



PATIENT

Speedy Sunshine
Willer

SPECIES

Canine

BREED

Chihuahua Mix

SEX

Spayed Female

AGE

10 years

WEIGHT

13.06 lbs

INTERPRETED BY

Andrea Nicastro,
DVM, Diplomate
ACVIM (*Small
Animal Internal
Medicine*)

**IMAGING
PERFORMED BY**

Jessica Miller

HOSPITAL NAME

Rockaway AH

REFERRING VET

Dr. Maniar

INVOICE

10733

DATE

4/13/22

PRESENTING CLINICAL SIGNS

History: Pancreatitis, IVDD, lethargy
Abnormal PE/Chem/CBC/UA Results: CPL abn.

ULTRASONOGRAPHIC EXAMINATION OF THE ABDOMEN

Urinary System

The urinary bladder, trigone, and pelvic urethra are normal in thickness and the mucosal surface is smooth. The bladder lumen is moderately distended with anechoic urine. No masses, inflammatory changes or calculi are observed. Ureteral papillae and visualized portion of the proximal urethra, visible to a depth of 2 cm, are normal.

The left kidney presented normal size (4.17 cm in length); normal shape and architecture with smooth peripheral margins. There is a normal 1:3 cortex to medulla ratio with minimal to mild loss of corticomedullary distinction. An ill-defined hyperechoic medullary band is observed adjacent to the corticomedullary junction. There is no evidence of pyelectasia, nephroliths, infarcts or hydroureter.

The right kidney presented normal size (4.25 cm in length); normal shape and architecture with smooth peripheral margins. There is a normal 1:3 cortex to medulla ratio with minimal to mild loss of corticomedullary distinction. There is no evidence of pyelectasia, nephroliths, infarcts or hydroureter.

Adrenal Glands

The left adrenal gland is normal size (0.48 cm at cranial pole) (0.45 cm at caudal pole) (2.13 cm in length); normal shape; homogenous parenchyma. The glandular echogenicity and detail are unremarkable. Capsule, cortex, and medullary definition are normal. The phrenicoabdominal vein and surrounding vasculature are normal.

The right adrenal gland is normal size (0.63 cm at cranial pole) (0.40 cm at caudal pole) (2.30 cm in length); normal shape; homogenous parenchyma. The glandular echogenicity and detail are unremarkable. Capsule, cortex, and medullary definition are normal. The phrenicoabdominal vein and surrounding vasculature are normal.

Spleen

The spleen is normal in size (1.46 cm in width at the level of the hilus) with a normal capsular contour. There is appropriate echogenicity and echotexture. No focal lesions are observed. Splenic vasculature is normal.

Liver

The liver is subjectively normal in size with normal contours and structure. There is appropriate echogenicity and echotexture. No overt structural evidence of inflammatory, infiltrative or regenerative pathology is evident. Vascular and biliary tracts are of normal volume with no evidence of congestion. No pathological hepatic lymphadenopathy observed.

The gall bladder lumen is moderately distended. The wall is thin and smooth. A small amount of aggregated, echogenic dependent to partially-dependent sludge is observed within the lumen. The cystic and common bile ducts are normal.

Gastrointestinal

The stomach and intestine are free of stasis and exhibit normal peristaltic activity. The gastric lumen is not distended. The gastric wall and pylorus are normal in thickness with a normal layering pattern. The small intestinal lumen is not dilated. The small intestinal wall thickness is normal with a normal layering pattern

and appropriate mural detail. Discreet masses are not identified. The colonic wall is normal. No obstructive or overt infiltrative disease is noted.

Pancreas

The left limb of the pancreas is visible with normal curvilinear peripheral contours. The parenchyma is largely isoechoic relative to surrounding omental fat and slightly mottled in appearance. The pancreatic duct is visible but not overtly dilated. There is no evidence of peripancreatic inflammation or effusion.

Free Abdomen

The peritoneal cavity is normal. There is no evidence of inflammation or effusion. One to two prominent mesenteric lymph nodes are visualized, the largest measuring 0.98 cm in length.

ULTRASONOGRAPHIC FINDINGS

Primary Findings

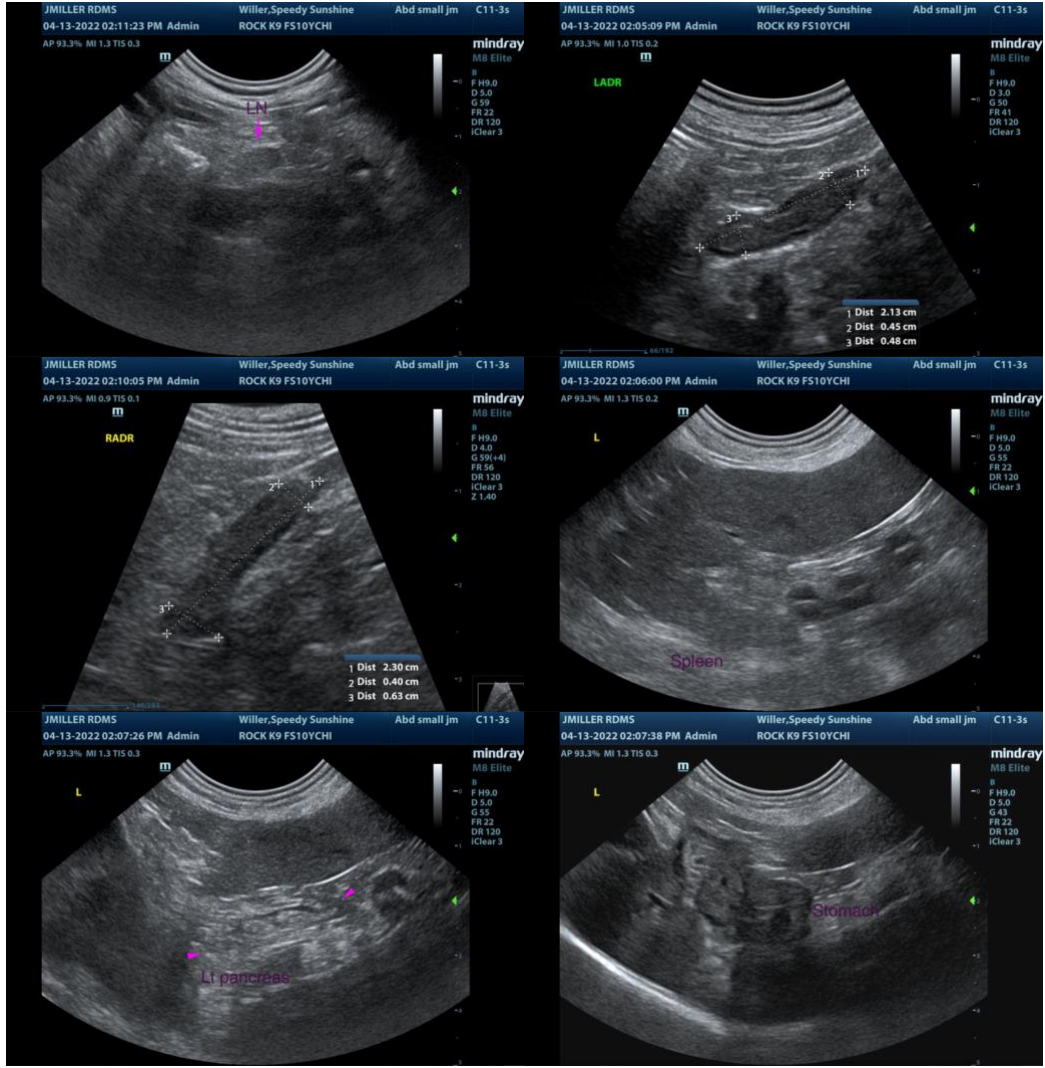
- Minor bilateral age-related renal changes
- Minor gall bladder sludge, non-mucocele.
- The pancreatic changes are most consistent with age-related parenchymal remodeling, potentially secondary to a prior inflammatory episode, early fibrosis or chronic pancreatitis.
- The lymph node changes are most consistent with reactive lymphadenitis or lymphoid hyperplasia.

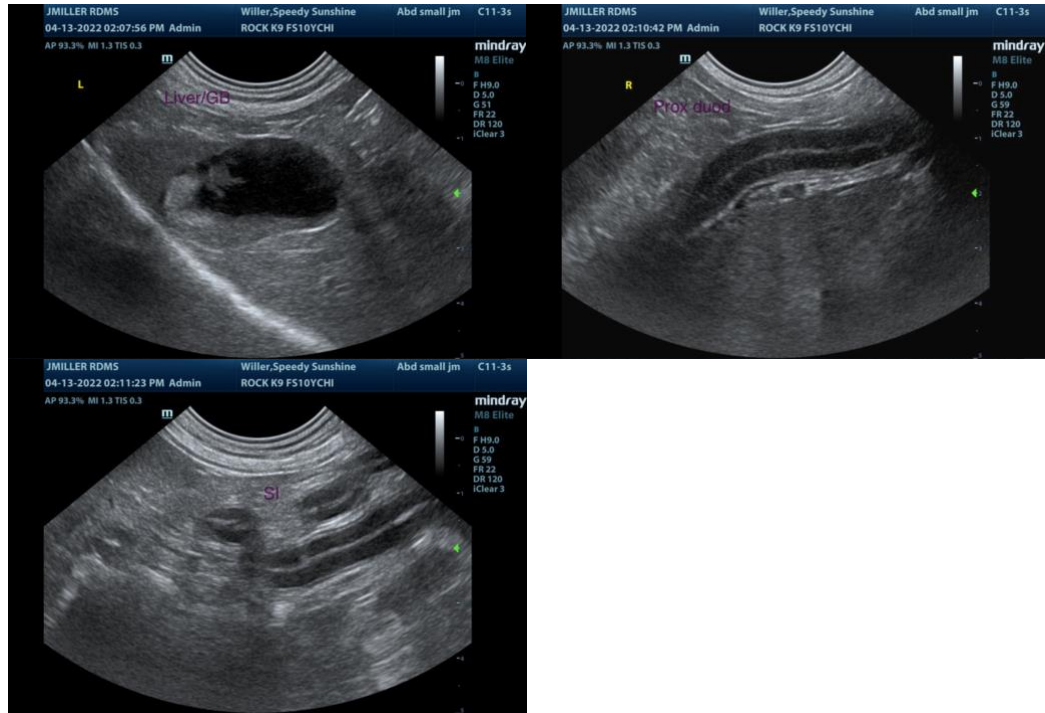
**An obvious cause for the patient's lethargy is not identified in this study. Considerations include underlying metabolic disease, orthopedic or neurologic disease, occult neoplasia, other.

INTERPRETATION OF THE FINDINGS & FURTHER RECOMMENDATIONS

Baseline lab-work including a CBC chemistry panel, urinalysis and T4 is recommended, if not already performed.

Also consider thoracic radiographs (three-view) to assess for occult disease in the chest, as well as thorough orthopedic and neurologic evaluations to assess for evidence of pain and deficits, respectively.





The information and recommendations provided are based on the images presented by the referring veterinarian/sonographer. No evaluation can be communicated regarding pathology that was not visible in the image/video clips provided.

Thank you for this referral. If the clinical or image interpretation does not parallel your findings or if I can be of any further assistance, please contact me.

Andrea Nicastro, DVM, Diplomate DACVIM (Small Animal Internal Medicine)
info@SonoPath.com