


PATIENT PRESENTING CLINICAL SIGNS

Ollie Veverka

History: Recheck ultrasound from 10/12/21. Patient continues to do well at home, no further concerns. Liver values were rechecked on 2/24/22 and showed that her ALP continues to elevate. Presented today for comprehensive oral health assessment and treatment and performed ultrasound prior to anesthesia.

SPECIES

Canine

Abnormal PE/Chem/CBC/UA Results: 3/9/2020 TP: 7.7 ALB: 2.8 Glob: 4.8 ALT: 21 ALP: 437 9/28/21 TP: 6.4 ALB: 3.5 Glob: 2.9 ALT: 51 ALP:

BREED

Beagle Mix

ULTRASONOGRAPHIC EXAMINATION OF THE ABDOMEN
Urinary System
SEX

Spayed Female

The urinary bladder, trigone, and pelvic urethra are normal in thickness and the mucosal surface is smooth. The bladder lumen is moderately distended with anechoic urine. No masses, inflammatory changes or calculi are observed. Ureteral papillae and visualized portion of the proximal urethra, visible to a depth of 2 cm, are normal.

AGE

13 years

The left kidney presented normal size (5.82 cm in length); normal shape and architecture with smooth peripheral margins. There is a normal 1:3 cortex to medulla ratio with mild to moderate loss of corticomedullary distinction. There is no evidence of pyelectasia, nephroliths, infarcts or hydronephrosis.

WEIGHT

39.4 lbs

The right kidney presented normal size (6.11 cm in length); normal shape and architecture with smooth peripheral margins. There is a normal 1:3 cortex to medulla ratio with mild loss of corticomedullary distinction. There is no evidence of pyelectasia, nephroliths, infarcts or hydronephrosis.

Adrenal Glands
INTERPRETED BY

Andrea Nicastro,
DVM, Diplomate
ACVIM (*Small Animal
Internal Medicine*)

The left adrenal gland is upper limits of normal size (0.68 cm at cranial pole) (0.70 cm at caudal pole); normal shape; homogenous parenchyma. The glandular echogenicity and detail are unremarkable. Capsule, cortex, and medullary definition are normal. The phrenicoabdominal vein and surrounding vasculature are normal.

The right adrenal gland is normal size (0.93 cm at cranial pole) (0.62 cm at caudal pole) (2.37 cm in length); normal shape; homogenous parenchyma. The glandular echogenicity and detail are unremarkable. Capsule, cortex, and medullary definition are normal. The phrenicoabdominal vein and surrounding vasculature are normal.

IMAGING PERFORMED BY

Dr. Goodman

Spleen

(Previously splenectomized)

HOSPITAL NAME

Evandale-Blue Ash PH

Liver

The liver is subjectively prominent in size with slightly swollen peripheral contours. The parenchyma is isoechoic relative to the spleen and subtly heterogenous in appearance. No distinct focal lesions are observed. Hepatic vasculature and intrahepatic biliary tracts are of normal volume with no evidence of congestion.

REFERRING VET

Dr. Goodman

The gall bladder lumen is moderately distended. The wall is thin and smooth. A small to moderate amount of echogenic debris is observed within the lumen, some of which is partially dependent and some of which is suspended. The cystic and common bile ducts are normal.

INVOICE

10737

Gastrointestinal

The stomach and intestine are free of stasis and exhibit normal peristaltic activity. The gastric lumen is not distended. The gastric wall and pylorus are normal in thickness with a normal layering pattern. The small

DATE

4/13/22

intestinal lumen is not dilated. The small intestinal wall thickness is normal with a normal layering pattern and appropriate mural detail. Discreet masses are not identified. The colonic wall is normal. No obstructive or overt infiltrative disease is noted.

Pancreas

The region of the pancreas is isoechoic relative to surrounding omental fat. No obvious parenchymal abnormalities are observed. There is no evidence of regional inflammation or effusion.

Free Abdomen

The peritoneal cavity is normal. There is no evidence of inflammation or effusion. The abdominal lymph nodes are normal/not visible.

ULTRASONOGRAPHIC FINDINGS

Primary Findings

- Suspected benign diffuse hepatopathy. Vacuolar hepatopathy and regenerative nodular hyperplasia are the top differentials. Changes are similar to the previous sonogram.
- Gall bladder debris, non-mucocele

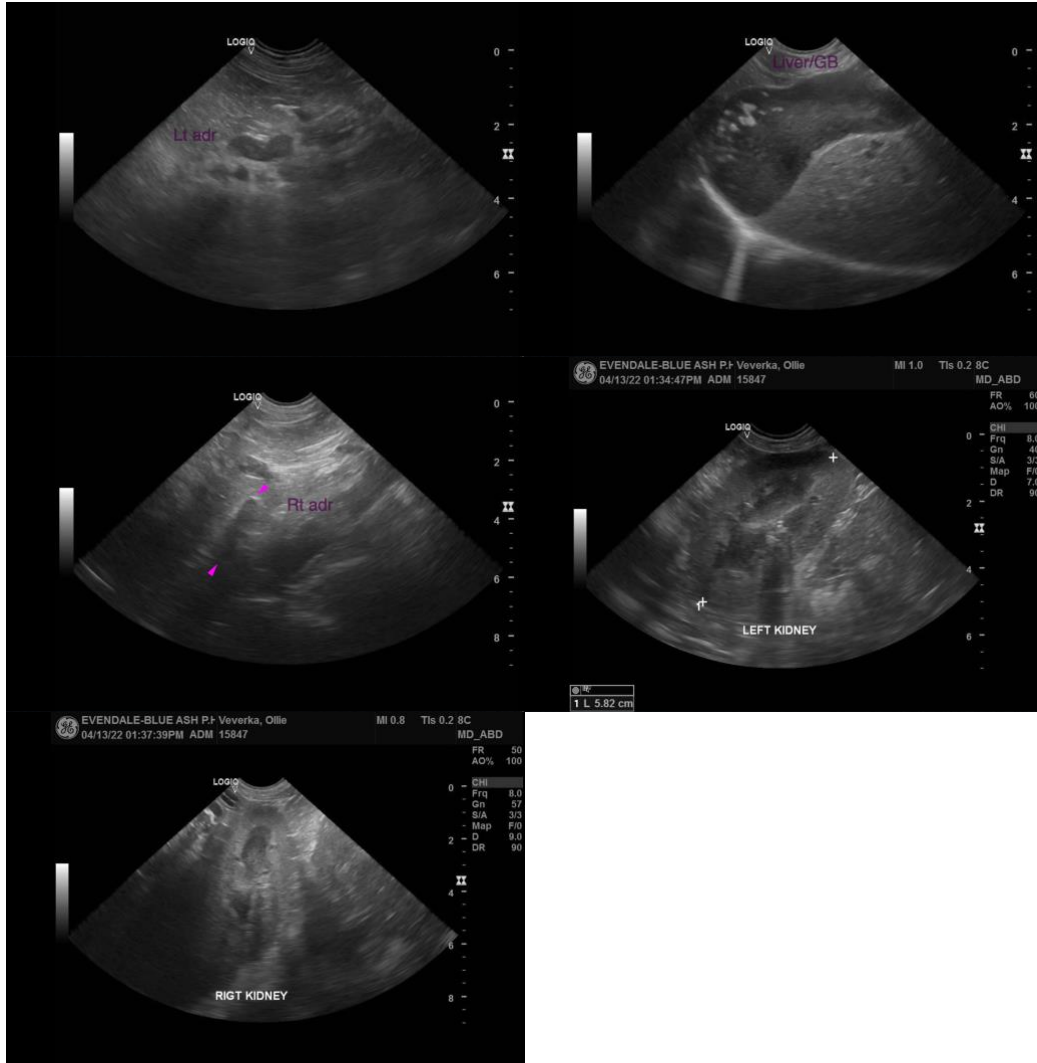
Secondary Findings

- Mild, chronic, nonspecific, age-related renal changes

INTERPRETATION OF THE FINDINGS & FURTHER RECOMMENDATIONS

Continued monitoring (i.e., every 3-4 months) of the patient's liver values is recommended, with repeat sonography if values continue to increase.

With regard to anesthesia, it would be prudent to avoid benzodiazepines. Also, opioids should be used judiciously due to their hepatic metabolism.



The information and recommendations provided are based on the images presented by the referring veterinarian/sonographer. No evaluation can be communicated regarding pathology that was not visible in the image/video clips provided.

Thank you for this referral. If the clinical or image interpretation does not parallel your findings or if I can be of any further assistance, please contact me.

Andrea Nicastro, DVM, Diplomate DACVIM (Small Animal Internal Medicine)
 info@SonoPath.com