



PATIENT

Charlotte
Tamburino

SPECIES

Canine

PRESENTING CLINICAL SIGNS

History: Weight loss, intermittent GI signs, history of Addisons. Current meds: Zycortal pred.
Abnormal PE/Chem/CBC/UA Results: Creat. 1.9, ALT 141, lymphs .92.

ULTRASONOGRAPHIC EXAMINATION OF THE ABDOMEN

BREED

WH Terrier

Urinary System

The bladder is mildly distended. The wall in the region of the apex is thickened (up to 0.70 cm) and irregular. The wall tapers to a normal thickness as it extends to the urinary bladder neck. A scant amount of echogenic debris is observed within the lumen. No cystic calculi are observed. The region of the trigone is normal.

SEX

Spayed Female

The left kidney presented normal size (4.34 cm in length); normal shape and architecture with smooth peripheral margins. There is a normal 1:3 cortex to medulla ratio with mild loss of corticomedullary distinction. A 0.34 cm cortical cyst is observed at the medial aspect. Mild to moderate pyelectasia is present (0.40 cm in the longitudinal plane). There is no evidence of nephroliths, infarcts or hydroureter. Renal vasculature is normal.

AGE

17 years

The right kidney presented normal size (3.34 cm in length); normal shape and architecture with smooth peripheral margins. There is a normal 1:3 cortex to medulla ratio with mild loss of corticomedullary distinction. There is no evidence of pyelectasia, nephroliths, infarcts or hydroureter. Renal vasculature is normal.

WEIGHT

11.2 lbs

Adrenal Glands

The left adrenal gland is normal size (0.47 cm at cranial pole) (0.54 cm at caudal pole) (1.38 cm in length); normal shape; homogenous parenchyma. The glandular echogenicity and detail are unremarkable. Capsule, cortex, and medullary definition are normal. The phrenicoabdominal vein and surrounding vasculature are normal.

The right adrenal gland is small in size (0.51 cm at cranial pole) (0.28 cm at caudal pole) (1.12 cm in length); normal shape; homogenous parenchyma. The glandular echogenicity and detail are unremarkable. Capsule, cortex, and medullary definition are normal. The phrenicoabdominal vein and surrounding vasculature are normal.

INTERPRETED BY

Andrea Nicastro,
DVM, Diplomate
ACVIM (Small Animal
Internal Medicine)

IMAGING PERFORMED BY

Kelly Vazquez

HOSPITAL NAME

Animal General on
Hudson

REFERRING VET

Dr. William Freedman

Spleen

The spleen is normal in size (0.72 cm in width at the level of the hilus) with a normal capsular contour. There is appropriate echogenicity and echotexture. A 0.54 cm irregular, hyperechoic nodule is observed at the medial aspect. The nodule causes slight capsular expansion. Splenic vasculature is normal.

Liver

The liver is subjectively normal in size with normal curvilinear peripheral contours. The parenchyma is hypoechoic relative to the spleen with minor changes consistent with age-related remodeling. No focal lesions are observed. Hepatic vasculature and biliary tracts are of normal volume with no evidence of congestion.

INVOICE

10735

DATE

4/13/22

The gall bladder lumen is moderately distended. The wall is thin and smooth. Luminal contents are anechoic. The cystic and common bile ducts are normal.

Gastrointestinal

The gastric lumen is not distended. The gastric wall in the region of the fundus is normal in thickness with a normal layering pattern. Near the region of the pyloric antrum, the wall is thickened (up to 0.84 cm) with a

prominent muscularis layer and retention of the normal layering pattern. The pyloric outflow tract is patent. The small intestinal lumen is segmentally dilated with chyme. The small intestinal wall thickness is normal with a normal layering pattern and appropriate mural detail. Discreet masses are not identified. The colonic wall is normal. No obstructive or overt infiltrative disease is noted.

Pancreas

The right limb of the pancreas is visible with normal curvilinear peripheral contours. The parenchyma is largely isoechoic relative to surrounding omental fat and slightly mottled in appearance. The pancreatic duct is visible but not overtly dilated. There is no evidence of peripancreatic inflammation or effusion.

Free Abdomen

Trace free fluid is observed. The abdominal lymph nodes are normal/not visible.

Other

A uterine stump is visible and is normal in size (0.54 cm in width). No obvious pathology is observed.

ULTRASONOGRAPHIC FINDINGS

Primary Findings

- The urinary bladder wall changes could be consistent with cystitis or infiltrative neoplasia (i.e., transitional cell carcinoma). Some of the bladder wall thickening may be artifactual due to lack of full repletion. The previously observed finger-like projections are no longer visible. However, the wall is slightly thicker compared to the previous scan.
- The gastric wall thickening in the pyloric antrum could be consistent with inflammatory, hypertrophy or emerging neoplasia.
- Trace ascites

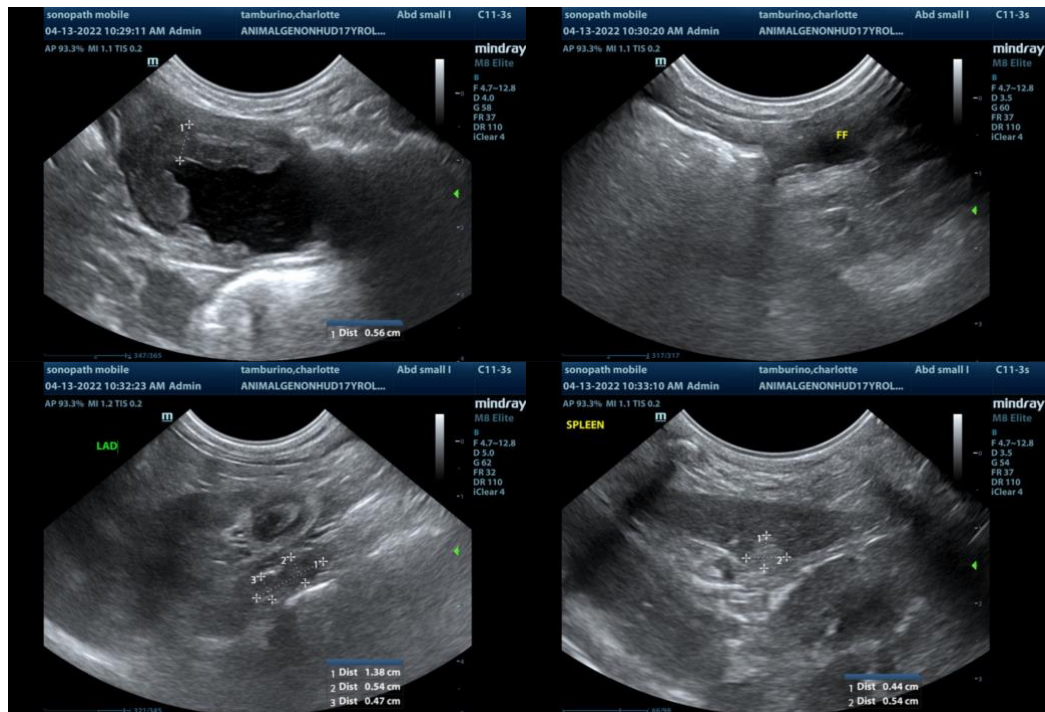
Secondary Findings

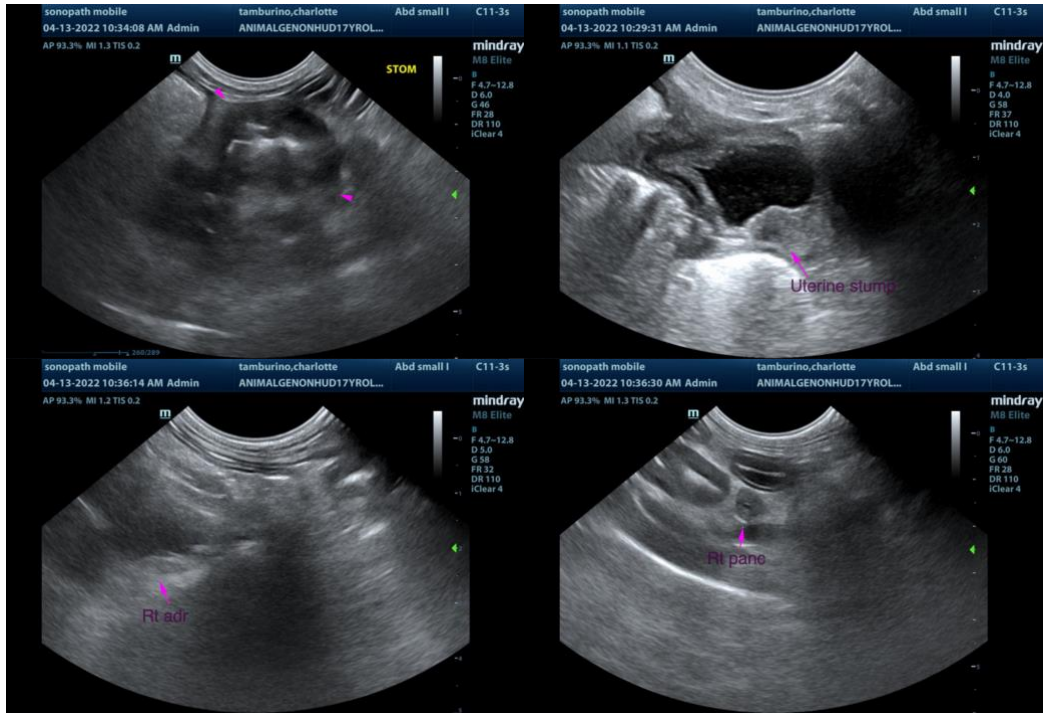
- The hepatic changes are consistent with age-related parenchymal remodeling and are not considered clinically significant at this time.
- The splenic nodule trends toward the benign (i.e., myelolipoma) with a lower possibility of emerging neoplasia.
- The small right adrenal gland is consistent with a previous diagnosis of hypoadrenocorticism.
- Bilateral age-related renal changes with right pyelectasia. Changes are similar to the previous sonogram.
- The pancreatic changes are most consistent with age-related parenchymal remodeling, potentially secondary to a prior inflammatory episode, early fibrosis or chronic pancreatitis.
- Visible uterine stump – incidental.

**An obvious cause for the patient's clinical signs is not definitively identified in this study.

INTERPRETATION OF THE FINDINGS & FURTHER RECOMMENDATIONS

- Fecal evaluation for ova and Giardia
- Malabsorption panel, including serum cobalamin and folate, TLI and PLI
- Thoracic radiographs to assess for occult neoplasia
- +/- pre-and postprandial serum bile acids to assess hepatic function.
- Consider transitioning to a limited antigen diet.
- Ultimately, endoscopic or surgical gastrointestinal biopsies may be necessary to get a definitive diagnosis.





The information and recommendations provided are based on the images presented by the referring veterinarian/sonographer. No evaluation can be communicated regarding pathology that was not visible in the image/video clips provided.

Thank you for this referral. If the clinical or image interpretation does not parallel your findings or if I can be of any further assistance, please contact me.

Andrea Nicastro, DVM, Diplomate DACVIM (Small Animal Internal Medicine)
info@SonoPath.com