

**DATE PRESENTING CLINICAL SIGNS**

4/13/2022

Presented on 31st of March 2022 for hyporexia. Had been seen 14 days prior for wellness examination with no significant findings/concerns; no vaccinations or procedures performed at the wellness examination. No changes in diet; no vomiting, diarrhea, coughing, or sneezing. Indoor only cat. Weight in September 2021: 11.7 lbs; March 2022: 10.7 lbs; April 2022 9.1 lbs. Examination: Oral Cavity: multiple missing incisors, periodontal disease grade 1; no history of dentistry workup/extractions BCS 5/9, No palpable regions of pain.

PATIENT

Buddy Richardson

SPECIES

Feline

BREED

DSH

SEX

Neutered Male

AGE

9.1lbs

WEIGHT

1/12/2009

INTERPRETED BY

Andrea Nicastro, DMV,
Diplomate DACVIM
(Small Animal
Internal Medicine)

HOSPITAL NAME

Airpark Animal
Hospital

REFERRING VET

Dr. Marciszewski

INVOICE

10726

Current Medications: April 2, 2022: -Subcutaneous fluids (150 mLs) -1 mL Vitamin B injection (SQ), -Cerenia injection (0.45 mg/lb SQ)
-Entyce (0.9 PO SID as needed q24 hours).
Lab Results: CBC: mild monocytosis. Chemistry: ALT, ALP below normal reference ranges, hypocholesterolemia, proBNP: WNL, TT4, FT4: WNL
Date of Previous IntraPet Ultrasound: No previous.
Sedation: Patient sedated with Dexdomitor.
Stat Report: Not requested.

Imaging Performed By: Andi Parkinson, RDMS.

ULTRASONOGRAPHIC EXAMINATION OF THE ABDOMEN**Urinary System**

The urinary bladder is mildly distended. The wall is normal in thickness with a smooth mucosal surface. A small amount of aggregated, echogenic, suspended debris is observed within the lumen. No cystic calculi are observed. The region of the trigone is normal.

The left kidney is normal in size (3.87 cm in length); with a slightly irregular shape. There is a normal 1:3 cortex to medulla ratio with mild to moderate loss of corticomedullary distinction. There is no evidence of nephroliths. A 0.47 cm cortical cyst is seen. Moderate to severe hydronephrosis is present (0.96 cm in the longitudinal plane). The proximal ureter is dilated (up to 0.41 cm in diameter). The ureter is no longer visible approximately 1.31 in the transverse plane.

The right kidney is normal in size (4.36 cm in length) with a normal shape, smooth peripheral margins, and normal internal architecture. There is mild to moderate loss of corticomedullary distinction. Several hyperechoic shadowing diverticular foci are observed. Trace pyelectasia is present. There is no evidence of infarcts or hydroureter.

Adrenal Glands

The left adrenal gland is normal size (0.45 cm width). Normal shape and glandular echogenicity. The phrenicoabdominal vein and surrounding vasculature are normal.

The region of the right adrenal gland is evaluated. No obvious pathology is observed.

Spleen

The spleen is normal in size (0,76 cm in width at the level of the hilus) with a normal capsular contour. There is appropriate echogenicity and echotexture. No focal lesions are observed. Splenic vasculature is normal.

Liver

The liver is subjectively normal in size with normal contours and structure. There is appropriate echogenicity and echotexture. No overt structural evidence of inflammatory, infiltrative, or regenerative pathology is evident. Vascular and biliary tracts are of normal volume with no evidence of congestion. No pathological hepatic lymphadenopathy observed.

The gall bladder lumen is mildly distended. The wall is normal in thickness. A small amount of aggregated, echogenic, gravity dependent debris is observed within the lumen. The cystic and common bile ducts are normal.

Gastrointestinal

The stomach and intestine are free of stasis and exhibit normal peristaltic activity. The gastric lumen is not distended. The gastric wall and pylorus are normal in thickness with a normal layering pattern. The pyloric outflow tract is patent. The small intestinal lumen is not dilated. The small intestinal wall thickness is normal with a normal layering pattern and appropriate mural detail. There is disruption in the normal 1:3 muscularis: mucosal ratio in most segments. Discreet masses are not identified. The colonic wall is normal. There is no evidence of an obstructive pattern.

Pancreas

The region of the pancreas is isoechoic relative to surrounding omental fat. No obvious parenchymal abnormalities are observed. There is no evidence of regional inflammation or effusion.

Free Abdomen

There is no obvious evidence of free fluid. The abdominal lymph nodes are normal/not visible.

Other

A brief echocardiogram reveals no evidence of pericardial effusion or obvious right atrial/auricular mass. A few nodules are observed within the thorax, the largest measuring 1.41 cm in diameter. Ring-down artifact is associated with the nodules.

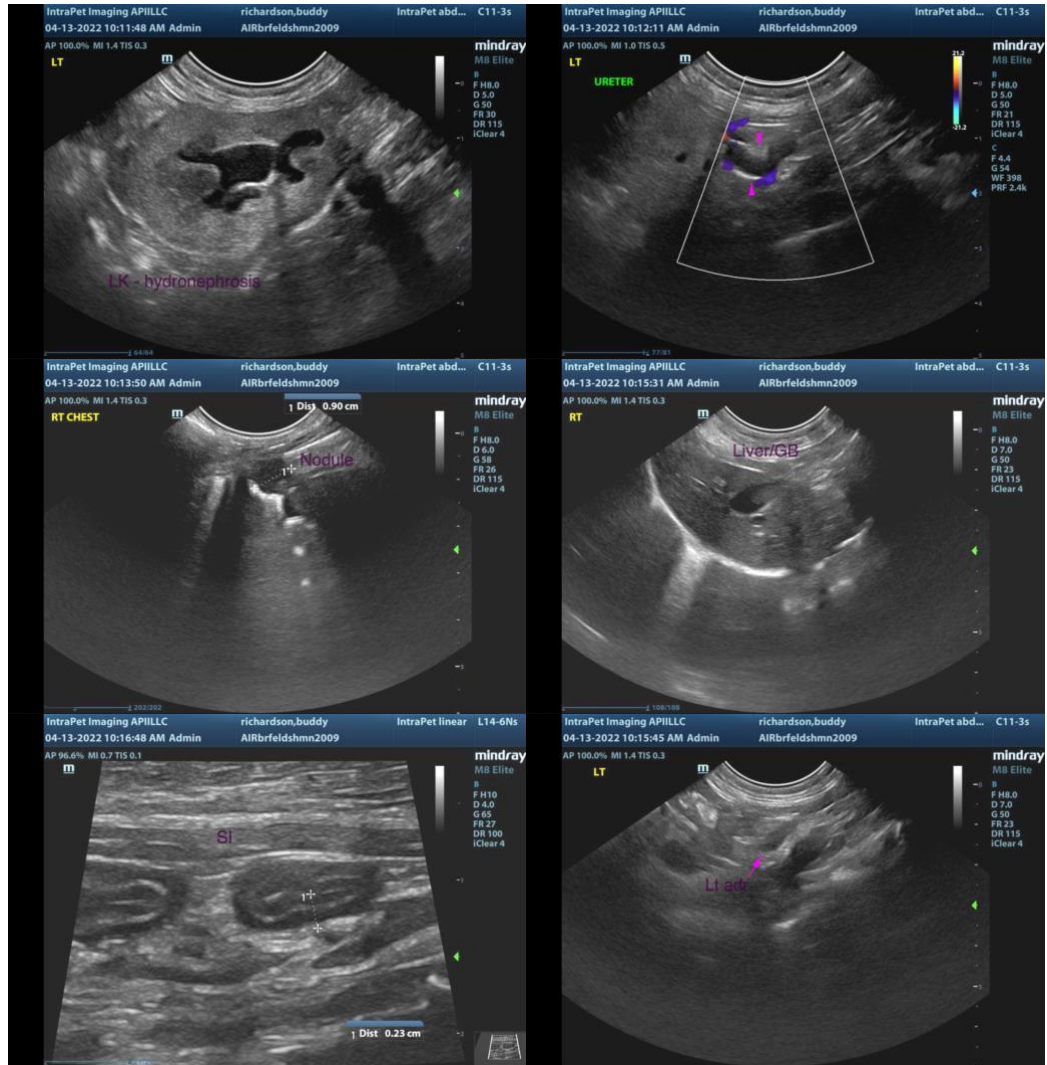
ULTRASONOGRAPHIC FINDINGS

Primary Findings

- The small intestinal wall changes are consistent with inflammatory bowel disease with potential for emerging lymphoma. However, neoplasia is considered less likely at this time.
- The pulmonary nodules could be consistent with neoplasia, granulomas, foci of inflammation, other.
- Bilateral age-related renal changes. The left hydronephrosis/proximal hydroureter, may be secondary to a left ureteral stricture, a small ureterolith, or less likely, a ureteral tumor.

INTERPRETATION OF THE FINDINGS & FURTHER RECOMMENDATIONS

- Regarding the bowel changes and patient's clinical signs, consider a malabsorption panel (i.e., serum cobalamin and folate, TLI and PLI), fecal evaluation for ova and Giardia, and gastrointestinal biopsies (i.e., endoscopic or surgical), depending on the results of the thoracic radiographs.
- Regarding the renal changes, urinalysis and culture and sensitivity are recommended.



The information and recommendations provided are based on the images presented by the referring veterinarian/sonographer. No evaluation can be communicated regarding pathology that was not visible in the image/video clips provided.

Thank you for this referral. If the clinical or image interpretation does not parallel your findings or if I can be of any further assistance, please contact me.

Andrea Nicastro, DVM, Diplomate DACVIM (Small Animal Internal Medicine)
info@SonoPath.com