**PATIENT**

Ballard Turcotte

SPECIES

Canine

BREED

Labrador Retriever

SEX

Female, spayed

AGE

13 Yrs.

WEIGHT

47 Pounds

INTERPRETED BY

Andrea Nicastro,
DVM, Diplomate
ACVIM (*Small
Animal Internal
Medicine*)

IMAGING PERFORMED BY

PMVU

HOSPITAL NAME

Silver Spring AH

REFERRING VET

Dr. Cathy Jarrett

INVOICE

13191

DATE

4/12/22

PRESENTING CLINICAL SIGNS

History: Abnormal lab work and hypertension. Currently on amlodipine.

Abnormal PE/Chem/CBC/UA Results: (03/11/2022) Urine Culture: No growth. U/A: USG 1.035, pH 7.0, Creatinine 107, Protein >400, Ketones 15. (03/07/2022) CBC: Reticulocyte Hemoglobin 23.3. CHEM: SDMA 18, Amylase 1710, Lipase 414. T4: WNL.

ULTRASONOGRAPHIC EXAMINATION OF THE ABDOMEN*Urinary System*

The urinary bladder, trigone, and pelvic urethra are normal in thickness and the mucosal surface is smooth. The bladder lumen is moderately distended with anechoic urine. No masses, inflammatory changes or calculi are observed. Ureteral papillae and visualized portion of the proximal urethra, visible to a depth of 2 cm, are normal.

The left kidney is normal size (6.21 cm in length); normal shape and architecture with smooth peripheral margins. The cortex is mildly thickened and hyperechoic and there is mild loss of corticomedullary distinction. Hyperechoic shadowing diverticular foci are visualized. Trace pyelectasia is present. There is no evidence of infarcts or hydroureter. Renal vasculature is normal.

The right kidney is normal size (6.25 cm in length); normal shape and architecture with smooth peripheral margins. There is a normal 1:3 cortex to medulla ratio with normal corticomedullary distinction. There is no evidence of pyelectasia, nephroliths, infarcts or hydroureter. Renal vasculature is normal.

Adrenal Glands

The cranial pole of the left adrenal gland is prominent (1.15 cm at cranial pole) and the caudal pole is normal in size (0.66 cm at caudal pole) (3.20 cm in length). The gland overall has a slightly irregular shape. A 1.10 x 0.77 cm hyperechoic nodule is observed at the cranial aspect. The glandular echogenicity and detail at the caudal aspect are unremarkable. The phrenicoabdominal vein and surrounding vasculature are normal.

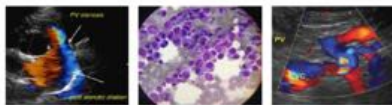
The right adrenal gland is prominent at the cranial to mid aspect and normal in size at the caudal aspect (1.04 cm at cranial pole) (0.59 cm at caudal pole) (2.67 cm in length). A 2.11 x 1.01 cm irregular lobulated hyperechoic to heterogeneous nodule/mass is observed in the cranial to mid gland. The glandular echogenicity and detail at the caudal pole are normal. There was no obvious evidence of invasion into the caudal vena cava.

Spleen

The spleen is normal in size (1.43 cm in width at the level of the hilus) with a normal capsular contour. There is appropriate echogenicity and echotexture. No focal lesions are observed. Splenic vasculature is normal.

Liver

The liver is subjectively prominent in size with swollen curvilinear peripheral contours. The parenchyma is isoechoic relative to the spleen and exhibits mild heterogeneity. No distinct focal lesions are observed. Hepatic vasculature and biliary tracts are of normal volume with no evidence of congestion. The portal vein: caudal vena cava ratio is approximately 1:1. The gall bladder lumen is moderately distended. The wall is thin and smooth. A moderate amount of aggregated echogenic to mineralized

**PATIENT**

Ballard Turcotte

sludge is observed within the lumen, most of which is gravity-dependent and some of which is adhered to the luminal surface or suspended. The cystic and common bile ducts are normal/not seen.

Gastrointestinal**SPECIES**

Canine

The stomach and intestine are free of stasis and exhibit normal peristaltic activity. The gastric lumen is not distended. The gastric wall and pylorus are normal in thickness with a normal layering pattern. The pyloric outflow tract is patent. The small intestinal lumen is not dilated. The small intestinal wall thickness is normal with a normal layering pattern and appropriate mural detail. Discreet masses are not identified. The colonic wall is normal. No obstructive disease is noted.

BREED

Labrador Retriever

Pancreas

The pancreas is normal in size with normal peripheral contours. The pancreatic duct is normal. The base and limbs of the pancreas are isoechoic to surrounding omental fat. No focal lesions are observed. There is no evidence of peripancreatic inflammation or effusion.

SEX

Female, spayed

Free Abdomen**AGE**

13 Yrs.

The peritoneal cavity is normal. There is no evidence of inflammation or effusion. A few prominent jejunal lymph nodes are visualized, the largest measuring 1.20 cm in length. The nodes are normal in shape and echogenicity.

WEIGHT

47 Pounds

ULTRASONOGRAPHIC FINDINGS**Primary Findings:**

- Bilateral adrenal nodules. These lesions may represent bilateral tumors, benign nodular hyperplasia or a unilateral tumor (right gland) with nodular hyperplasia in the contralateral (left gland).

Secondary Findings:

- The diffuse hepatic changes are non-specific and could be consistent with vacuolar hepatopathy, regenerative nodular hyperplasia, and/or age-related remodeling. Inflammatory and infiltrative disease are considered less likely.
- The gastric wall changes in the pyloric antrum could be consistent with an inflammation or hypertrophy or less likely, emerging neoplasia. Correlation with clinical findings is recommended.
- The lymph node changes are most consistent with reactive lymphadenitis or lymphoid hyperplasia.
- The bilateral renal changes are consistent with chronic interstitial nephrosis with dystrophic mineralization.
- Gallbladder sludge, non-mucocele.

INTERPRETED BY

Andrea Nicastro,
DVM, Diplomate
ACVIM (*Small
Animal Internal
Medicine*)

IMAGING PERFORMED BY

PMVU

HOSPITAL NAME

Silver Spring AH

REFERRING VET

Dr. Cathy Jarrett

INVOICE

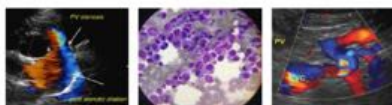
13191

DATE

4/12/22

INTERPRETATION OF THE FINDINGS & FURTHER RECOMMENDATIONS

- To further assess for functional adrenal tumors, consider a low-dose dexamethasone suppression test and urine/blood catecholamine levels (Marshfield Lab).
- Three-view thoracic radiographs are also recommended to assess for pulmonary metastatic disease.



PATIENT

Ballard Turcotte

- Given the hypertension, also consider a UPC (if proteinuria is present) +/- an echocardiogram to assess for underlying cardiac disease.

SPECIES

Canine

BREED

Labrador Retriever

SEX

Female, spayed

AGE

13 Yrs.

WEIGHT

47 Pounds

INTERPRETED BY

Andrea Nicastro,
DVM, Diplomate
ACVIM (*Small
Animal Internal
Medicine*)

**IMAGING
PERFORMED BY**

PMVU

HOSPITAL NAME

Silver Spring AH

REFERRING VET

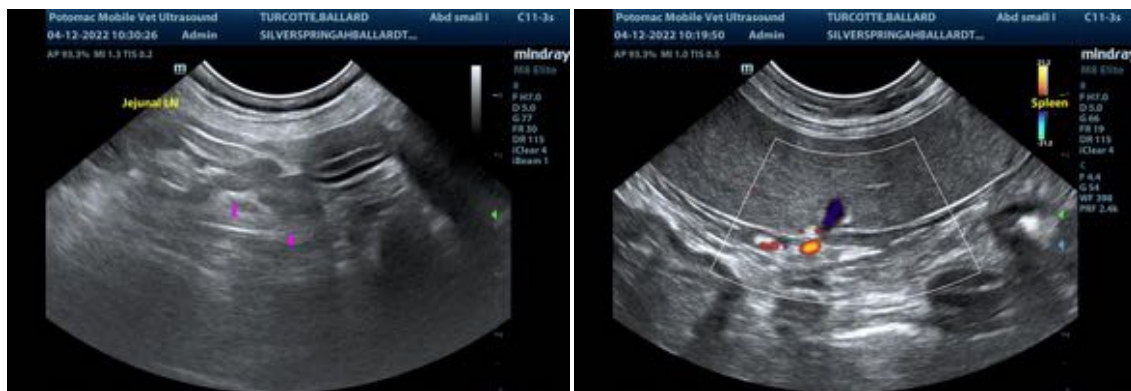
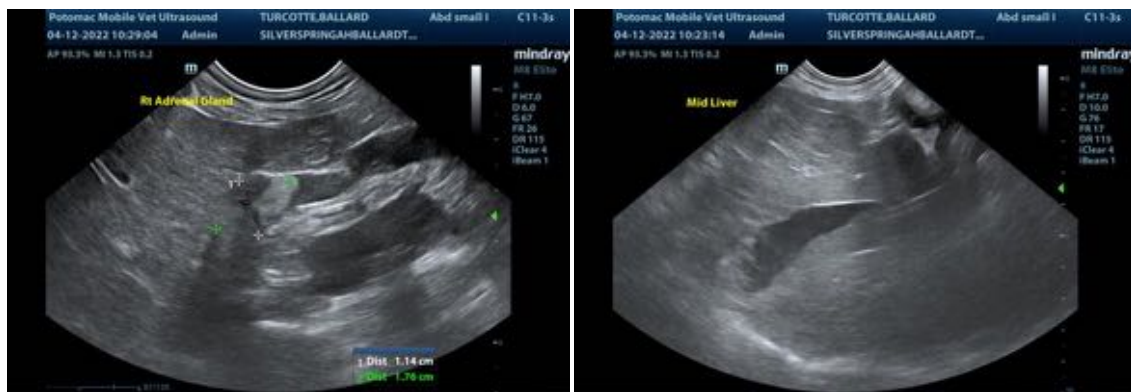
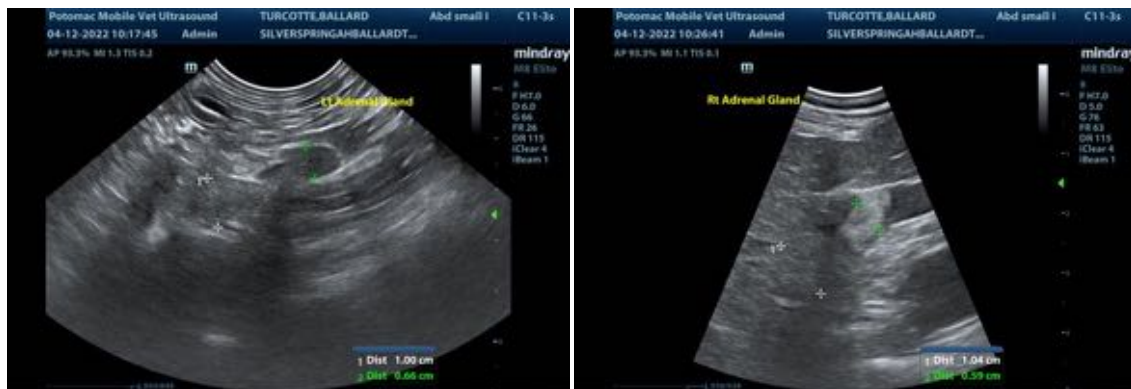
Dr. Cathy Jarrett

INVOICE

13191

DATE

4/12/22



The information and recommendations provided are based on the images presented by the referring veterinarian. No evaluation can be communicated regarding pathology that was not visible in the image/video clips provided.

Thank you for this referral. If the clinical or image interpretation does not parallel your findings or if I can be of any further assistance please contact me.

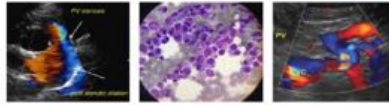
Andrea Nicastro, DVM, Diplomate ACVIM (*Small Animal Internal Medicine*)

IMAGING PERFORMED BY

www.potomacmvu.com 571-207-7467



Potomac Mobile Veterinary Ultrasound



 **SonoPath**
Clinical Sonography & Telectology

EDUCATIONAL TELECONSULTATION SERVICES™

1-800-838-4268 info@sonopath.com SonoPath.com

PATIENT

Andrea.nicastro@sonopath.com

Ballard Turcotte

SPECIES

Canine

BREED

Labrador Retriever

SEX

Female, spayed

AGE

13 Yrs.

WEIGHT

47 Pounds

INTERPRETED BY

Andrea Nicastro,
DVM, Diplomate
ACVIM (*Small
Animal Internal
Medicine*)

**IMAGING
PERFORMED BY**

PMVU

HOSPITAL NAME

Silver Spring AH

REFERRING VET

Dr. Cathy Jarrett

INVOICE

13191

DATE

4/12/22