SonoPath
Clinical Sonography & Telecytology
EDUCATIONAL TELECONSULTATION SERVICES™
1-800-838-4268 info@sonopath.com SonoPath.com

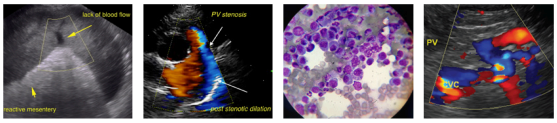

Charleston Mobile Veterinary Services
IMAGING PERFORMED BY
CharlestonMobile.Net 800.403.5408

PATIENT
Lena Ver Hey

SPECIES
Canine

BREED
Goldendoodle

SEX
Intact Female

AGE
10/10/21

WEIGHT
52 lbs

INTERPRETED BY
Andrea Nicastro, DVM, Diplomate ACVIM (*Small Animal Internal Medicine*)

IMAGING PERFORMED BY
Andrea Nicastro, DVM, Diplomate ACVIM (*Small Animal Internal Medicine*)

HOSPITAL NAME
Clements Ferry Vet

REFERRING VET
Dr. Kaitlyn Thomas

INVOICE
36777

DATE
4/11/22

PRESENTING CLINICAL SIGNS

Acute onset of vomiting and icterus. ALP 1000, ALT off the scale, TBili 20. No known dietary indiscretion.

Current Meds: Fluids in hosp, Simparica Trio on 3/30/22

ULTRASONOGRAPHIC EXAMINATION OF THE ABDOMEN

Urinary System

The urinary bladder, trigone, and pelvic urethra are normal in thickness and the mucosal surface is smooth. The bladder lumen is moderately distended with anechoic urine. No masses, inflammatory changes or calculi are observed. Ureteral papillae and visualized portion of the proximal urethra, visible to a depth of 1 cm, are normal.

The left kidney presented slightly swollen in size (8.07 cm in length); normal shape and architecture with smooth peripheral margins. There is a normal 1:3 cortex to medulla ratio with normal corticomedullary distinction. There is no evidence of pyelectasia, nephroliths, infarcts or hydroureter. The renal artery is subjectively prominent/dilated.

The right kidney presented normal size (5.87 cm in length); normal shape and architecture with smooth peripheral margins. There is a normal 1:3 cortex to medulla ratio with normal corticomedullary distinction. There is no evidence of pyelectasia, nephroliths, infarcts or hydroureter. Renal vasculature is normal.

Adrenal Glands

The left adrenal gland is normal size (0.38 cm at cranial pole) (0.47 cm at caudal pole) (3.33 cm in length); normal shape; homogenous parenchyma. The glandular echogenicity and detail are unremarkable. Capsule, cortex, and medullary definition are normal. The phrenicoabdominal vein and surrounding vasculature are normal.

The right adrenal gland is normal size (0.69 cm at cranial pole) (0.65 cm at caudal pole) (2.89 cm in length); normal shape; homogenous parenchyma. The glandular echogenicity and detail are unremarkable. Capsule, cortex, and medullary definition are normal. The phrenicoabdominal vein and surrounding vasculature are normal.

Spleen

The spleen is normal in size (2.48 cm) with a normal capsular contour. There is appropriate echogenicity and echotexture. No focal lesions are observed. Splenic vasculature is normal.

Liver

The liver is subjectively small in size with normal curvilinear peripheral contours. The parenchyma is hypoechoic relative to the spleen and subtly mottled in appearance. No distinct focal lesions are observed. Hepatic vasculature and intrahepatic biliary tracts are of normal volume with no evidence of congestion. The portal vein/caudal vena cava ratio is approximately 1:1.

The gall bladder lumen is moderately distended. The wall is normal to slightly thickened (up to 0.22 cm). Luminal contents are mostly anechoic. The cystic and common bile ducts are normal/not seen.

SonoPath
Clinical Sonography & Telecytology
EDUCATIONAL TELECONSULTATION SERVICES™
1-800-838-4268 info@sonopath.com SonoPath.com

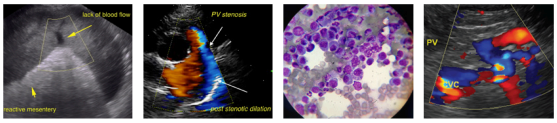

Charleston Mobile Veterinary Services
IMAGING PERFORMED BY
CharlestonMobile.Net 800.403.5408

PATIENT
Lena Ver Hey

SPECIES
Canine

BREED
Goldendoodle

SEX
Intact Female

AGE
10/10/21

WEIGHT
52 lbs

INTERPRETED BY
Andrea Nicastro, DVM, Diplomate ACVIM (*Small Animal Internal Medicine*)

IMAGING PERFORMED BY
Andrea Nicastro, DVM, Diplomate ACVIM (*Small Animal Internal Medicine*)

HOSPITAL NAME
Clements Ferry Vet

REFERRING VET
Dr. Kaitlyn Thomas

INVOICE
36777

DATE
4/11/22

Gastrointestinal

The stomach and intestine are free of stasis and exhibit normal peristaltic activity. The gastric lumen is not distended. The gastric wall and pylorus are normal in thickness with a normal layering pattern. The small intestinal lumen is segmentally fluid distended (mild). The small intestinal wall thickness is normal (xxx cm) with a normal layering pattern and appropriate mural detail. Discreet masses are not identified. The colonic wall is normal. No obstructive or overt infiltrative disease is noted.

Pancreas

The right limb of the pancreas is visible/prominent with minimal deviation from the normal peripheral contours. The parenchyma is slightly hypoechoic relative to surrounding omental fat and mildly edematous. No distinct focal lesions are observed. The pancreatic duct is not overtly dilated.

Free Abdomen

A small amount of anechoic free fluid is visualized.

A few prominent mesenteric lymph nodes are visualized, the largest measuring 3.17 cm in length. The nodes are normal in shape and echogenicity.

Other

A brief echocardiogram reveals no evidence of pericardial effusion or obvious right atrial/auricular mass.

PRIMARY FINDINGS

- Suspect primary hepatopathy. Top differentials include inflammatory hepatopathy (i.e., bacterial cholangiohepatitis, chronic fibrosing hepatitis), Leptospirosis, hepatotoxicosis (i.e., sago palm, copper-associated hepatoopathy). A congenital extrahepatic portosystemic shunt is considered unlikely based on the normal portal vein to caudal vena cava ratio and normal portal vein branching. However, a congenital intrahepatic vascular anomaly cannot be completely excluded.

- Trace ascites – likely secondary to hepatic disease (i.e., due to portal hypertension or low oncotic pressure, if applicable).

SECONDARY FINDINGS

- The abdominal lymphadenopathy may be secondary to immunologic immaturity and/or reactive change.

- The pancreatic changes may be secondary to portal hypertension or mild pancreatitis.
- The significance of the prominent left renal artery is unclear but could suggest increased hydrostatic pressure (i.e., due to early portal hypertension).

INTERPRETATION OF THE FINDINGS & FURTHER RECOMMENDATIONS

- Leptospirosis testing (i.e., blood in urine PCR serology)

- Assessment of coagulation status (PT/PTT)

- Consider empirical treatment for bacterial cholangiohepatitis/Leptospirosis (i.e., amoxicillin, clavulanic acid +/- metronidazole, Denamarin) as well as supportive care.

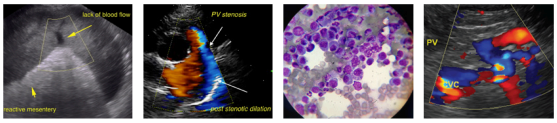

PATIENT

Lena Ver Hey

SPECIES

Canine

BREED

Goldendoodle

SEX

Intact Female

AGE

10/10/21

WEIGHT

52 lbs

INTERPRETED BY

Andrea Nicastro, DVM, Diplomate ACVIM (*Small Animal Internal Medicine*)

IMAGING PERFORMED BY

Andrea Nicastro, DVM, Diplomate ACVIM (*Small Animal Internal Medicine*)

HOSPITAL NAME

Clements Ferry Vet

REFERRING VET

Dr. Kaitlyn Thomas

INVOICE

36777

DATE

4/11/22

- If the liver values do not improve within 3-5 days of initiation of therapy and Leptospirosis testing is negative, consider a surgical liver biopsy with aerobic and anaerobic bile cultures. If surgery is pursued, acquisition of additional hepatic tissue samples for potential copper quantitation is recommended. A contrast abdominal CT scan could be useful in ruling out an intrahepatic vascular anomaly but this differential is considered less likely.

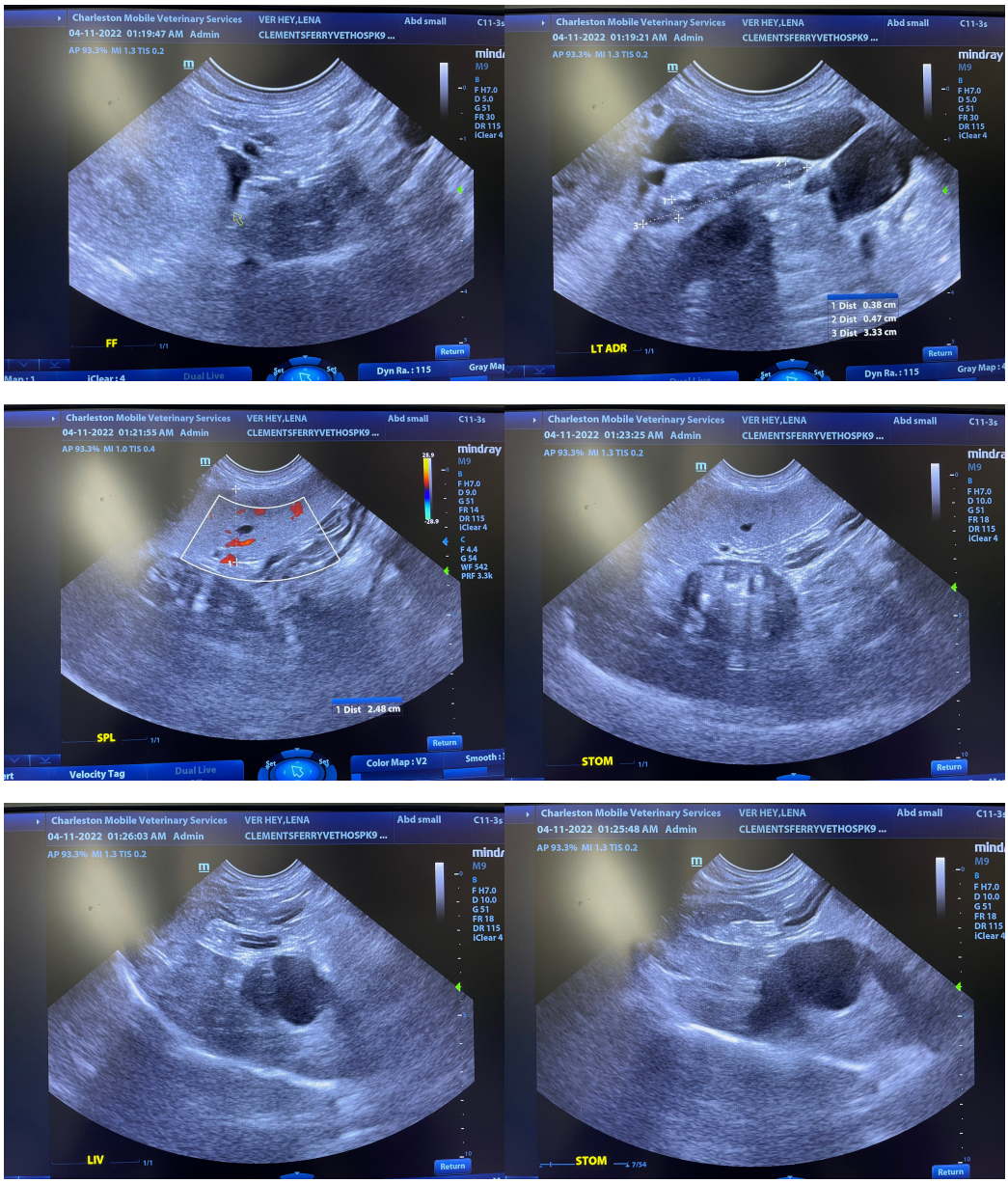

SonoPath
Clinical Sonography & Telecytology
EDUCATIONAL TELECONSULTATION SERVICES™
1-800-838-4268 info@sonopath.com SonoPath.com

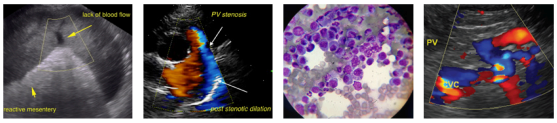

Charleston Mobile Veterinary Services
IMAGING PERFORMED BY
CharlestonMobile.Net 800.403.5408

PATIENT

Lena Ver Hey

SPECIES

Canine

BREED

Goldendoodle

SEX

Intact Female

AGE

10/10/21

WEIGHT

52 lbs

INTERPRETED BY

Andrea Nicastro, DVM, Diplomate ACVIM (*Small Animal Internal Medicine*)

IMAGING PERFORMED BY

Andrea Nicastro, DVM, Diplomate ACVIM (*Small Animal Internal Medicine*)

HOSPITAL NAME

Clements Ferry Vet

REFERRING VET

Dr. Kaitlyn Thomas

INVOICE

36777

DATE

4/11/22

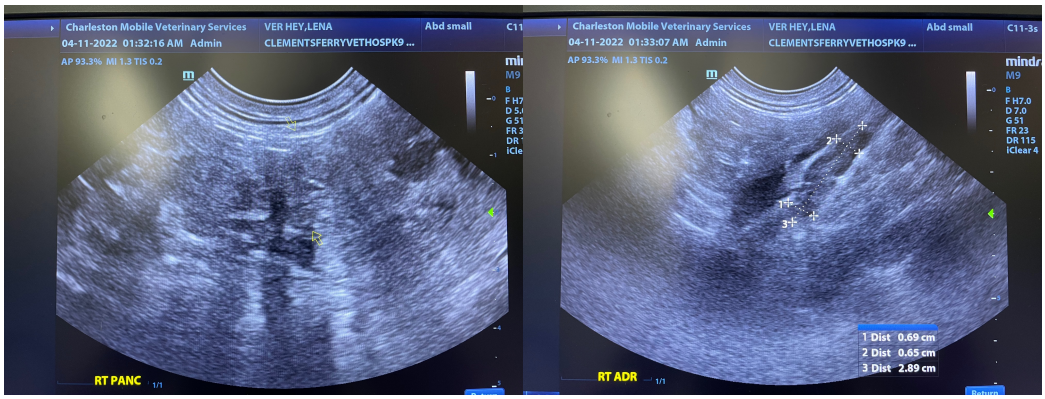

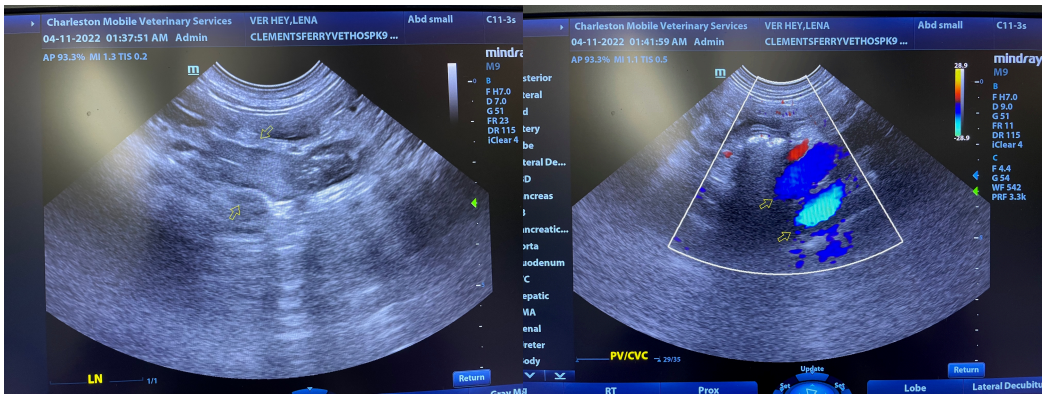

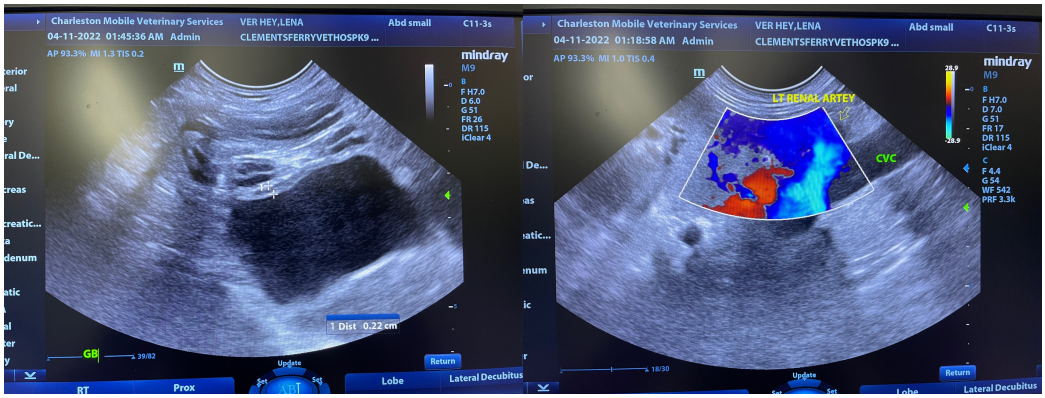

The information and recommendations provided are based on the images presented by the referring veterinarian/sonographer. No evaluation can be communicated regarding pathology that was not visible in the image/video clips provided.

Thank you for this referral. If the clinical or image interpretation does not parallel your findings or if I can be of any further assistance please contact me.

Andrea Nicastro, DVM, Diplomate DACVIM (Small Animal Internal Medicine)
info@SonoPath.com