

**DATE PRESENTING CLINICAL SIGNS**

4/11/22

Recent diagnosis of cutaneous high grade MCT, complete excision. Staging today with AUS and TRX.

PATIENT

Current Medications: None listed.

Date of Previous IntraPet Ultrasound: No previous.

Sedation: Patient sedated with Dexdomitor for relaxation of abdominal wall.

Stat Report: Not requested.

Jax Zellwegerr

SPECIES

Imaging Performed By: Andi Parkinson, RDMS.

Canine

BREED**ULTRASONOGRAPHIC EXAMINATION OF THE ABDOMEN****Urinary System**

The urinary bladder and visible portion of the pelvic urethra are normal for the degree of luminal distension. The urine is mostly anechoic with no evidence of debris. Cystic calculi and discrete masses are not observed. The region of the trigone and the visible portion of the proximal urethra are normal.

SEX

Male, neutered

The prostate is normal in size (1.08 cm in width) and shape. Parenchyma is homogenous. The prostatic urethra appears normal without evidence of dilation or obstruction.

AGE

9/23/2017

The left kidney is normal size (6.79 cm in length); normal shape and architecture with smooth peripheral margins. There is a normal 1:3 cortex to medulla ratio with normal corticomedullary distinction. There is no evidence of pyelectasia, nephroliths, infarcts or hydroureter.

WEIGHT

52.8 lbs.

The right kidney is normal size (6.70 cm in length); normal shape and architecture with smooth peripheral margins. There is a normal 1:3 cortex to medulla ratio with normal corticomedullary distinction. There is no evidence of pyelectasia, nephroliths, infarcts or hydroureter.

INTERPRETED BY

Andrea Nicastro, DVM,
 Diplomate ACVIM
 (Small Animal Internal
 Medicine)

Adrenal Glands

The left adrenal gland is normal size (0.56 cm at cranial pole) (0.71 cm at caudal pole) (2.39 cm in length); normal shape; homogenous parenchyma. The glandular echogenicity and detail are unremarkable. Capsule, cortex, and medullary definition are normal. The phrenicoabdominal vein and surrounding vasculature are normal.

HOSPITAL NAME

Timonium AH

The right adrenal gland is normal size (0.74 cm at cranial pole) (0.64 cm at caudal pole) (2.84 cm in length); normal shape; homogenous parenchyma. The glandular echogenicity and detail are unremarkable. Capsule, cortex, and medullary definition are normal. The phrenicoabdominal vein and surrounding vasculature are normal.

REFERRING VET

Dr. McIntyre

Spleen

The spleen is normal in size (1.67 cm in width at the level of the hilus) with a normal capsular contour. There is appropriate echogenicity and echotexture. No focal lesions are observed. Splenic vasculature is normal.

INVOICE

13180

Liver

The liver is subjectively normal in size with normal contours and structure. There is appropriate echogenicity and echotexture. No overt structural evidence of inflammatory, infiltrative or regenerative pathology is evident. Vascular and biliary tracts are of normal volume with no evidence of congestion. No pathological hepatic lymphadenopathy observed. The gall bladder lumen is moderately distended. The wall is thin and smooth. Luminal contents are anechoic. The cystic and common bile ducts are normal/not seen.

Gastrointestinal

The gastric lumen is not distended. The gastric wall is normal in thickness with a normal layering pattern. The small intestinal lumen is not dilated. The small intestinal wall thickness is normal with a normal layering pattern and appropriate mural detail. Discreet masses are not identified. The colonic wall is normal. No obstructive disease is noted.

Pancreas

The region of the pancreas is isoechoic relative to surrounding omental fat. No obvious parenchymal abnormalities are observed. There is no evidence of regional inflammation or effusion.

Free Abdomen

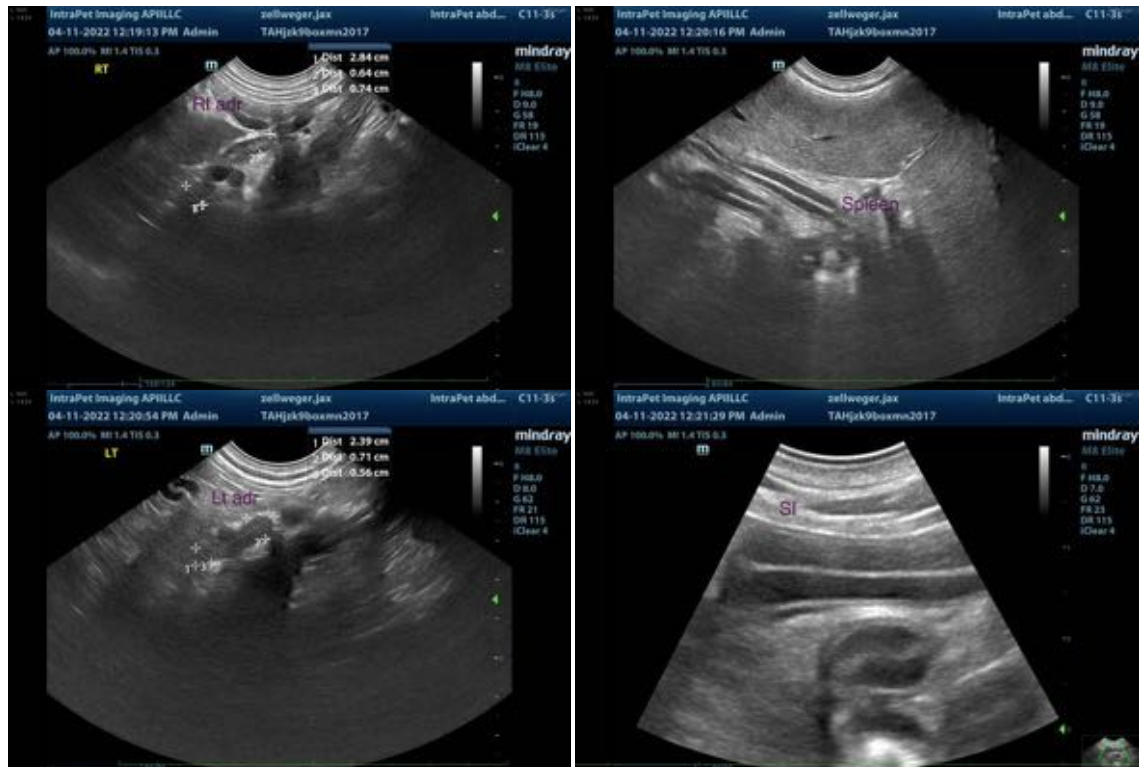
The peritoneal cavity is normal. There is no evidence of inflammation or effusion. The abdominal lymph nodes are normal/not visible.

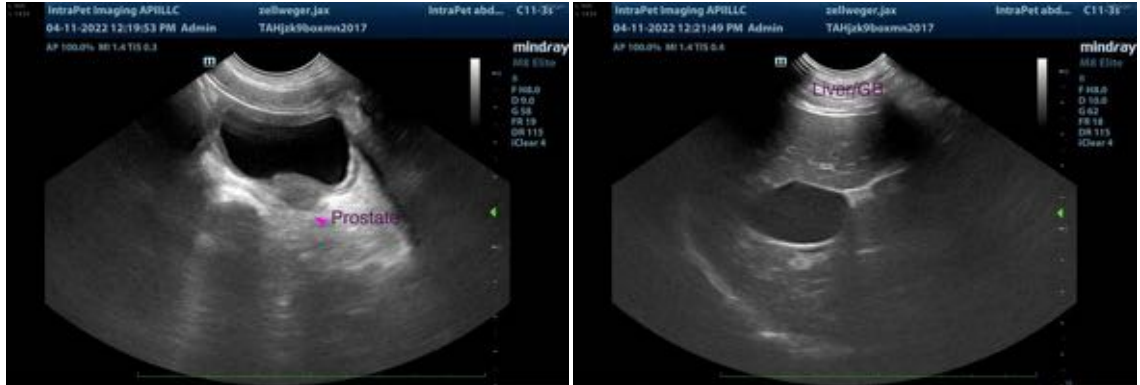
ULTRASONOGRAPHIC FINDINGS

- Unremarkable abdomen. There is no obvious evidence of metastatic disease in the abdomen.

INTERPRETATION OF THE FINDINGS & FURTHER RECOMMENDATIONS

- Consultation with a board-certified oncologist is recommended for further treatment and follow up recommendations.





The information and recommendations provided are based on the images presented by the referring veterinarian. No evaluation can be communicated regarding pathology that was not visible in the image/video clips provided.

Thank you for this referral. If the clinical or image interpretation does not parallel your findings or if I can be of any further assistance please contact me.

Andrea Nicastro, DVM, Diplomate ACVIM (*Small Animal Internal Medicine*)
Andrea.nicastro@sonopath.com