

**DATE PRESENTING CLINICAL SIGNS**

4/1/2022 3/16/22 - Presenting with FUO and general ADR, poor appetite. Has had a left sided heart murmur since 2018 and present on exam. Previous RADs have shown a WNL heart silhouette. BW WNL. Started on Clavamox and Carprofen. 3/18-3/24 - Fever resolved, but still ADR and poor appetite. No significant changes on exam and very BAR/accepting treats in clinic. Stretched out carprofen for a few more days and instructed to finish clavamox. 3/30 - Fever returned and BW now has neutrophilia and hyperbilirubinemia/elevated ALP. RADs show hepatomegaly

SPECIES

Canine

Current Medications: Carprofen 75mg PO SID, Augmentin 312.5mg PO BID, Enrofloxacin 340mg PO SID, Enalapril 10mg PO BID.

BREED

Pitbull

Lab Results: 3/16 - ALP 75, bilirubin 0.5 WBC 2.8k. 3/18 - WBC 10k. 3/30 - ALP 1200, bilirubin 1.1, WBC 35k

Date of Previous IntraPet Ultrasound: No previous.

Sedation: Not required to complete full diagnostic ultrasound.

Stat Report: Not requested.

SEX

Spayed Female

Imaging Performed By: Andi Parkinson, RDMS.

AGE

5/6/2010

ULTRASONOGRAPHIC EXAMINATION OF THE ABDOMEN**WEIGHT**

42.6 lbs

Urinary System

The urinary bladder, trigone, and pelvic urethra are normal in thickness and the mucosal surface is smooth. The bladder lumen is moderately distended with anechoic urine. No masses, inflammatory changes or calculi are observed. Ureteral papillae and visualized portion of the proximal urethra, visible to a depth of 2 cm, are normal.

INTERPRETED BY

Andrea Nicastro, DMV,
Diplomate DACVIM
(Small Animal
Internal Medicine)

The left kidney is normal size (6.53 cm in length); normal shape and architecture with smooth peripheral margins. There is a normal 1:3 cortex to medulla ratio with minimal to mild to moderate loss of corticomedullary distinction. There is no evidence of pyelectasia, nephroliths, infarcts or hydronephrosis.

The right kidney is normal size (5.97 cm in length); normal shape and architecture with smooth peripheral margins. There is a normal 1:3 cortex to medulla ratio with minimal to mild to moderate loss of corticomedullary distinction. There is no evidence of pyelectasia, nephroliths, infarcts or hydronephrosis.

HOSPITAL NAME

Pleasantville Animal
Hospital

Adrenal Glands

The left adrenal gland is normal size (0.69 cm at cranial pole) (0.69 cm at caudal pole) (2.47 cm in length); normal shape; homogenous parenchyma. The glandular echogenicity and detail are unremarkable. Capsule, cortex, and medullary definition are normal. The phrenicoabdominal vein and surrounding vasculature are normal.

REFERRING VET

Dr. Gounaris

The right adrenal gland is normal size (0.74 cm at caudal pole) (2.46 cm in length); normal shape; homogenous parenchyma. The glandular echogenicity and detail are unremarkable. Capsule, cortex, and medullary definition are normal. The phrenicoabdominal vein and surrounding vasculature are normal.

INVOICE

10647

Spleen

The spleen is normal in size (2.11 cm in width at the level of the hilus) with a normal capsular contour. There is appropriate echogenicity and echotexture. No focal lesions are observed. Splenic vasculature is normal.

Liver

The liver is subjectively prominent in size with slightly swollen peripheral contours. The parenchyma is hypoechoic to isoechoic relative to the spleen and heterogenous in appearance. A 1.78 cm irregular, hypoechoic nodule is observed at the caudal aspect. Hepatic vasculature and intrahepatic biliary tracts are of normal volume with no evidence of congestion.

The gall bladder lumen is over distended. The wall is normal in thickness. The lumen is filled with a large amount of aggregated echogenic, congealed, suspended sludge. The mesentery surrounding the gall bladder is mildly hyperechoic. The cystic and common bile ducts are normal/not seen.

Gastrointestinal

The stomach and intestine are free of stasis and exhibit normal peristaltic activity. The gastric lumen is mildly fluid distended. The gastric wall and pylorus are normal in thickness with a normal layering pattern. The small intestinal lumen is not dilated. The small intestinal wall thickness is normal with a normal layering pattern and appropriate mural detail. Discrete masses are not identified. The colonic wall is normal. No obstructive or overt infiltrative disease is noted.

Pancreas

The region of the pancreas is isoechoic relative to surrounding omental fat. No obvious parenchymal abnormalities are observed. There is no evidence of regional inflammation or effusion.

Free Abdomen

The peritoneal cavity is normal. There is no evidence of inflammation or effusion. The abdominal lymph nodes are normal/not visible.

ULTRASONOGRAPHIC FINDINGS

Primary Findings

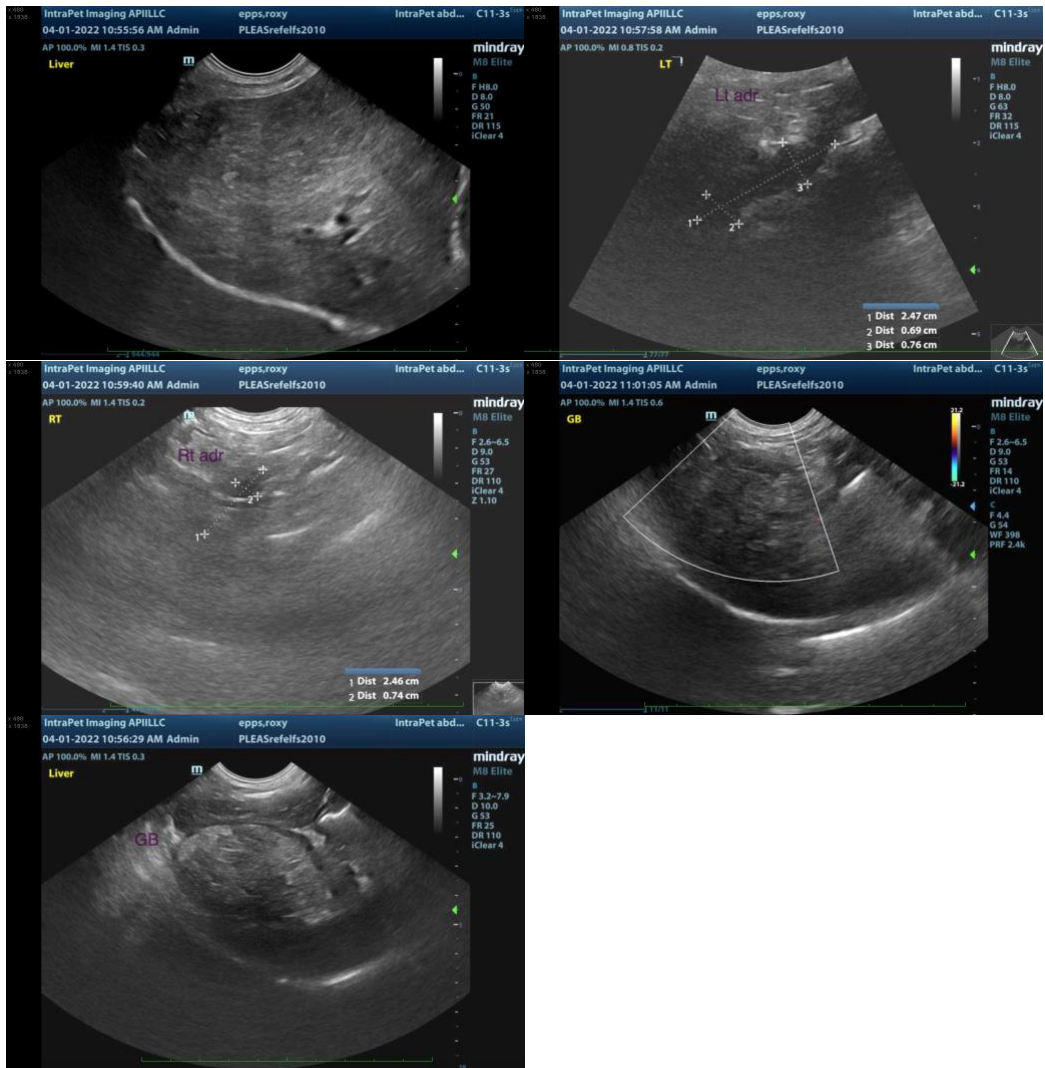
- Gall bladder mucocele with suspected mild regional peritonitis
- The hepatic parenchymal changes are nonspecific and could be secondary to a benign age-related process (i.e., regenerative nodular hyperplasia, vacuolar hepatopathy). Alternatively, a more pathologic hepatopathy (i.e., inflammatory disease) may be present. Concurrent cholecystitis is also a consideration, particularly given the recent history of a fever.

Secondary Findings

- Bilateral nonspecific age-related renal changes

INTERPRETATION OF THE FINDINGS & FURTHER RECOMMENDATIONS

- Given the gall bladder changes, a cholecystectomy should be considered due to the risk of potential rupture. If surgery is pursued, a liver biopsy should also be obtained. Three-view thoracic radiographs should be performed prior to anesthesia.
- In the meantime, empirical treatment for cholangiohepatitis is recommended, including broad-spectrum antibiotics, fluid therapy (as needed) and Ursodiol.



The information and recommendations provided are based on the images presented by the referring veterinarian/sonographer. No evaluation can be communicated regarding pathology that was not visible in the image/video clips provided.

Thank you for this referral. If the clinical or image interpretation does not parallel your findings or if I can be of any further assistance, please contact me.

Andrea Nicastro, DVM, Diplomate DACVIM (Small Animal Internal Medicine)
info@SonoPath.com