



PATIENT PRESENTING CLINICAL SIGNS

History: Continued weight loss
Abnormal PE/Chem/CBC/UA Results: Bloodwork done in January 2026, glucose 378, lipase >1800 Fructosamine in February, 278 PE unremarkable, no other symptoms

SPECIES

Canine

BREED

Mixed

SEX

Female Spayed

AGE

9

WEIGHT

26.8

INTERPRETED BY

Andrea Nicastro, DVM,
 Diplomate ACVIM
 (Small Animal Internal
 Medicine)

IMAGING PERFORMED BY

Chelsea Pastor

HOSPITAL NAME

Fredon AH

REFERRING VET

Michelle Roche

INVOICE

22664

DATE

3-9-26

ULTRASONOGRAPHIC EXAMINATION OF THE ABDOMEN

Urinary System

The urinary bladder wall is normal in thickness. The mucosal surface is smooth. The bladder is moderately distended. Luminal contents are mostly anechoic. No cystic calculi are observed. The region of the trigone is normal.

The left kidney is normal in size (5.63 cm in length) with a normal shape, architecture and smooth peripheral margins. There is a normal 1:3 cortex to medulla ratio with minimal- to mild loss of corticomedullary distinction. An ill-defined hyperechoic medullary band is observed at the corticomedullary junction. There is no evidence of pyelectasia, nephroliths, infarcts or hydroureter. Renal vasculature is normal.

The right kidney is normal in size (4.91 cm in length) with a normal shape, architecture and smooth peripheral margins. There is a normal 1:3 cortex to medulla ratio with minimal- to mild loss of corticomedullary distinction. An ill-defined hyperechoic medullary band is observed at the corticomedullary junction. There is no evidence of pyelectasia, nephroliths, infarcts or hydroureter. Renal vasculature is normal.

Adrenal Glands

The left adrenal gland is normal in size at the cranial pole and enlarged at the caudal pole (0.58 cm at cranial pole) (1.38 cm at caudal pole). A 1.59 x 1.38 cm hyperechoic- to heterogenous nodule is observed at the caudal pole. Glandular echogenicity and detail at the cranial pole normal. Surrounding vasculature appears normal.

The region of the right adrenal gland is evaluated. No obvious pathology is observed in this region.

Spleen

The spleen is normal in size (1.30 cm in width at the level of the hilus) with a normal capsular contour. There is appropriate echogenicity and echotexture. No focal lesions are observed. Splenic vasculature is normal.

Liver

The liver is subjectively enlarged, with swollen peripheral contours. The parenchyma is hyperechoic relative to the spleen, attenuating and subtly mottled in appearance. Hepatic vasculature and intrahepatic biliary tracts are of normal volume with no evidence of congestion.

The gallbladder lumen is moderately distended. The wall is thin and smooth. A few polypoid-like lesions are arising from the mucosal surface. A small- to moderate amount of aggregated, echogenic partially dependent debris/sludge is observed within the lumen. The cystic and common bile ducts are normal/not seen.

Gastrointestinal

The gastric lumen is not distended. The gastric wall is normal in thickness with a normal layering pattern. The small intestinal lumen is not dilated. The small intestinal wall is normal in thickness with a normal layering pattern and appropriate mural detail. Discreet masses are not identified. The colonic wall is normal. There is no evidence of an obstructive pattern.



PATIENT

Bailey Teets

SPECIES

Canine

BREED

Mixed

SEX

Female Spayed

AGE

9

WEIGHT

26.8

INTERPRETED BY

Andrea Nicastro, DVM,
Diplomate ACVIM
(Small Animal Internal
Medicine)

IMAGING PERFORMED BY

Chelsea Pastor

HOSPITAL NAME

Fredon AH

REFERRING VET

Michelle Roche

INVOICE

22664

DATE

3-9-26

Pancreas

The right limb of the pancreas is visible with normal curvilinear peripheral contours. The parenchyma is largely hyperechoic relative to surrounding omental fat and slightly mottled in appearance. The pancreatic duct is visible but not overtly dilated. There is no evidence of peripancreatic inflammation or effusion.

Lymph Nodes

The abdominal lymph nodes are normal/not visible.

Free Abdomen

There is no obvious evidence of free fluid.

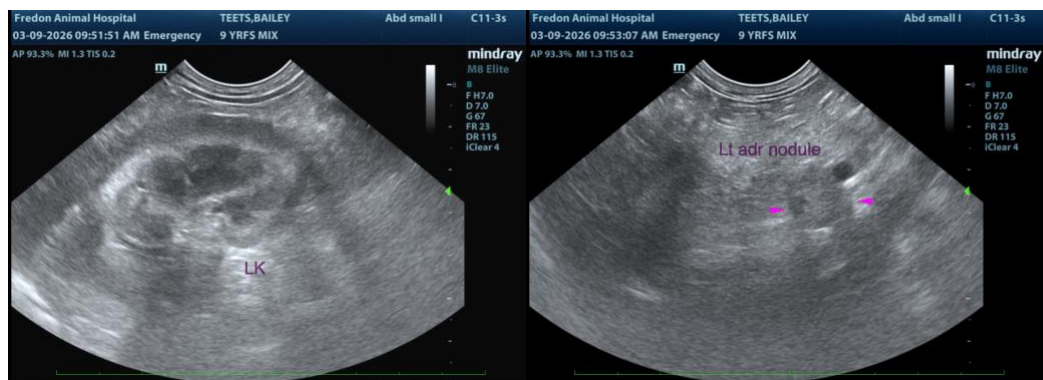
ULTRASONOGRAPHIC FINDINGS

- The bilateral renal changes are most consistent with a diabetic nephropathy.
- The hepatic changes are most consistent with a diabetic hepatopathy. Other considerations include vacuolar hepatopathy (i.e., idiopathic/endocrine), inflammatory disease, infiltrative neoplasia, and/or other hepatopathy. Correlation with the patient's liver values is recommended.
- The pancreatic changes are most consistent with age-related parenchymal remodeling, potentially secondary to a prior inflammatory episode, early fibrosis or chronic pancreatitis.
- The left adrenal nodule could be consistent with focal nodular hyperplasia, adenoma, emerging adenocarcinoma or pheochromocytoma, other.

*An obvious cause for the patient's weight loss is not identified in this study. Broad considerations include occult neoplasia, primary enteropathy, underlying metabolic issue, other.

INTERPRETATION OF THE FINDINGS & FURTHER RECOMMENDATIONS

- Three-view thoracic radiographs are recommended to assess for occult pathology in the chest.
- Consider a fecal evaluation for ova and Giardia, as well as a GI panel including serum cobalamin and folate, TLI and PLI.
- Depending on the results of the above diagnostics further work-up may be indicated.





PATIENT

Bailey Teets

SPECIES

Canine

BREED

Mixed

SEX

Female Spayed

AGE

9

WEIGHT

26.8

INTERPRETED BY

Andrea Nicastro, DVM,
Diplomate ACVIM
(Small Animal Internal
Medicine)

**IMAGING
PERFORMED BY**

Chelsea Pastor

HOSPITAL NAME

Fredon AH

REFERRING VET

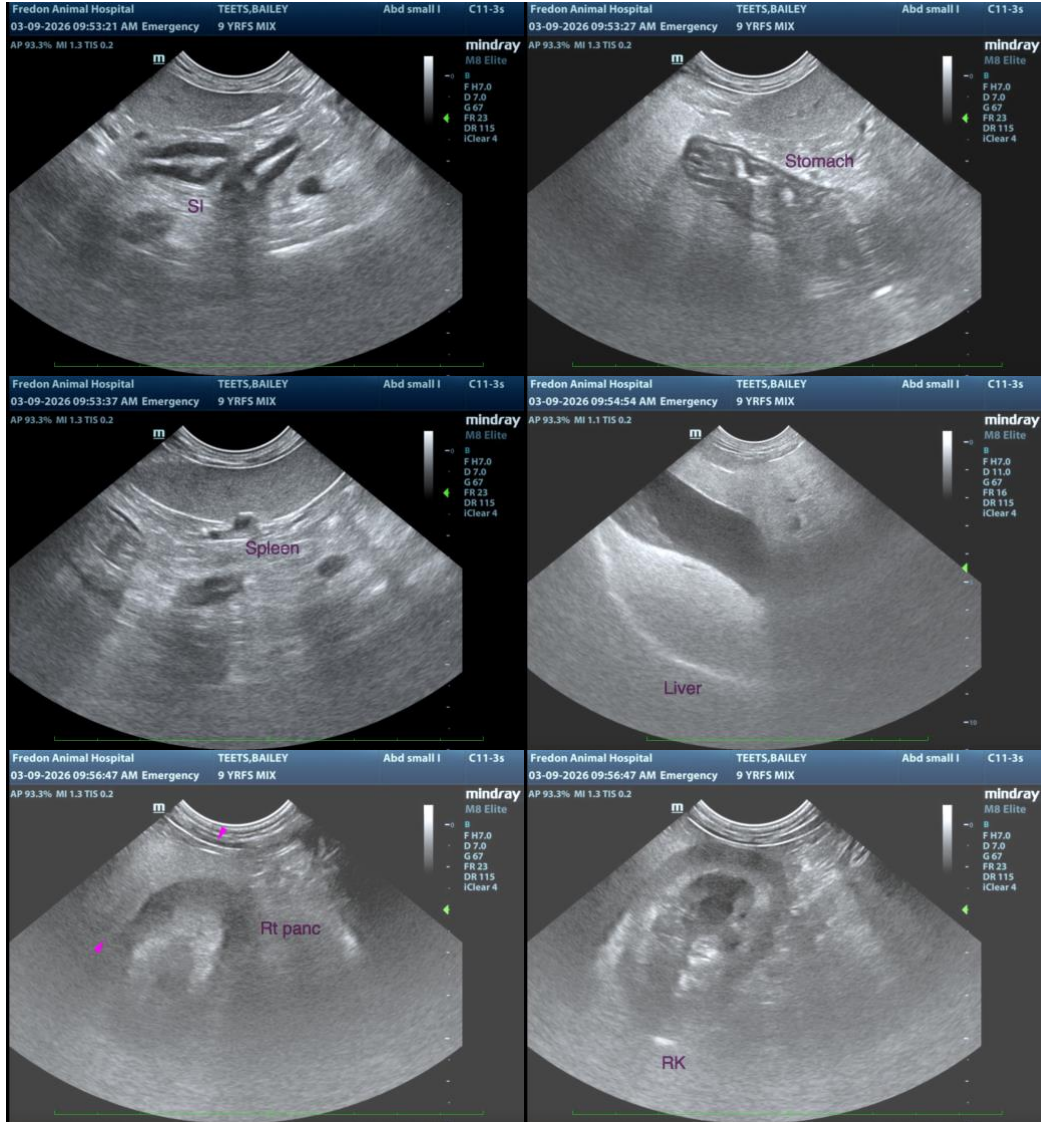
Michelle Roche

INVOICE

22664

DATE

3-9-26



The information and recommendations provided are based on the images presented by the referring veterinarian/sonographer. No evaluation can be communicated regarding pathology that was not visible in the image/video clips provided.

Thank you for this referral. If the clinical or image interpretation does not parallel your findings or if I can be of any further assistance, please contact me.

Andrea Nicastro, MPH, DVM, Diplomate DACVIM (Small Animal Internal Medicine)
info@SonoPath.com