



## PATIENT PRESENTING CLINICAL SIGNS

**Riley Cohn** History: Riley started having diarrhea a couple weeks ago. Yesterday, he started vomiting - it was bile and undigested food. He did not show interest in eating last night, which is very unusual. On physical exam, he had a tense, painful abdomen. In hospital, he passed a large clot of grass in mucus and liquid.

## SPECIES

Canine

Abnormal PE/Chem/CBC/UA Results: CBC: normal Chem: hi ALT 500 (0-120), hi ALP 300 (0-140), hi chol 399 (120-310), hi Alb 4.3 (2.5-4.0) PLI: normal 75 (0-200) Abdo x-rays: small ingesta in stomach, SI and LI gas distended, no radiopaque foreign material seen

## BREED

Airedale Terrier

## ULTRASONOGRAPHIC EXAMINATION OF THE ABDOMEN

### SEX

#### Urinary System

The urinary bladder is moderately distended. The wall is normal in thickness with a relatively smooth mucosal surface. Luminal contents appear mostly anechoic. No cystic calculi are observed.

Neutered Male

### AGE

The left kidney is normal in size (6.87 cm in length) with a normal shape, architecture and smooth peripheral margins. There is a normal 1:3 cortex to medulla ratio with mild loss of corticomedullary distinction. There is no evidence of pyelectasia, nephroliths, infarcts or hydronephrosis.

10 years 9 mos

### WEIGHT

The right kidney is normal in size (7.17 cm in length) with a normal shape, architecture and smooth peripheral margins. There is a normal 1:3 cortex to medulla ratio with minimal- to mild loss of corticomedullary distinction. There is no evidence of pyelectasia, nephroliths, infarcts or hydronephrosis.

71 lbs

### INTERPRETED BY

#### Adrenal Glands

No images provided.

Andrea Nicastro, DVM,  
Diplomate ACVIM  
(Small Animal Internal  
Medicine)

#### Spleen

The spleen is subjectively normal in size with a normal capsular contour. There is appropriate echogenicity and echotexture. A few, ill-defined hypoechoic nodules are observed (the largest measuring 2.2 x 1.5 cm). Splenic vasculature is normal.

### IMAGING PERFORMED BY

#### Liver

The liver is subjectively normal in size with normal peripheral contours. The parenchyma is hypoechoic relative to the spleen. A 3.4 x 2.8 cm slightly hypoechoic mass is observed at the caudal aspect, approximately mid-liver. The remaining parenchyma is subtly mottled in appearance. Hepatic vasculature and intrahepatic biliary tracts are of normal volume with no evidence of congestion.

Cathleen Whitcraft

### HOSPITAL NAME

Craig Road AH

The gallbladder lumen is moderately distended. The wall is thin and smooth. A scant amount of suspended echogenic debris is observed within the lumen. The cystic and common bile ducts are normal/not seen.

### REFERRING VET

Cathleen Whitcraft DVM

#### Gastrointestinal

The gastric lumen is not distended. The gastric wall is normal in thickness with a normal layering pattern. The small intestinal lumen is not dilated. The small intestinal wall is normal in thickness with a normal layering pattern and appropriate mural detail. Discreet masses are not identified. The colonic wall is normal. There is no evidence of an obstructive pattern.

### INVOICE

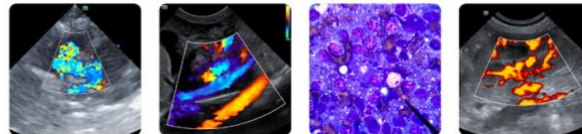
22663

#### Pancreas

### DATE

The region of the pancreas is isoechoic relative to surrounding omental fat. No obvious parenchymal abnormalities are observed. There is no evidence of regional inflammation or effusion.

3-8-26



## PATIENT

Riley Cohn

## SPECIES

Canine

## BREED

Airedale Terrier

## SEX

Neutered Male

## AGE

10 years 9 mos

## WEIGHT

71 lbs

## INTERPRETED BY

Andrea Nicastro, DVM,  
Diplomate ACVIM  
(Small Animal Internal  
Medicine)

## IMAGING PERFORMED BY

Cathleen Whitcraft

## HOSPITAL NAME

Craig Road AH

## REFERRING VET

Cathleen Whitcraft DVM

## INVOICE

22663

## DATE

3-8-26

### **Lymph Nodes**

The abdominal lymph nodes are normal/not visible.

### **Free Abdomen**

The peritoneal cavity is normal. There is no evidence of inflammation or effusion.

## **ULTRASONOGRAPHIC FINDINGS**

### **Primary Findings**

- The caudal hepatic mass could be consistent with neoplasia (i.e., adenoma, adenocarcinoma, round cell tumor). Alternatively, a benign process (i.e., regenerative nodule, inflammatory focus) is possible. An obvious cause for the elevated liver values is not definitively identified in this study. The hepatic lesion may be contributing to the elevations but does not likely explain the full picture due to its focal nature. Therefore, other hepatopathies (i.e., cholangiohepatitis, chronic hepatitis, Leptospirosis, hepatotoxicosis, fibrosis) or less likely, infiltrative neoplasia, should also be considered.

### **Secondary Findings**

- Mild bilateral nonspecific age-related renal changes
- The splenic parenchyma changes are most consistent with a benign process such as lymphoid hyperplasia, extramedullary hematopoiesis or splenitis with a lower possibility of infiltrative neoplasia (i.e., lymphoma, mast cell neoplasia).

## **INTERPRETATION OF THE FINDINGS & FURTHER RECOMMENDATIONS**

- Consider pre- and postprandial serum bile acids to assess hepatic function.
- Also consider Leptospirosis testing (i.e., blood and urine PCR, serology).
- Regarding the liver mass, consider excisional biopsy. If surgery is pursued, biopsy of other liver lobes is also recommended, along with aerobic and anaerobic bile cultures and hepatic copper quantitation. GI biopsies should also be obtained at the time of surgery. If a conservative approach is desired, consider empirical treatment for bacterial cholangiohepatitis (amoxicillin-clavulanic acid, Denamarin). If no improvement in the liver values is seen within 7-10 days of initiating therapy, antibiotics should be discontinued, and hepatic tissue sampling reconsidered. If liver values improve, continue therapy for at least 4-6 weeks and 1 week beyond normalization of the liver values.
- Regarding the vomiting and diarrhea, other considerations could include the following:
  1. Fecal evaluation for ova and Giardia
  2. Prophylactic deworming with fenbendazole
  3. GI panel including serum cobalamin and folate, TLI, PLI and resting cortisol level
- Regarding the splenic changes, consider fine-needle aspiration (assuming normal clotting status). A 25-gauge needle should be used. Particular attention should be paid to the hypochoic nodules.



## PATIENT

Riley Cohn

## SPECIES

Canine

## BREED

Airedale Terrier

## SEX

Neutered Male

## AGE

10 years 9 mos

## WEIGHT

71 lbs

## INTERPRETED BY

Andrea Nicastro, DVM,  
Diplomate ACVIM  
(Small Animal Internal  
Medicine)

## IMAGING PERFORMED BY

Cathleen Whitcraft

## HOSPITAL NAME

Craig Road AH

## REFERRING VET

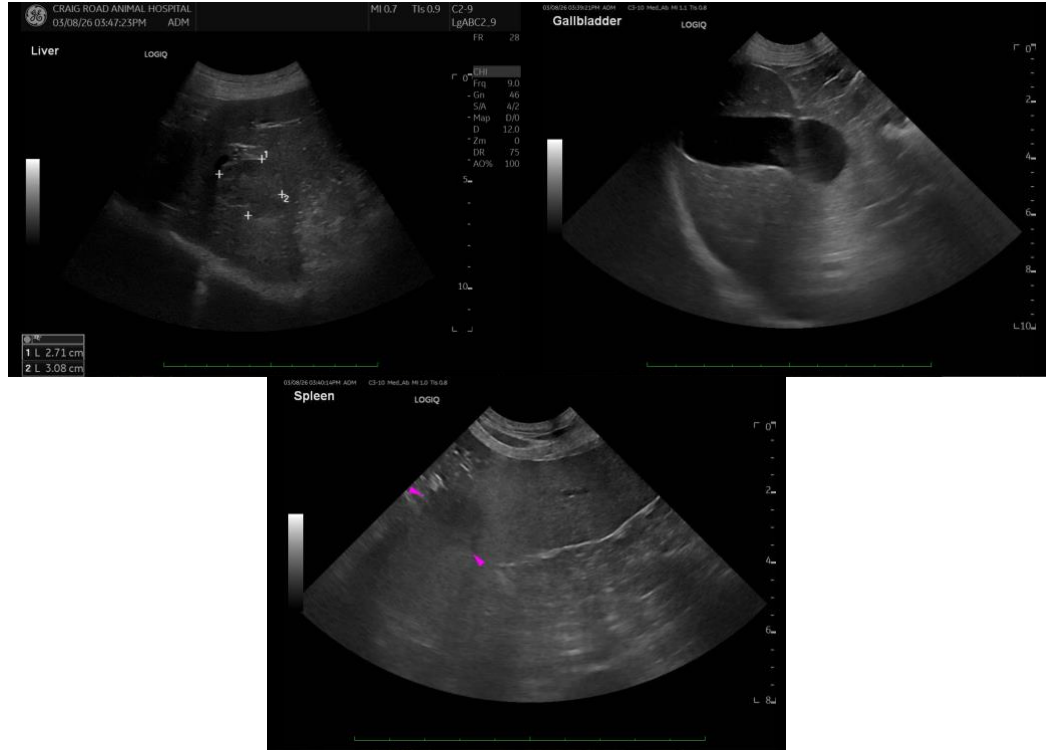Cathleen Whitcraft DVM

## INVOICE

22663

## DATE

3-8-26



The information and recommendations provided are based on the images presented by the referring veterinarian/sonographer. No evaluation can be communicated regarding pathology that was not visible in the image/video clips provided.

Thank you for this referral. If the clinical or image interpretation does not parallel your findings or if I can be of any further assistance, please contact me.

**Andrea Nicastro, MPH, DVM, Diplomate DACVIM (Small Animal Internal Medicine)**  
[info@SonoPath.com](mailto:info@SonoPath.com)