Pennsylvania Mobile
VETERINARY ULTRASOUND SERVICES

IMAGING PERFORMED BY
PAMobileVet.com 443-794-4700

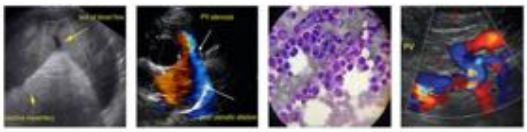

SonoPath
Clinical Sonography & Telecytology
EDUCATIONAL TELECONSULTATION SERVICES™
1-800-838-4268 info@sonopath.com SonoPath.com

PATIENT
Bentley Krishnamoorthy

SPECIES
Canine

BREED
Hound Mix

SEX
Neutered Male

AGE
2012

WEIGHT
44.8 lbs

INTERPRETED BY
Andrea Nicastro, DVM, Diplomate ACVIM (*Small Animal Internal Medicine*)

IMAGING PERFORMED BY
Rebekah Jakum

HOSPITAL NAME
New Britain VC

REFERRING VET
Bandekar

INVOICE
12355

DATE
3.8.23

PRESENTING CLINICAL SIGNS

History: Hyporexia/anorexia, lethargy.

Lab-work: CBC count unremarkable. Precision PSL negative. T4 normal.

ULTRASONOGRAPHIC EXAMINATION OF THE ABDOMEN

Urinary System

The urinary bladder wall is normal in thickness and the mucosal surface is smooth. The bladder lumen is moderately distended with anechoic urine. No masses, inflammatory changes or calculi are observed. The region of the trigone and visible portion of the proximal urethra are normal.

The prostate is normal in size (0.98 cm in width) and shape. Parenchyma is homogenous. The prostatic urethra appears normal without evidence of dilation or obstruction.
The left kidney is normal in size (6.43 cm in length) with a normal shape, architecture and smooth peripheral margins. There is a normal 1:3 cortex to medulla ratio with mild loss of corticomedullary distinction. There is no evidence of pyelectasia, nephroliths, infarcts or hydroureter. Renal vasculature is normal.

The right kidney is normal in size (6.27 cm in length) with a normal shape, architecture and smooth peripheral margins. There is a normal 1:3 cortex to medulla ratio with mild loss of corticomedullary distinction. There is no evidence of pyelectasia, nephroliths, infarcts or hydroureter. Renal vasculature is normal.

Adrenal Glands

The left adrenal gland is small in size (0.57 cm at cranial pole) (0.37 cm at caudal pole) (2.09 cm in length) with a slightly flattened contour. The glandular echogenicity and detail are unremarkable. Capsule, cortex, and medullary definition are normal. The phrenicoabdominal vein and surrounding vasculature are normal.

What is thought to be right adrenal gland is normal in length with a flattened contour (0.47 cm at cranial pole) (0.43 cm at caudal pole) with a normal shape and homogenous parenchyma. The glandular echogenicity and detail are unremarkable. Capsule, cortex, and medullary definition are normal. The phrenicoabdominal vein and surrounding vasculature are normal.

Spleen

The spleen is normal in size (1.55 cm in width at the level of the hilus) with a normal capsular contour. The parenchyma is subtly mottled in appearance. No focal lesions are observed. Splenic vasculature is normal.

Liver

The liver is subjectively normal in size with normal curvilinear peripheral contours. The parenchyma is hypoechoic relative to the spleen with minor changes consistent with age-related remodeling. No focal lesions are observed. Hepatic vasculature and biliary tracts are of normal volume with no evidence of congestion.
The gall bladder lumen is moderately distended. The wall is thin and smooth. Luminal contents are anechoic. The cystic and common bile ducts are normal/not seen.

Gastrointestinal

The lumen is not distended. The gastric wall is normal in thickness with a normal layering pattern. The small intestinal lumen is not dilated. The small intestinal wall thickness is normal with a normal layering pattern and appropriate mural detail. Discreet masses are not identified. The colonic wall is normal. There is no evidence of an obstructive pattern.

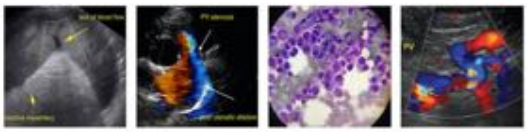

PATIENT

Bentley Krishnamoorthy

SPECIES

Canine

BREED

Hound Mix

SEX

Neutered Male

AGE

2012

WEIGHT

44.8 lbs

INTERPRETED BY

Andrea Nicastro, DVM, Diplomate ACVIM (*Small Animal Internal Medicine*)

IMAGING PERFORMED BY

Rebekah Jakum

HOSPITAL NAME

New Britain VC

REFERRING VET

Bandekar

INVOICE

12355

DATE

3.8.23

Pancreas
The region of the pancreas is isoechoic relative to surrounding omental fat. No obvious parenchymal abnormalities are observed. There is no evidence of regional inflammation or effusion.

Free Abdomen
The peritoneal cavity is normal. There is no evidence of inflammation or effusion. The abdominal lymph nodes are normal/not visible.

ULTRASONOGRAPHIC FINDINGS

Findings

- Minor geriatric renal and hepatic changes
- The splenic parenchymal changes are most consistent with a benign process such as lymphoid hyperplasia, extramedullary hematopoiesis, splenitis or antigenic stimulation with a low possibility of infiltrative neoplasia (i.e., lymphoma, mast cell neoplasia).
- The flattened adrenal glands may be a normal variant or could be consistent with early atrophy (i.e., secondary to hypoadrenocorticism). Given the patient's age, this differential is considered less likely.

  *An obvious cause for the patient's clinical signs is not definitively identified in this study. Considerations include microscopic gastrointestinal disease, underlying metabolic issue (i.e., hypoadrenocorticism), occult neoplasia, orthopedic or neurologic disease, other.

INTERPRETATION OF THE FINDINGS & FURTHER RECOMMENDATIONS

- Three-view thoracic radiographs are recommended to assess for occult disease in the chest.
- Consider a malabsorption panel, including serum cobalamin and folate, TLI, PLI and resting cortisol level to screen for underlying small intestinal and pancreatic disease and hypoadrenocorticism.
- Orthopedic and neurologic examinations are recommended to assess for nonmetabolic causes for the patient's clinical signs.
- A comprehensive tick panel can also be considered.

Pennsylvania Mobile
VETERINARY ULTRASOUND SERVICES

IMAGING PERFORMED BY
PAMobileVet.com 443-794-4700

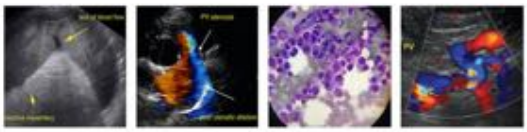

SonoPath
Clinical Sonography & Telecytology
EDUCATIONAL TELECONSULTATION SERVICES™
1-800-838-4268 info@sonopath.com SonoPath.com

PATIENT

Bentley Krishnamoorthy

SPECIES

Canine

BREED

Hound Mix

SEX

Neutered Male

AGE

2012

WEIGHT

44.8 lbs

INTERPRETED BY

Andrea Nicastro, DVM, Diplomate ACVIM (*Small Animal Internal Medicine*)

IMAGING PERFORMED BY

Rebekah Jakum

HOSPITAL NAME

New Britain VC

REFERRING VET

Bandekar

INVOICE

12355

DATE

3.8.23

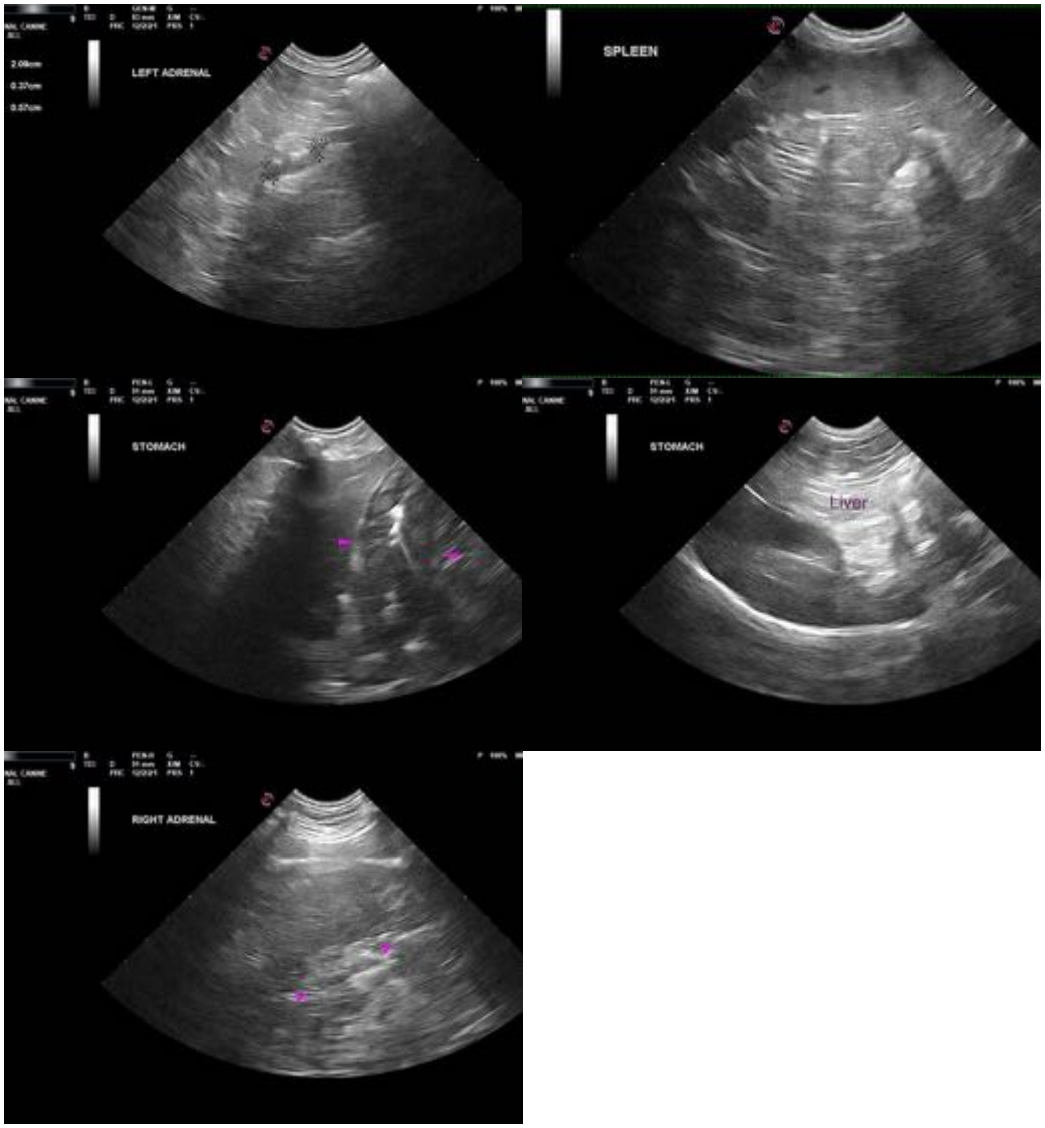

The information and recommendations provided are based on the images presented by the referring veterinarian/sonographer. No evaluation can be communicated regarding pathology that was not visible in the image/video clips provided.

Thank you for this referral. If the clinical or image interpretation does not parallel your findings or if I can be of any further assistance, please contact me.
Andrea Nicastro, MPH, DVM, Diplomate DACVIM (Small Animal Internal Medicine)
info@SonoPath.com