

**DATE PRESENTING CLINICAL SIGNS**

3/7/23

Hx mild chronic weight loss, increasingly finicky appetite. Hx copper storage liver dz based on liver bx from AVIM. Icteric on PE, no abdominal pain.

PATIENT

Checkers Fabian

Current Medications: Penicillamine 100 mg PO BID, Denamarin 225 mg PO SID
 Lab Results: 3/1/23: CBC WNL (HCT 49%, stable). Chem: ALT 985 (previously 600-800), ALP 1699 (previously 500-700), tBili 4.0 (previously 0.3), GGT 18 (previously 16).

Date of Previous IntraPet Ultrasound: No previous.

Sedation: Not required to complete full diagnostic ultrasound.

Stat Report: Not requested.

Imaging Performed By: Andi Parkinson, BS, RDMS.

SPECIES

Canine

BREED

Terrier mix

SEX

Male, neutered

AGE

8/17/2016

WEIGHT

19.5 lbs.

INTERPRETED BY

Andrea Nicastro, DVM,
 Diplomate ACVIM
 (Small Animal Internal
 Medicine)

HOSPITAL NAME

Timonium AH

REFERRING VET

Dr. McIntyre

INVOICE

14708

ULTRASONOGRAPHIC EXAMINATION OF THE ABDOMEN**Urinary System**

The urinary bladder wall is normal in thickness and the mucosal surface is smooth. The bladder lumen is mildly distended. A small amount of echogenic to mineralized debris, some of which is suspended and some of which is gravity-dependent is observed within the lumen. No masses, inflammatory changes or calculi are observed. Ureteral papillae and visualized portion of the proximal urethra, visible to a depth of 2 cm, are normal.

The prostate is normal in size (0.88 cm in width) and shape. Parenchyma is homogenous. The prostatic urethra appears normal without evidence of dilation or obstruction.

The left kidney is normal size (5.12 cm in length); normal shape and architecture with smooth peripheral margins. There is a normal 1:3 cortex to medulla ratio with mild loss of corticomedullary distinction. There is no evidence of pyelectasia, nephroliths, infarcts or hydroureter.

The right kidney is normal size (5.04 cm in length); normal shape and architecture with smooth peripheral margins. There is a normal 1:3 cortex to medulla ratio with mild loss of corticomedullary distinction. There is no evidence of pyelectasia, nephroliths, infarcts or hydroureter.

Adrenal Glands

The left adrenal gland is normal size (0.33 cm at cranial pole) (0.48 cm at caudal pole) (1.88 cm in length); normal shape; homogenous parenchyma. The glandular echogenicity and detail are unremarkable. Capsule, cortex, and medullary definition are normal. The phrenicoabdominal vein and surrounding vasculature are normal.

The right adrenal gland is normal size (0.81 cm at cranial pole) (0.49 cm at caudal pole); normal shape; homogenous parenchyma. The glandular echogenicity and detail are unremarkable. Capsule, cortex, and medullary definition are normal. The phrenicoabdominal vein and surrounding vasculature are normal.

Spleen

The spleen is normal in size (1.83 cm in width at the level of the hilus) with a normal capsular contour. A light micronodular pattern is observed throughout the organ. No focal lesions are observed. Splenic vasculature is normal.

Liver

The liver is subjectively normal in size with slightly irregular peripheral contours. The parenchyma is isoechoic relative to the spleen and slightly mottled in appearance. No distinct focal lesions are observed. Vascular and biliary tracts are of normal volume with no evidence of congestion. The portal vein to caudal vena cava ratio is approximately 1:1. The gall bladder lumen is moderately distended. The wall is thin and

smooth. A small amount of suspended echogenic debris is observed within the lumen. The cystic and common bile ducts are normal/not seen.

Gastrointestinal

The stomach and intestine are free of stasis and exhibit normal peristaltic activity. The gastric lumen is not distended. The gastric wall and pylorus are normal in thickness with a normal layering pattern. The pyloric outflow tract is patent. The small intestinal lumen is segmentally dilated with gas and chyme (mild). The small intestinal wall thickness is normal with a normal layering pattern and appropriate mural detail. Discreet masses are not identified. The colonic wall is normal. No obstructive disease is noted.

Pancreas

The base and right limb are prominent to enlarged with irregular peripheral contours. The parenchyma is hypoechoic relative to surrounding omental fat and mottled in appearance. The pancreatic duct measured 0.30 cm in diameter. The mesentery surrounding the pancreas is hyperechoic to saponified. See also *Other*.

Free Abdomen

A small amount of free fluid is visualized.

Lymph Nodes

1-2 sublumbar lymph nodes are visible/prominent, the largest measuring 0.87 cm in length. See also *Other*.

Other

In the right cranial quadrant, a 2.47 x 1.11 cm ill-defined hypoechoic structure is visualized adjacent to the portal vein.

ULTRASONOGRAPHIC FINDINGS

Primary Findings:

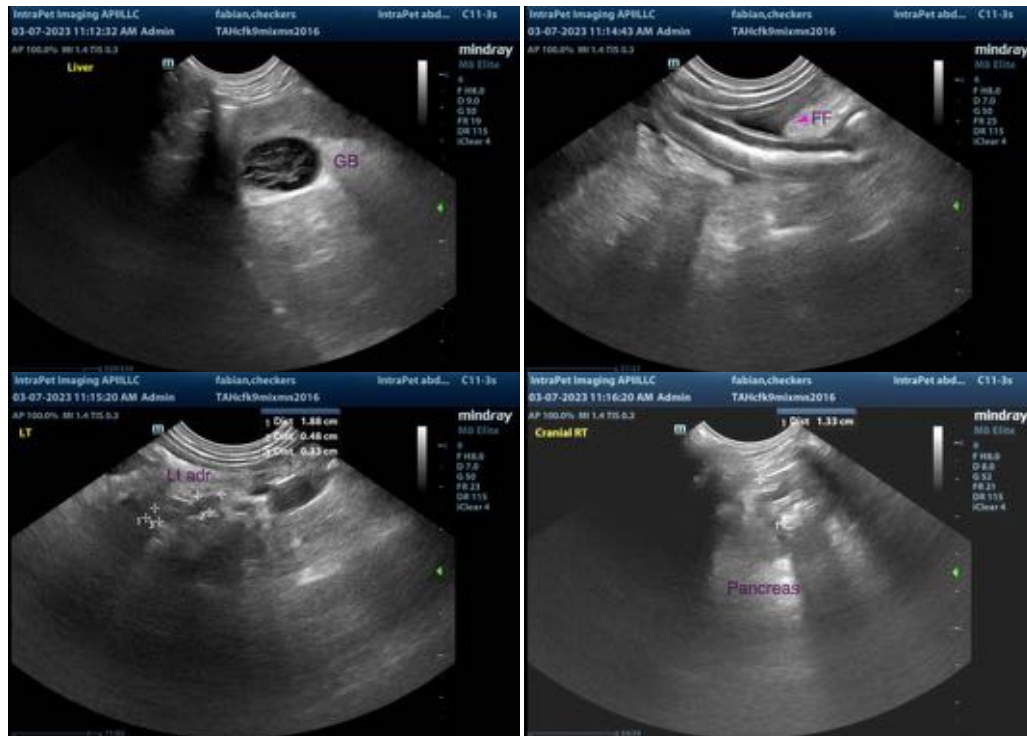
- The pancreatic changes are consistent with moderate pancreatitis with adjacent peritonitis.
- Non-specific diffuse hepatopathy. Differentials include hepatotoxicity (i.e., copper; previously diagnosed), inflammatory hepatopathy (i.e., bacterial cholangiohepatitis, chronic hepatitis), Leptospirosis, fibrosis, infiltrative neoplasia (less likely), other hepatopathy.

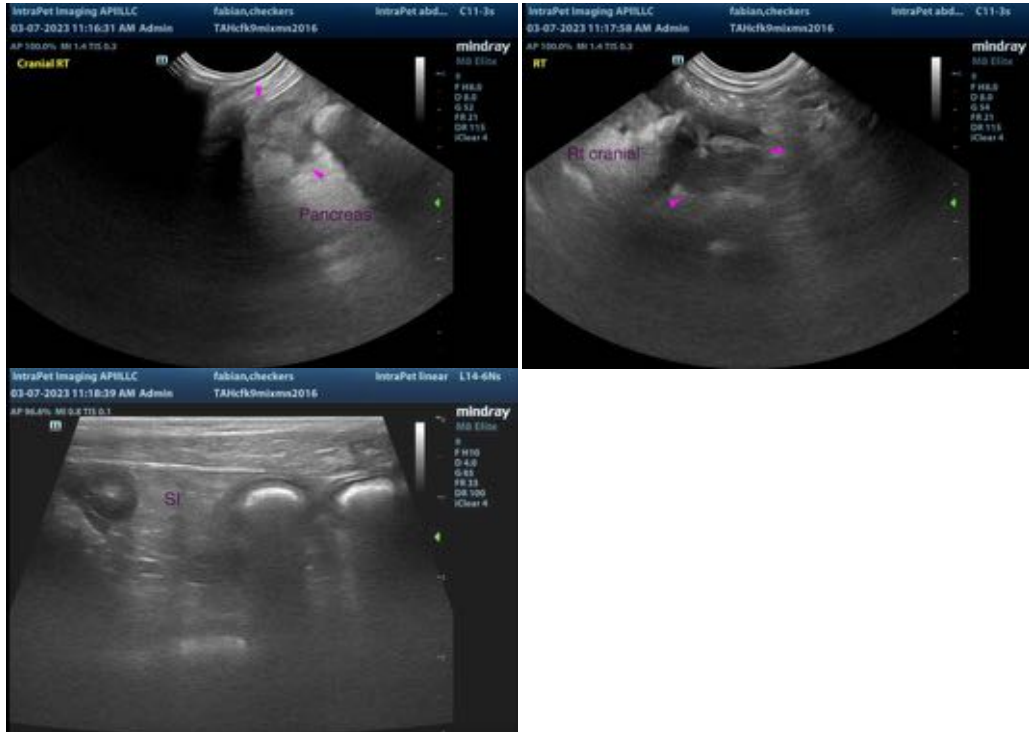
Secondary Findings:

- The splenic parenchymal changes are most consistent with a benign process such as lymphoid hyperplasia, extramedullary hematopoiesis, splenitis or antigenic stimulation with a low possibility of infiltrative neoplasia (i.e., lymphoma, mast cell neoplasia).
- The hypoechoic structure in the right cranial quadrant may represent an enlarged portal lymph node, a portion of the right limb of the pancreas, other.
- Urinary bladder sand.
- Minor bilateral, age-related renal changes.
- Gallbladder debris- non-mucocele.

INTERPRETATION OF THE FINDINGS & FURTHER RECOMMENDATIONS

- Supportive care for pancreatitis is recommended including IV fluid therapy, gastric protectants, antiemetics, pain medication as needed, +/- fresh frozen plasma. If available, hyperbaric oxygen therapy may be useful in reducing pancreatic inflammation. Trickle feeding is also recommended as soon as the patient will tolerate it. Also consider initiation of broad spectrum antibiotic therapy as empirical treatment for bacterial cholangiohepatitis.
- Serial monitoring of the patient's liver values is recommended, particularly the total bilirubin. If the bilirubin continues to increase, a repeat abdominal ultrasound +/- an abdominal exploratory may be warranted to evaluate bile duct patency, as pancreatitis can cause extraluminal compression of the common bile duct.
- Consider three-view thoracic radiographs to assess cardiopulmonary status, which can be affected by moderate to severe cases of pancreatitis.





The information and recommendations provided are based on the images presented by the referring veterinarian. No evaluation can be communicated regarding pathology that was not visible in the image/video clips provided.

Thank you for this referral. If the clinical or image interpretation does not parallel your findings or if I can be of any further assistance please contact me.

Andrea Nicastro, MPH, DVM, Diplomate DACVIM (Small Animal Internal Medicine)
info@SonoPath.com