



PATIENT

Summer Wilkinson

SPECIES

Canine

BREED

Golden Retriever

SEX

Spayed Female

AGE

09/08/2017

WEIGHT

60 lbs

INTERPRETED BY

Andrea Nicastro, DVM,
Diplomate ACVIM (*Small
Animal Internal Medicine*)

**IMAGING
PERFORMED BY**

Andrea Nicastro, DVM,
Diplomate ACVIM (*Small
Animal Internal Medicine*)

HOSPITAL NAME

Sun Dog Cat Moon

REFERRING VET

Kelsey Pruitt

INVOICE

12345

DATE

3.6.23

PRESENTING CLINICAL SIGNS

Clinical Exam Findings: Normal lab work on 3/4 at Paw Med
Lethargy (mild) per o, normal appetite, persistent diarrhea w/ increased frequency (no blood or mucus noted)
No pain or nausea elicited on abdominal palpation
waxing and waning diarrhea and lethargy with occasional vomiting
O certain p did not get into anything po.
Responds slightly to probiotic paste but reoccurs when o stops administering. P did not respond to bland diet.

Current Medications: Provable, GI Fast Balance and Rx Clay

ULTRASONOGRAPHIC EXAMINATION OF THE ABDOMEN

Urinary System

The urinary bladder wall is normal in thickness and the mucosal surface is smooth. The bladder lumen is moderately distended with anechoic urine. No masses, inflammatory changes or calculi are observed. Ureteral papillae and visualized portion of the proximal urethra, visible to a depth of 1-2 cm, are normal.

The left kidney is normal in size (6.97 cm in length) with a normal shape, architecture and smooth peripheral margins. There is a normal 1:3 cortex to medulla ratio with normal corticomedullary distinction. There is no evidence of pyelectasia, nephroliths, infarcts or hydroureter. Renal vasculature is normal.

The right kidney is normal in size (5.87 cm in length) with a slightly irregular shape. There is a normal 1:3 cortex to medulla ratio with minimal loss of corticomedullary distinction. A cortical infarct is suspected at the caudolateral aspect. There is no evidence of pyelectasia, nephroliths, or hydroureter. Renal vasculature is normal.

Adrenal Glands

The left adrenal gland is normal in size (0.68 cm at cranial pole) (0.62 cm at caudal pole) with a normal shape and homogenous parenchyma. The glandular echogenicity and detail are unremarkable. Capsule, cortex, and medullary definition are normal. The phrenicoabdominal vein and surrounding vasculature are normal.

The right adrenal gland is in normal size (1.05 cm at cranial pole) (0.53 cm at caudal pole) with a normal shape and homogenous parenchyma. The glandular echogenicity and detail are unremarkable. Capsule, cortex, and medullary definition are normal. The phrenicoabdominal vein and surrounding vasculature are normal.

Spleen

The spleen is normal in size (1.47 cm in width at the level of the hilus) with a normal capsular contour. There is appropriate echogenicity and echotexture. No focal lesions are observed. Splenic vasculature is normal.

Liver

The liver is subjectively normal in size with normal contours and structure. There is appropriate echogenicity and echotexture. No overt structural evidence of inflammatory, infiltrative, or regenerative pathology is evident. Vascular and biliary tracts are of normal volume with no evidence of congestion. No pathological hepatic lymphadenopathy observed. The portal vein to caudal vena cava ratio is approximately 1: 1.

The gall bladder is of normal contours and contains some dependent echogenic debris. The wall is normal

in thickness. No choleliths are observed. The cystic and common bile ducts are normal/not seen.

Gastrointestinal

The gastric lumen is mildly to moderately distended with ingesta (consistent with a post-prandial presentation). The gastric wall and pylorus are normal in thickness with a normal layering pattern. The pyloric outflow tract is patent. The small intestinal lumen is not dilated. The small intestinal wall thickness is normal with a normal layering pattern and appropriate mural detail. Discreet masses are not identified. The colonic wall is normal. The lumen of the descending colon contains watery, diarrheic stool. There is no obvious evidence of an obstructive pattern.

Pancreas

The region of the pancreas is isoechoic relative to surrounding omental fat. No obvious parenchymal abnormalities are observed. There is no evidence of regional inflammation or effusion.

Free Abdomen

The peritoneal cavity is normal. There is no evidence of inflammation or effusion. The abdominal lymph nodes are normal/not visible.

Other

A brief echocardiogram reveals no evidence of pericardial effusion or obvious right atrial/auricular mass.

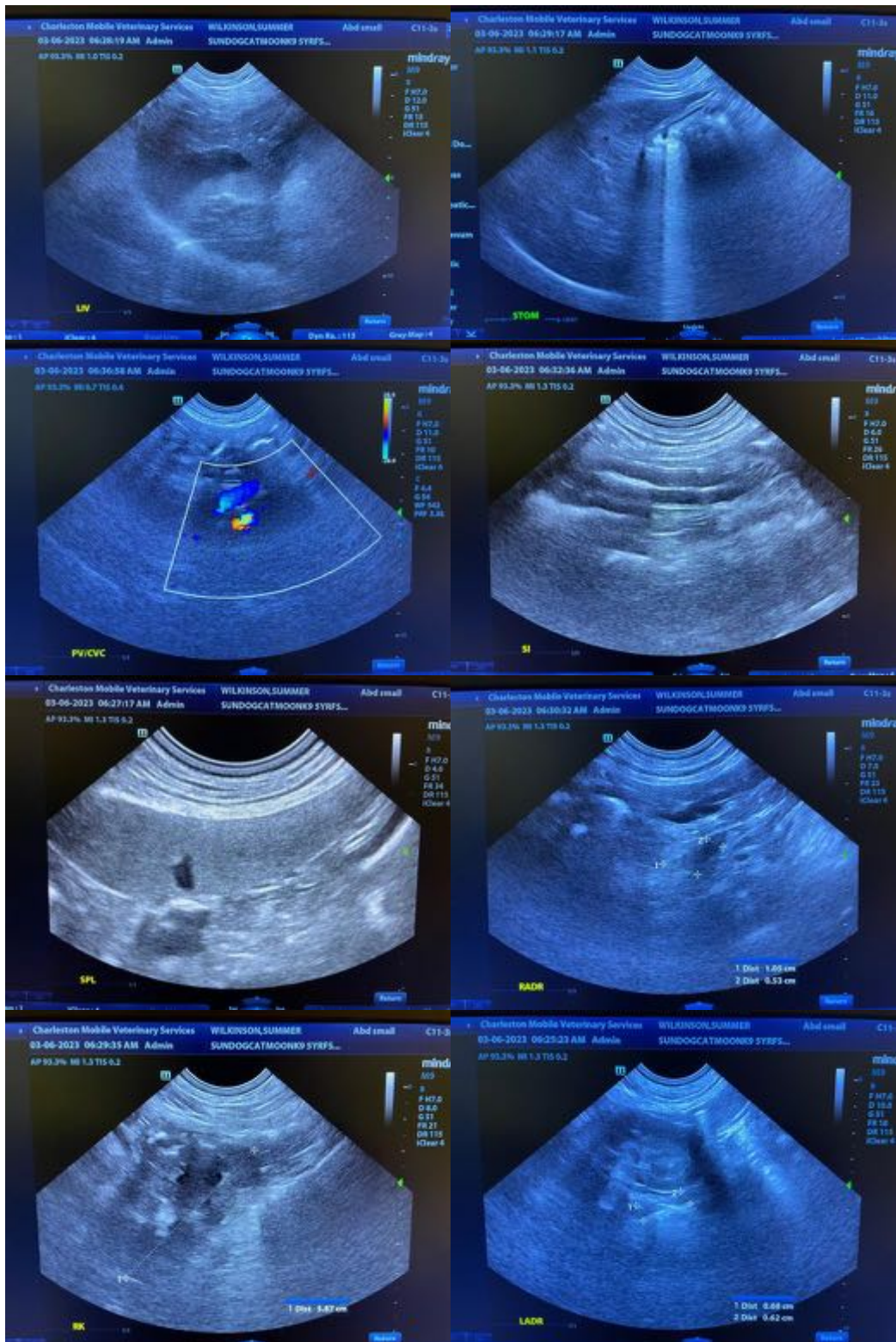
ULTRASONOGRAPHIC FINDINGS

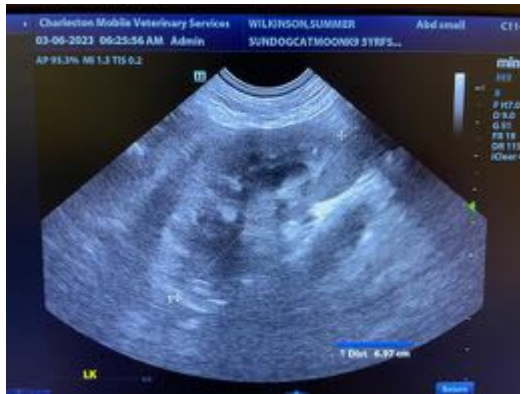Findings

- Suspected right renal infarct. The abdomen is otherwise unremarkable. An obvious cause for the patient's clinical signs is not definitively identified in this study. Considerations include primary gastrointestinal disease (i.e., food allergy, inflammatory bowel disease, infectious/parasitic disease), underlying metabolic issue, other.

INTERPRETATION OF THE FINDINGS & FURTHER RECOMMENDATIONS

- Fecal evaluation for ova and Giardia
- Fecal PCR infectious disease panel
- Consider prophylactic deworming with Fenbendazole.
- A GI panel including serum cobalamin and folate, TLI, PLI and resting cortisol is recommended (send to Texas A&M).
- Consider a 6-week limited antigen or hydrolyzed protein diet trial.
- Ultimately, endoscopic or surgical GI biopsies may be necessary to get a definitive diagnosis.
- In the meantime, initiation of probiotic +/- fiber supplement may prove beneficial.





The information and recommendations provided are based on the images presented by the referring veterinarian/sonographer. No evaluation can be communicated regarding pathology that was not visible in the image/video clips provided.

Thank you for this referral. If the clinical or image interpretation does not parallel your findings or if I can be of any further assistance, please contact me.

Andrea Nicastro, MPH, DVM, Diplomate DACVIM (Small Animal Internal Medicine)
info@SonoPath.com