

**DATE**

3-5-26

**PATIENT**

Dino Barski

**SPECIES**

Canine

**BREED**

Great Pyrenees Mix

**SEX**

Neutered Male

**AGE**

1/15/2021

**WEIGHT**

59.2 lbs

**INTERPRETED BY**

Andrea Nicastro DVM  
Diplomate ACVIM  
(Sm Animal Internal Med)

**HOSPITAL NAME**

Animal EH

**REFERRING VET**

Dr. Saubier

**INVOICE**

22658

**PRESENTING CLINICAL SIGNS**

**Patient History:** Recently diagnosed with atypical hypoadrenocorticism. - Hospitalized previously; improved after initiation of steroid therapy and gastric acid suppressant. - Ate while hospitalized; discharged home. - At home: marked lethargy, anorexia (medication and food left uneaten), significant weight loss, severe liquid diarrhea (described as "peeing out of his butt"), fecal incontinence, no observed hematochezia, intermittent vomiting (small amounts, described as "throwing up a little bit"), no normal activity or interaction. Previous concern for gastrointestinal foreign body; initial radiographs reportedly suggested obstruction, but subsequent findings unclear. - No confirmation of repeat radiographs; will review prior records. - No mention of urination other than fecal incontinence. - No coughing or sneezing reported.

**Current Medications:** Metronidazole, Ondansetron, Protonix, Vitamin B Complex.

**Labwork Results:** Labwork attached.

**Date of Previous IntraPet Ultrasound:** No previous.

**Sedation:** Not required to complete full diagnostic ultrasound.

**Stat Report:** Not requested.

**Imaging Performed by:** Rachel Brilhart, RDMS.

**ULTRASONOGRAPHIC EXAMINATION OF THE ABDOMEN**

**Urinary System**

The urinary bladder wall is normal in thickness. The mucosal surface is smooth. The bladder is moderately distended. Luminal contents are anechoic. No cystic calculi are observed. The region of the trigone and the proximal urethra, visible to a depth of 2 cm, are normal.

The prostate is normal in size (0.95 cm in width) and shape. Parenchyma is homogenous. The prostatic urethra appears normal without evidence of dilation or obstruction.

The left kidney is normal in size (7.24 cm in length) with a normal shape, architecture and smooth peripheral margins. There is a normal 1:3 cortex to medulla ratio with normal corticomedullary distinction. There is no evidence of pyelectasia, nephroliths, infarcts or hydroureter. Renal vasculature is normal.

The right kidney is normal in size (6.80 cm in length) with a normal shape, architecture and smooth peripheral margins. There is a normal 1:3 cortex to medulla ratio with normal corticomedullary distinction. There is no evidence of pyelectasia, nephroliths, infarcts or hydroureter. Renal vasculature is normal.

**Adrenal Glands**

The left adrenal gland is subjectively normal in length (0.24 cm at cranial pole) (0.24 cm at caudal pole) with a flattened contour. Glandular echogenicity and detail are normal. The phrenicoabdominal vein and surrounding vasculature are normal.

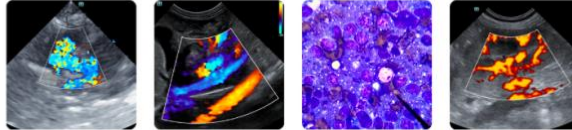
The right adrenal gland is normal in size (0.39 cm at cranial pole) (0.27 cm at caudal pole) with a normal shape and homogenous parenchyma. The glandular echogenicity and detail are unremarkable. Capsule, cortex, and medullary definition are normal. The phrenicoabdominal vein and surrounding vasculature are normal.

**Spleen**

The spleen is normal in size (1.30 cm in width at the level of the hilus) with a normal capsular contour. There is appropriate echogenicity and echotexture. No focal lesions are observed. Splenic vasculature is normal.

**Liver**

The liver is subjectively normal in size with normal contours and structure. There is appropriate



**DATE**

3-5-26

echogenicity and echotexture. No overt structural evidence of inflammatory, infiltrative, or regenerative pathology is evident. Vascular and biliary tracts are of normal volume with no evidence of congestion.

**PATIENT**

Dino Barski

The gallbladder lumen is moderately distended. The wall is thin and smooth. Luminal contents are anechoic. The cystic and common bile ducts are normal/not seen.

**SPECIES**

Canine

**Gastrointestinal**

The gastric lumen is not distended. The gastric wall and pylorus are normal in thickness with a normal layering pattern. The pyloric outflow tract is patent. The small intestinal lumen is not dilated. The small intestinal wall is normal in thickness with a normal layering pattern and appropriate mural detail. Discreet masses are not identified. The colonic wall is normal. There is no evidence of an obstructive pattern.

**BREED**

Great Pyrenees Mix

**Pancreas**

The right limb of the pancreas is visible with normal curvilinear peripheral contours. The parenchyma is slightly hyperechoic relative to surrounding omental fat and slightly mottled in appearance. The pancreatic duct is visible but not overtly dilated. There is no evidence of peripancreatic inflammation or effusion.

**SEX**

Neutered Male

**Lymph Nodes**

The abdominal lymph nodes are normal/not visible.

**AGE**

1/15/2021

**Free Abdomen**

The peritoneal cavity is normal. There is no evidence of inflammation or effusion.

**ULTRASONOGRAPHIC FINDINGS**

**WEIGHT**

59.2 lbs

- The pancreatic changes are most consistent with age-related parenchymal remodeling, potentially secondary to a prior inflammatory episode, early fibrosis or chronic pancreatitis.

**INTERPRETED BY**

Andrea Nicastro DVM  
Diplomate ACVIM  
(Sm Animal Internal Med)

- The bilaterally flattened adrenal glands are consistent with the previous diagnostic of atypical hypoadrenocorticism.

\*An obvious cause for the patient's clinical signs is not definitively identified in this study. Considerations include a microscopic enteropathy (i.e., food allergy/intolerance, inflammatory bowel disease, infectious/parasitic disease), underlying metabolic issue, other.

**HOSPITAL NAME**

Animal EH

**INTERPRETATION OF THE FINDINGS & FURTHER RECOMMENDATIONS**

The following diagnostics/treatment recommendations can be considered:

**REFERRING VET**

Dr. Saubier

1. Texas GI panel including serum cobalamin, folate, PLI, and TLI
2. A fecal evaluation for ova/Giardia
3. Prophylactic deworming with Fenbendazole.
4. A 3-4-week hypoallergenic or hydrolyzed protein diet trial
5. Also consider initiating a probiotic with a high colony count +/- fiber supplement (i.e., psyllium).
6. Depending on the results of the above diagnostics/therapeutics, endoscopic or surgical gastrointestinal biopsies may be warranted.
7. Three-view thoracic radiographs should be performed prior to any anesthetic event.

**INVOICE**

22658

Imaging performed by



Clinical Sonography & Telectylogy  
Educational Teleconsultation Services™

SonoPath

FOSTERING THE ART OF VETERINARY MEDICINE™

SonoPath.com info@sonopath.com 1.800.838.4268

**DATE**

3-5-26

**PATIENT**

Dino Barski

**SPECIES**

Canine

**BREED**

Great Pyrenees Mix

**SEX**

Neutered Male

**AGE**

1/15/2021

**WEIGHT**

59.2 lbs

**INTERPRETED BY**

Andrea Nicastro DVM  
Diplomate ACVIM  
(Sm Animal Internal Med)

**HOSPITAL NAME**

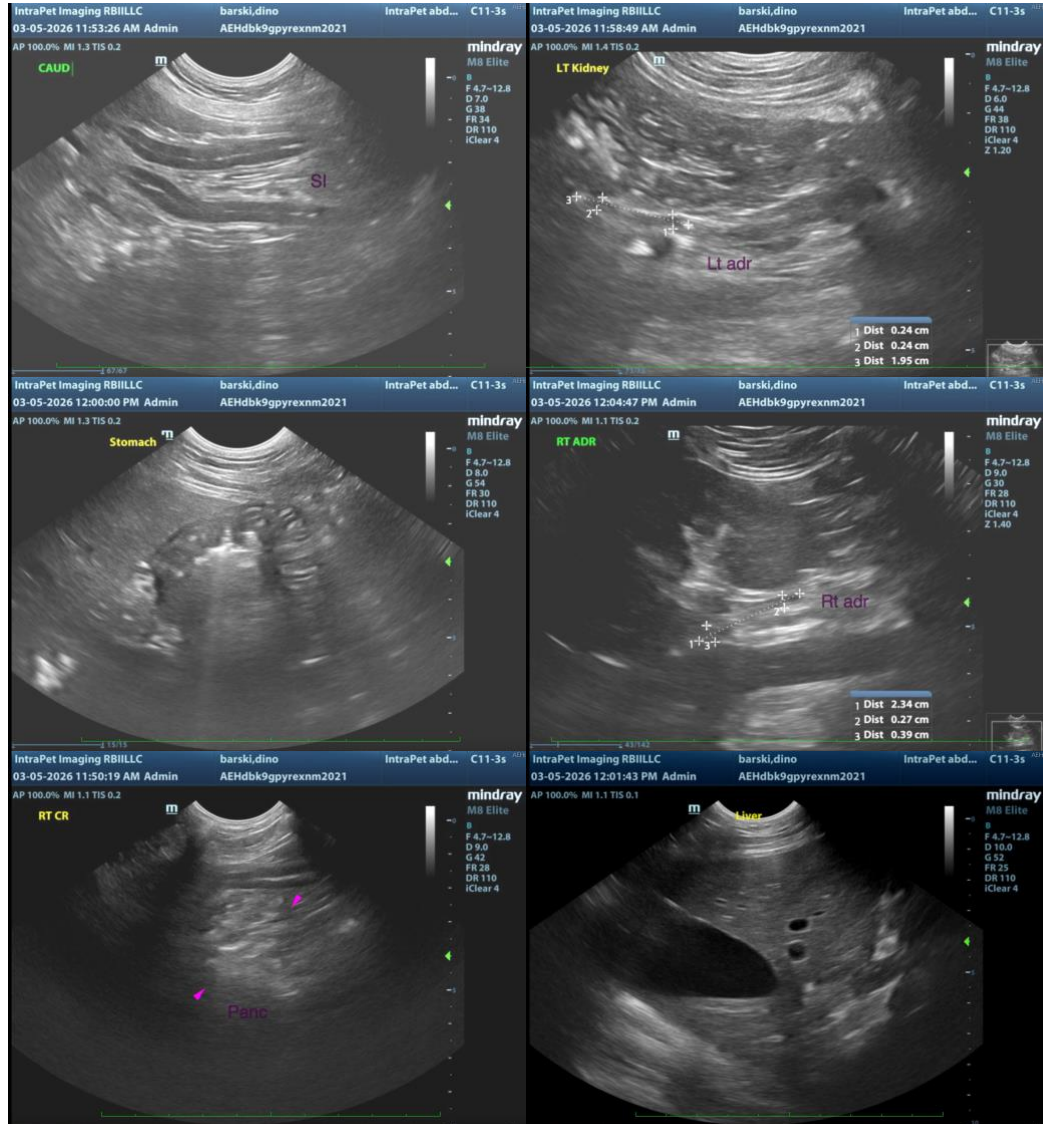
Animal EH

**REFERRING VET**

Dr. Saubier

**INVOICE**

22658



The information and recommendations provided are based on the images presented by the referring veterinarian/sonographer. No evaluation can be communicated regarding pathology that was not visible in the image/video clips provided.

Thank you for this referral. If the clinical or image interpretation does not parallel your findings or if I can be of any further assistance, please contact me.

**Andrea Nicastro, MPH, DVM, Diplomate DACVIM (Small Animal Internal Medicine)**  
[info@SonoPath.com](mailto:info@SonoPath.com)