

**DATE PRESENTING CLINICAL SIGNS**

3/4/2022 History: 2/22/22- presented for constipation and weight loss. O has not seen a bowel movement in 3 days. PE: oral exam- numerous missing teeth; grade 2 dental disease, soft stool present in colon, fecal material matted over rectum.

PATIENT

Max Rothman Current Medications: None.

Lab Results: 2/22- Moderate Leukocytosis 27.5K, Mild neutrophilia 19.5K, Mild monocytosis 0.55K, Moderate eosinophilia 4.6K, Moderate basophilia 0.275K. Mild hyperproteinemia 8.9K, T4 1.6.

SPECIES

Feline

Radiographs: 2/22- stomach empty. Small intestines appear enlarged with ingesta. Diffuse radiopaque material throughout ascending, transverse and descending colon. Mid-abdominal mass effect measuring 4.4cm. Brief ultrasound: cavitated mid abdominal mass.

Date of Previous IntraPet Ultrasound: No previous.

BREED

DSH

Sedation: Not required to complete full diagnostic ultrasound.
Stat Report: Not requested.

SEX

Neutered Male

Imaging Performed By: Andi Parkinson, RDMS.

ULTRASONOGRAPHIC EXAMINATION OF THE ABDOMEN**AGE**

2/22/2006

Urinary System

The urinary bladder, trigone, and pelvic urethra are normal in thickness and the mucosal surface is smooth. The bladder is moderately distended. A small amount of suspended echogenic debris is observed within the lumen. No masses, inflammatory changes or calculi are observed. Ureteral papillae and visualized portion of the proximal urethra, visible to a depth of 2 cm, are normal.

WEIGHT

7.4 lbs

The left kidney is normal size (4.29 cm in length); normal shape and architecture with smooth peripheral margins. There is a normal 1:3 cortex to medulla ratio with minimal to mild loss of corticomedullary distinction. There is no evidence of pyelectasia, nephroliths, infarcts or hydroureter.

INTERPRETED BY

Andrea Nicastro,
DMV, Diplomate
DACVIM (Small
Animal
Internal Medicine)

The right kidney is normal size (4.38 cm in length); normal shape and architecture with smooth peripheral margins. There is a normal 1:3 cortex to medulla ratio with minimal to mild loss of corticomedullary distinction. There is no evidence of pyelectasia, nephroliths, infarcts or hydroureter.

HOSPITAL NAME

Timonium AH

Adrenal Glands

The region of the adrenal glands is evaluated. No obvious pathology is observed.

REFERRING VET

Dr. Falkowski

Spleen

The spleen is normal in size (0.95 cm in width at the level of the hilus) with a normal capsular contour. There is appropriate echogenicity and echotexture. No focal lesions are observed. Splenic vasculature is normal.

INVOICE

10500

Liver

The liver is subjectively normal in size with normal contours and structure. There is appropriate echogenicity and echotexture. No overt structural evidence of inflammatory, infiltrative, or regenerative pathology is evident. Vascular and biliary tracts are of normal volume with no evidence of congestion. No pathological hepatic lymphadenopathy observed.

The gall bladder lumen is moderately distended. The wall is thin and smooth. A small amount of aggregated echogenic suspended debris is observed within the lumen. The cystic and common bile ducts are normal.

Gastrointestinal

The gastric lumen is mildly distended with ingesta. The gastric wall is normal in thickness with a normal layering pattern. A >3 cm irregular, hypoechoic mass is observed at within the small intestines. The mesentery effacing the serosal surface of the mass is hyperechoic. The wall in this region is severely thickened (up to 1.41 cm), with a complete loss of the normal layering pattern. The small intestinal lumen proximal to the mass is dilated with chyme. Distal to the mass, the lumen appears mostly empty. The remaining small intestinal walls are thickened (up to 0.50 cm), with disruption in the normal 1:3 muscularis: mucosal ratio. In some regions, there is concern for loss of the normal layering pattern. The colonic wall is normal.

Pancreas

A portion of the pancreas is obscured by the small intestinal mass. In the visualized portions, no obvious abnormalities are seen.

Free Abdomen

Trace free fluid is observed. The mesenteric lymph nodes are severely enlarged (> 6cm), with a mass effect. The nodes are irregular and heterogenous in appearance. Surrounding mesentery is mildly hyperechoic. One to two enlarged, rounded, hypoechoic lymph nodes are also observed in the cranial abdomen.

ULTRASONOGRAPHIC FINDINGS

Primary Findings

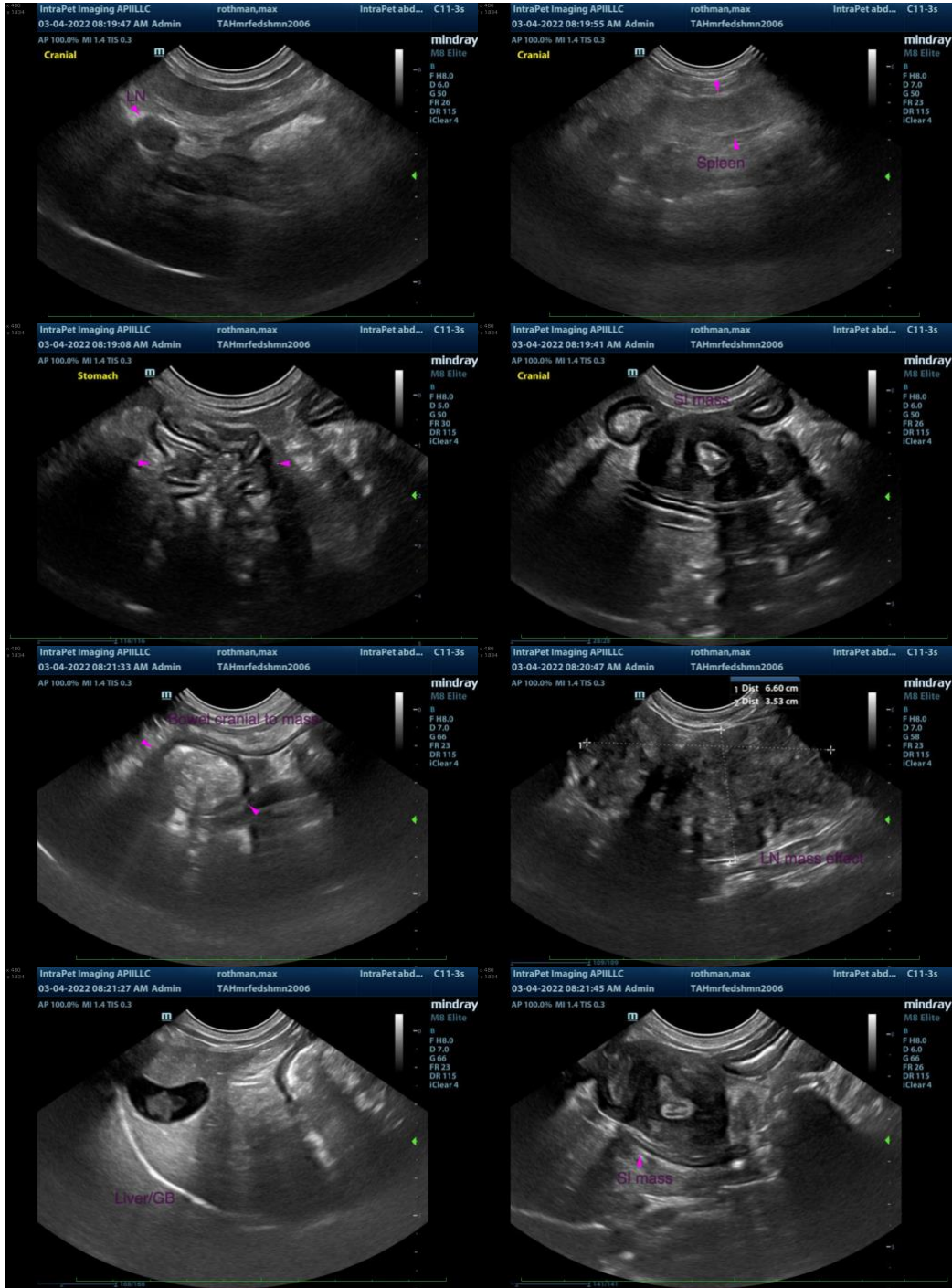
- Small intestinal mass effect with partial luminal obstruction. Neoplasia (i.e., adenocarcinoma, lymphoma), is suspected. However, a severe inflammatory (i.e., eosinophilic enteritis or pyogranulomatous inflammation), cannot be exclude. Regional peritonitis is present.
- The diffuse small intestinal changes are also concerning for infiltrative neoplasia. However, an inflammatory process (i.e., eosinophilic or lymphoplasmacytic enteritis), is also possible.
- Mass effect involving the mesenteric root lymph nodes. Again, neoplasia is suspected. However, a severe lymphadenitis is also possible, particularly in light of the peripheral eosinophilia.

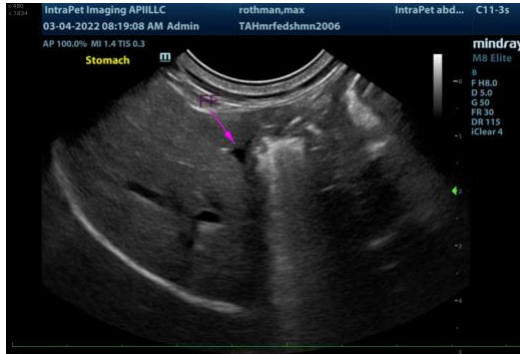Secondary Findings

- Minor nonspecific age-related renal changes

INTERPRETATION OF THE FINDINGS & FURTHER RECOMMENDATIONS

Chest X-rays (three-view), are recommended to evaluate for pulmonary metastatic disease. Fine-needle aspirates of the small intestinal mass and mesenteric lymph nodes are recommended, if clotting status is appropriate. If cytology results are nondiagnostic, surgical biopsies may be necessary to get a definitive diagnosis. A GI Panel (send to Texas A&M), is also recommended.





The information and recommendations provided are based on the images presented by the referring veterinarian/sonographer. No evaluation can be communicated regarding pathology that was not visible in the image/video clips provided.

Thank you for this referral. If the clinical or image interpretation does not parallel your findings or if I can be of any further assistance, please contact me.

Andrea Nicastro, DVM, Diplomate DACVIM (Small Animal Internal Medicine)
info@SonoPath.com