



PATIENT

Teddy Ramirez

SPECIES

Canine

BREED

Mini Poodle

SEX

Neutered Male

AGE

9 years

WEIGHT

6.9 lbs

INTERPRETED BY

Andrea Nicastro,
DVM, Diplomate ACVIM
(Small Animal Internal
Medicine)

**IMAGING
PERFORMED BY**

Dr. Andrew Holmes

HOSPITAL NAME

Cedarview AH

REFERRING VET

Dr. Andrew Holmes

INVOICE

10643

DATE

3/31/22

PRESENTING CLINICAL SIGNS

History: An episode of 24h of vomiting, - historically drinks a lot of water, normal urination - history of mildly elevated ALP that has recently spiked - typically around 500-700U/L increase dramatically to 2000+, hepatic support for 3 weeks and re-tested liver enzymes remained still elevated
Abnormal PE/Chem/CBC/UA Results: ALT 512 [18 - 121 U/L] ALP 2,423 [5 - 160 U/L] GGT 56 [0 - 13 U/L] Lipase 798 [0 - 250 U/L] Chloride 103 [108 - 119 mmol/L]

ULTRASONOGRAPHIC EXAMINATION OF THE ABDOMEN

Urinary System

The urinary bladder, trigone, and pelvic urethra are normal in thickness and the mucosal surface is smooth. The bladder lumen is moderately distended with anechoic urine. No masses, inflammatory changes or calculi are observed. Ureteral papillae and visualized portion of the proximal urethra, visible to a depth of 2 cm, are normal.

The prostate is normal in size (0.73 cm in width) and shape. Parenchyma is homogenous. The prostatic urethra appears normal without evidence of dilation or obstruction.

The left kidney is normal size (4.43 cm in length); normal shape and architecture with smooth peripheral margins. There is a normal 1:3 cortex to medulla ratio with minimal loss of corticomedullary distinction. An ill-defined hyperechoic medullary band is observed adjacent to the corticomedullary junction. There is no evidence of pyelectasia, nephroliths, infarcts or hydroureter.

The right kidney is normal size (4.93 cm in length); normal shape and architecture with smooth peripheral margins. There is a normal 1:3 cortex to medulla ratio with minimal loss of corticomedullary distinction. An ill-defined hyperechoic medullary band is observed adjacent to the corticomedullary junction. There is no evidence of pyelectasia, nephroliths, infarcts or hydroureter.

Adrenal Glands

The left adrenal gland is mildly enlarged (0.68 cm at cranial pole) (0.73 cm at caudal pole) (2.27 cm in length); normal shape; homogenous parenchyma. The glandular echogenicity and detail are unremarkable. Capsule, cortex, and medullary definition are normal. The phrenicoabdominal vein and surrounding vasculature are normal.

The right adrenal gland is borderline enlarged (0.93 cm at cranial pole) (0.53 cm at caudal pole) (1.66 cm in length); with a normal shape. A 0.90 x 0.51 cm irregular, hyperechoic nodule is observed at the cranial- to midaspect. The remaining glandular echogenicity and detail are normal. The phrenicoabdominal vein and surrounding vasculature appear normal.

Spleen

The spleen is subjectively normal to slightly prominent in size (1.75 cm in width at the level of the hilus) with normal curvilinear peripheral contours. The parenchyma is subtly mottled in appearance. A 0.84 cm hypoechoic nodule/area is observed near the lateral aspect. Splenic vasculature is normal with no evidence of thrombosis.

Liver

The liver is subjectively enlarged with slightly swollen peripheral contours. The parenchyma is hyperechoic relative to the spleen and diffusely homogeneous in appearance. No distinct focal lesions are observed. Vascular and biliary tracts are of normal volume with no evidence of congestion. The



PATIENT

Teddy Ramirez

gall bladder lumen is moderately distended. The wall is thin and smooth. A small amount of aggregated echogenic partially dependent debris is observed within the lumen. The cystic and common bile ducts are normal/not seen.

SPECIES

Canine

The gall bladder lumen is moderately distended. The wall is thin and smooth. A small amount of mostly gravity dependent, echogenic debris is observed within the lumen. The cystic and common bile ducts are normal.

Gastrointestinal

BREED

Mini Poodle

The stomach and intestine are free of stasis and exhibit normal peristaltic activity. The gastric lumen is not distended. The gastric wall and pylorus are normal in thickness with a normal layering pattern. The small intestinal lumen is not dilated. The small intestinal wall thickness is normal with a normal layering pattern and appropriate mural detail. Discreet masses are not identified. The colonic wall is normal. No obstructive or overt infiltrative disease is noted.

SEX

Neutered Male

Pancreas

The right limb of the pancreas is visible with normal curvilinear peripheral contours. The parenchyma is largely isoechoic relative to surrounding omental fat and slightly mottled in appearance. The pancreatic duct is visible but not overtly dilated. There is no evidence of peripancreatic inflammation or effusion.

AGE

9 years

Free Abdomen

The peritoneal cavity is normal. There is no evidence of inflammation or effusion. The abdominal lymph nodes are normal/not visible.

WEIGHT

6.9 lbs

INTERPRETED BY

Andrea Nicastro,
DVM, Diplomate ACVIM
(Small Animal Internal
Medicine)

ULTRASONOGRAPHIC FINDINGS

Primary Findings

- Nonspecific diffuse hepatopathy. Differentials include vacuolar hepatopathy, regenerative nodular hyperplasia, inflammatory disease, hepatotoxicosis (i.e., copper), infiltrative neoplasia (i.e., lymphoma), other.
- Gall bladder debris – incidental
- The bilateral adrenal changes are most consistent with hyperplasia, with a lower possibility of emerging neoplasia in the right adrenal gland.
-

IMAGING PERFORMED BY

Dr. Andrew Holmes

Secondary Findings

- Minor age-related chronic renal changes
- The pancreatic changes are most consistent with age-related parenchymal remodeling, potentially secondary to a prior inflammatory episode, early fibrosis or chronic pancreatitis.

HOSPITAL NAME

Cedarview AH

REFERRING VET

Dr. Andrew Holmes

**It is unclear whether the elevated liver enzymes are secondary to a primary hepatopathy, age-related change, or Cushing's disease. However, the recent vomiting is unlikely to be related to hyperadrenocorticism.

INVOICE

10643

DATE

3/31/22



PATIENT

Teddy Ramirez

SPECIES

Canine

BREED

Mini Poodle

SEX

Neutered Male

AGE

9 years

WEIGHT

6.9 lbs

INTERPRETED BY

Andrea Nicastro,
DVM, Diplomate ACVIM
(Small Animal Internal
Medicine)

IMAGING PERFORMED BY

Dr. Andrew Holmes

HOSPITAL NAME

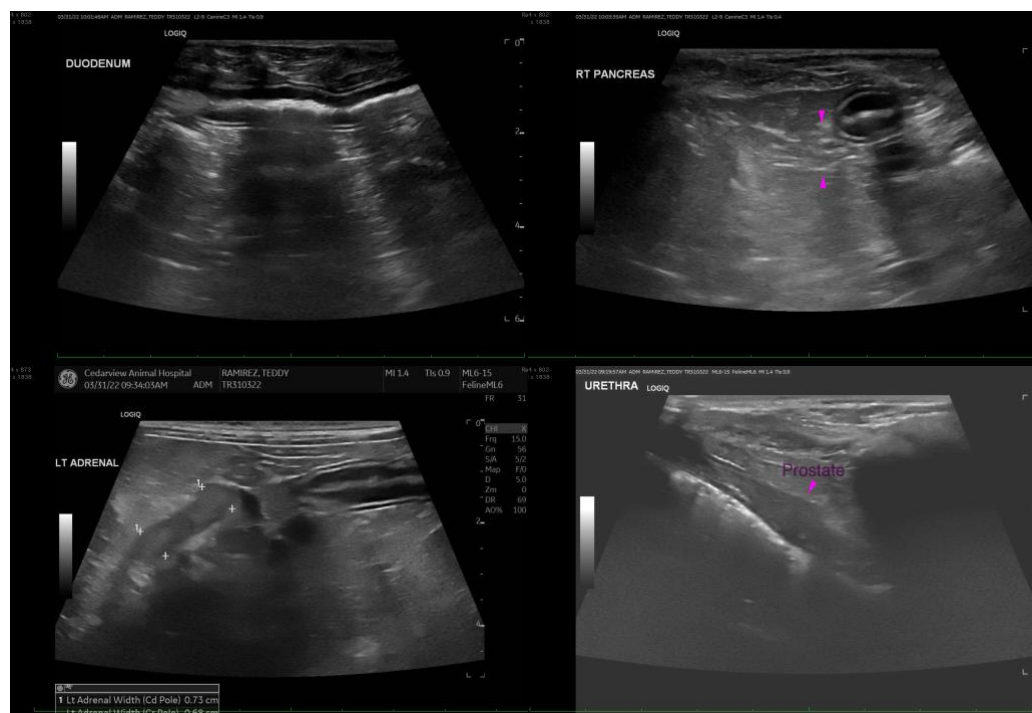
Cedarview AH

REFERRING VET

Dr. Andrew Holmes

INTERPRETATION OF THE FINDINGS & FURTHER RECOMMENDATIONS

- Pre-and postprandial serum bile acids are recommended to assess hepatic function. Consider hepatic tissue sampling (i.e., fine-needle aspirate or surgical biopsy), particularly if the bile acids are substantially elevated. If biopsies are pursued, aerobic and anaerobic bile cultures are also recommended as well as acquisition of additional hepatic tissue samples for potential copper quantitation.
- Also consider Leptospirosis testing (i.e., blood and urine PCR, serology), especially if the clinical index of suspicion is high.
- While awaiting test results, consider empirical treatment for gastroenteritis/cholangiohepatitis (i.e., fluid therapy, gastric protectants, antiemetics and broad-spectrum antibiotic therapy).
- Also consider a GI panel (i.e., serum cobalamin, folate, TLI and PLI) to further assess for gastrointestinal and pancreatic disease.
- Given the patient's age, three-view thoracic radiographs are recommended to assess cardiopulmonary status.
- When the patient's gastrointestinal signs have resolved, consider further testing for Cushing's Disease (i.e., low-dose dexamethasone suppression test or ACTH stimulation test).



INVOICE

10643

DATE

3/31/22



PATIENT

Teddy Ramirez

SPECIES

Canine

BREED

Mini Poodle

SEX

Neutered Male

AGE

9 years

WEIGHT

6.9 lbs

INTERPRETED BY

Andrea Nicastro,
DVM, Diplomate ACVIM
(Small Animal Internal
Medicine)

**IMAGING
PERFORMED BY**

Dr. Andrew Holmes

HOSPITAL NAME

Cedarview AH

REFERRING VET

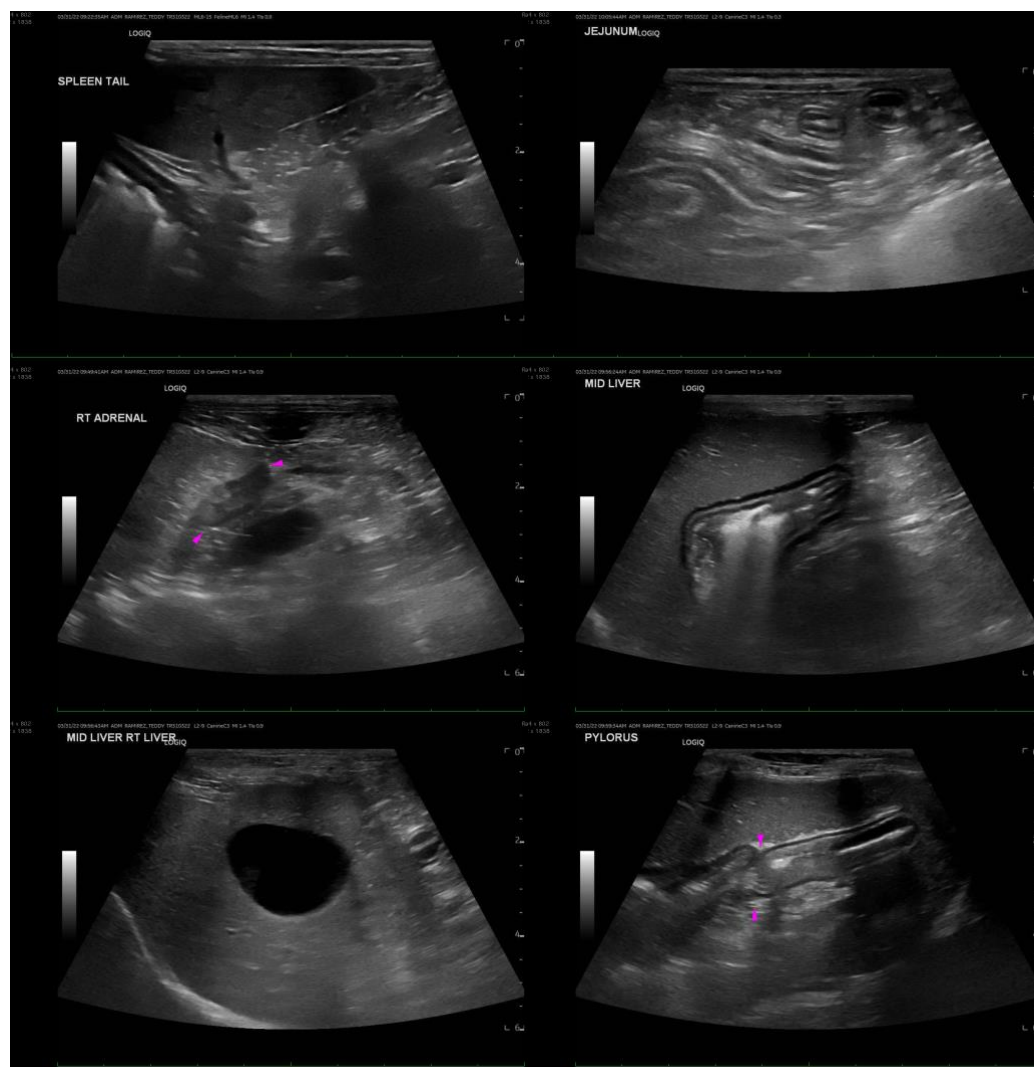
Dr. Andrew Holmes

INVOICE

10643

DATE

3/31/22



The information and recommendations provided are based on the images presented by the referring veterinarian/sonographer. No evaluation can be communicated regarding pathology that was not visible in the image/video clips provided.

Thank you for this referral. If the clinical or image interpretation does not parallel your findings or if I can be of any further assistance, please contact me.

Andrea Nicastro, DVM, Diplomate DACVIM (Small Animal Internal Medicine)
info@SonoPath.com