

PATIENT

Cairo Woodcock

SPECIES

Canine

BREED

Labradoodle

SEX

Neutered Male

AGE

8

WEIGHT

83 lbs

INTERPRETED BY

Andrea Nicastrò DVM
Diplomate ACVIM
(Sm Animal Internal Med)

**IMAGING
PERFORMED BY**

Andrea Nicastrò DVM
Diplomate ACVIM
(Sm Animal Internal Med)

HOSPITAL NAME

Sun Dog Cat Moon

REFERRING VET

Dr. Clayton

INVOICE

22766

DATE

3-30-26

PRESENTING CLINICAL SIGNS

Patient was worked up for a single seizure in the fall. No significant findings at that time. Had an MRI with a neurologist. Was put on phenobarbital and has been on it ever since. Recently, liver enzymes have been increasing. Most recent ALT 727. Most recent ALP 331. Both enzymes are increased from January. Previous phenobarbital level was low normal. Has not had any more seizures since starting phenobarbital. Otherwise, asymptomatic. Patient is having a pre- and postprandial serum bile acids and phenobarbital level performed today.

ULTRASONOGRAPHIC EXAMINATION OF THE ABDOMEN

Urinary System

The urinary bladder wall is normal in thickness. The mucosal surface is smooth. The bladder is moderately distended. Luminal contents are anechoic. No cystic calculi are observed. The region of the trigone and the proximal urethra, visible to a depth of 2 cm, are normal.

The prostate is normal in size (0.95 cm in width) and shape. Parenchyma is homogenous. The prostatic urethra appears normal without evidence of dilation or obstruction.

The left kidney is normal in size (7.29 cm in length) with a normal shape, architecture and smooth peripheral margins. There is a normal 1:3 cortex to medulla ratio with minimal loss of corticomedullary distinction. There is no evidence of pyelectasia, nephroliths, infarcts or hydroureter. Renal vasculature is normal.

The right kidney is normal in size (6.49 cm in length) with a normal shape, architecture and smooth peripheral margins. There is a normal 1:3 cortex to medulla ratio with minimal loss of corticomedullary distinction. There is no evidence of pyelectasia, nephroliths, infarcts or hydroureter. Renal vasculature is normal.

Adrenal Glands

The left adrenal gland is normal in size (0.59 cm at cranial pole) (0.53 cm at caudal pole) with a normal shape and homogenous parenchyma. The glandular echogenicity and detail are unremarkable. Capsule, cortex, and medullary definition are normal. The phrenicoabdominal vein and surrounding vasculature are normal.

The right adrenal gland is normal in size (0.94 cm at cranial pole) (0.54 cm at caudal pole) with a normal shape and homogenous parenchyma. The glandular echogenicity and detail are unremarkable. Capsule, cortex, and medullary definition are normal. The phrenicoabdominal vein and surrounding vasculature are normal.

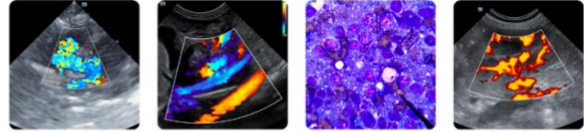
Spleen

The spleen is subjectively normal-in-size, with a normal capsular contour. There is appropriate echogenicity and echotexture. No focal lesions are observed. Splenic vasculature is normal.

Liver

The liver is subjectively normal in size with normal contours and structure. There is appropriate echogenicity and echotexture. No overt structural evidence of inflammatory, infiltrative, or regenerative pathology is evident. Vascular and biliary tracts are of normal volume with no evidence of congestion. The portal vein to caudal vena cava ratio is approximately 1: 1.

The gallbladder is of normal contours and contains some dependent echogenic debris. The wall is normal in thickness. No choleliths are observed. The cystic and common bile ducts are normal/not seen.



PATIENT

Cairo Woodcock

SPECIES

Canine

BREED

Labradoodle

SEX

Neutered Male

AGE

8

WEIGHT

83 lbs

INTERPRETED BY

Andrea Nicastrò DVM
Diplomate ACVIM
(Sm Animal Internal Med)

**IMAGING
PERFORMED BY**

Andrea Nicastrò DVM
Diplomate ACVIM
(Sm Animal Internal Med)

HOSPITAL NAME

Sun Dog Cat Moon

REFERRING VET

Dr. Clayton

INVOICE

22766

DATE

3-30-26

Gastrointestinal

The gastric lumen is not distended. The gastric wall and pylorus are normal in thickness with a normal layering pattern. The pyloric outflow tract is patent. The small intestinal lumen is not dilated. The small intestinal wall is normal in thickness with a normal layering pattern and appropriate mural detail. Discreet masses are not identified. The ileoceocolic junction and colonic wall are normal. There is no evidence of an obstructive pattern.

Pancreas

The region of the pancreas is isoechoic relative to surrounding omental fat. No obvious parenchymal abnormalities are observed. There is no evidence of regional inflammation or effusion.

Lymph Nodes

The abdominal lymph nodes are normal/not visible.

Free Abdomen

The peritoneal cavity is normal. There is no evidence of inflammation or effusion.

Other

A brief echocardiogram reveals no evidence of pericardial effusion or obvious right atrial/auricular mass.

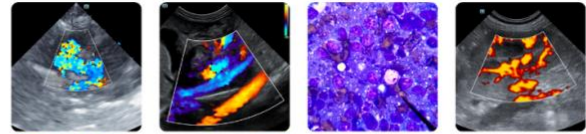
ULTRASONOGRAPHIC FINDINGS

Structurally unremarkable abdomen.

*An obvious cause for the elevated liver enzymes is not identified in the study. However, a microscopic hepatopathy (i.e., bacterial cholangiohepatitis, Leptospirosis, chronic active hepatitis, hepatotoxicity (copper, phenobarbital), infiltrative neoplasia (less likely)) is suspected.

INTERPRETATION OF THE FINDINGS & FURTHER RECOMMENDATIONS

- Hepatic tissue sampling (i.e., aspirates or biopsies) may be necessary to get a definitive diagnosis. If biopsies are pursued, aerobic and anaerobic bile cultures and hepatic copper quantitation should also be performed.
- If a conservative approach is desired, consider empirical treatment for bacterial cholangiohepatitis (amoxicillin-clavulanic acid, Denamarin). If no improvement in the liver values is seen within 7-10 days of initiating therapy, antibiotics should be discontinued, and hepatic tissue sampling reconsidered. If liver values improve, continue therapy for at least 4-6 weeks and 1 week beyond normalization of the liver values.
- Leptospirosis testing (i.e., blood and urine PCR, serology) can be considered. However, given the asymptomatic state of the patient, and the chronicity of the liver enzyme elevations, this test may be of low yield.



PATIENT

Cairo Woodcock

SPECIES

Canine

BREED

Labradoodle

SEX

Neutered Male

AGE

8

WEIGHT

83 lbs

INTERPRETED BY

Andrea Nicastrò DVM
 Diplomate ACVIM
 (Sm Animal Internal Med)

IMAGING PERFORMED BY

Andrea Nicastrò DVM
 Diplomate ACVIM
 (Sm Animal Internal Med)

HOSPITAL NAME

Sun Dog Cat Moon

REFERRING VET

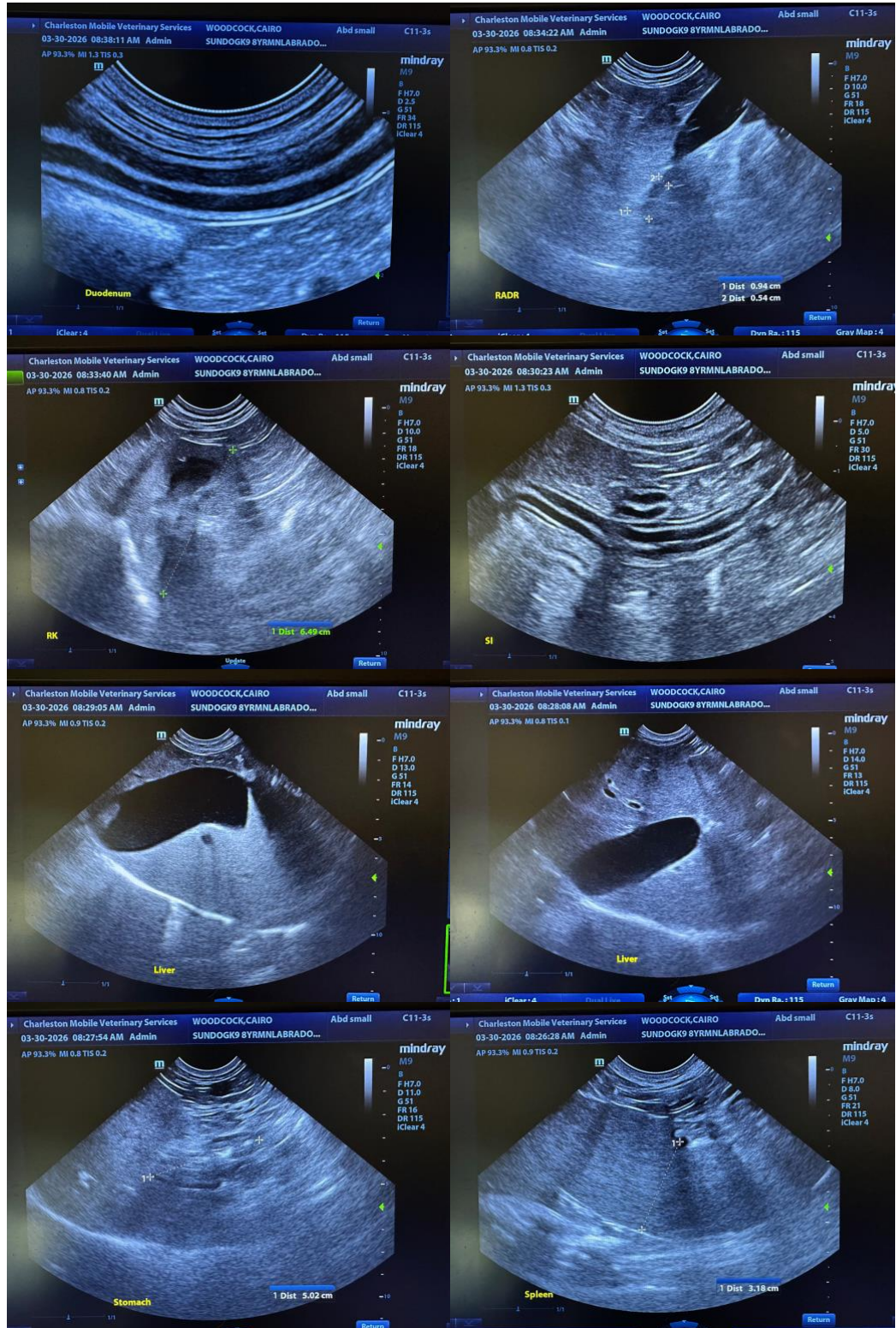
Dr. Clayton

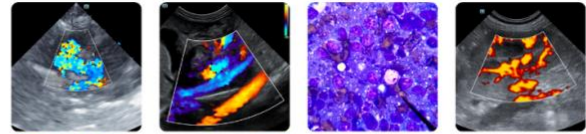
INVOICE

22766

DATE

3-30-26





PATIENT

Cairo Woodcock

SPECIES

Canine

BREED

Labradoodle

SEX

Neutered Male

AGE

8

WEIGHT

83 lbs

INTERPRETED BY

Andrea Nicastrò DVM
 Diplomate ACVIM
 (Sm Animal Internal Med)

IMAGING PERFORMED BY

Andrea Nicastrò DVM
 Diplomate ACVIM
 (Sm Animal Internal Med)

HOSPITAL NAME

Sun Dog Cat Moon

REFERRING VET

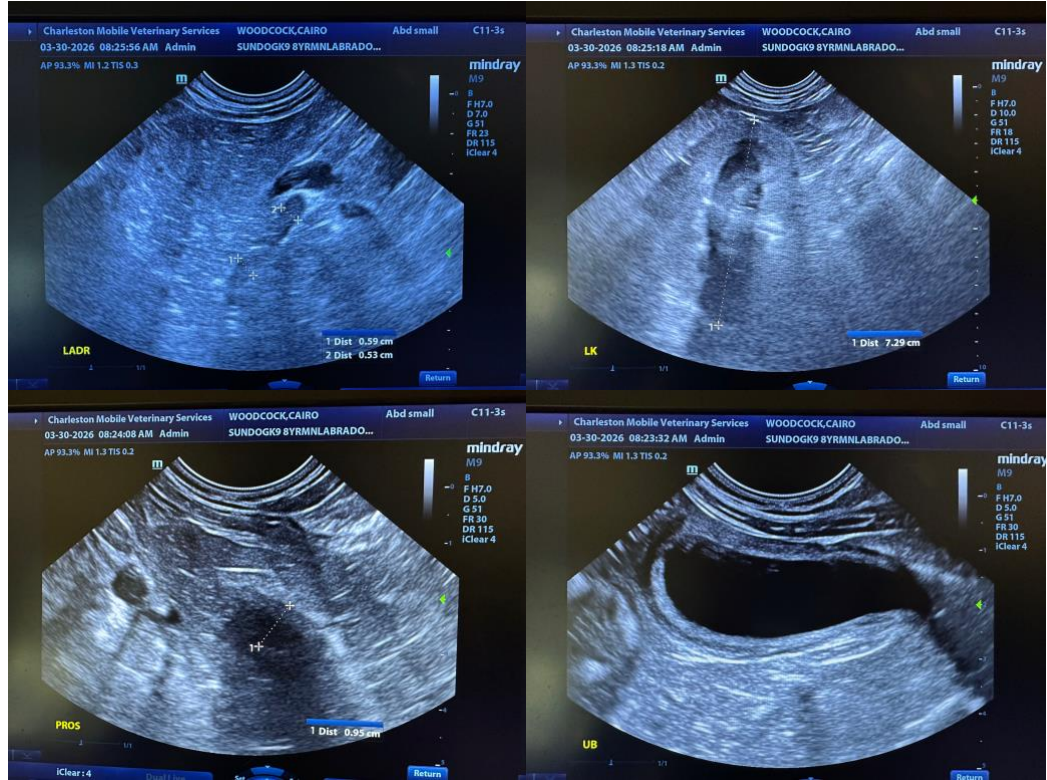
Dr. Clayton

INVOICE

22766

DATE

3-30-26



The information and recommendations provided are based on the images presented by the referring veterinarian/sonographer. No evaluation can be communicated regarding pathology that was not visible in the image/video clips provided.

Thank you for this referral. If the clinical or image interpretation does not parallel your findings or if I can be of any further assistance, please contact me.

Andrea Nicastrò, MPH, DVM, Diplomate DACVIM (Small Animal Internal Medicine)
info@SonoPath.com