SonoPath
Clinical Sonography & Telecytology
EDUCATIONAL TELECONSULTATION SERVICES™

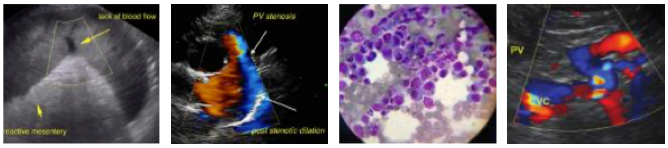

SonoPath.com
1-800-838-4268 info@sonopath.com

PATIENT
Carbon Ayala

SPECIES
Canine

BREED
Pitbull Terrier

SEX
Neutered Male

AGE
9 years

WEIGHT
37 lbs

INTERPRETED BY
Andrea Nicastro, DVM, Diplomate ACVIM (Small Animal Internal Medicine)

IMAGING PERFORMED BY
Dr. Ferrer DVM

HOSPITAL NAME
Paseos VC

REFERRING VET
Dr. Jose Cruz

INVOICE
12579

DATE
3.30.23

PRESENTING CLINICAL SIGNS

History: Patient came as a referral for an abdominal ultrasound to evaluate the Gastrointestinal tract. Pt has a hx of chronic vomiting.

ULTRASONOGRAPHIC EXAMINATION OF THE ABDOMEN

Urinary System

The urinary bladder is moderately distended. A 2.50-3.00 cm irregular mass is observed along the ventral wall at the level of the cystourethral junction. The remaining urinary bladder wall is normal in thickness with a smooth mucosal surface. No cystic calculi are observed. The proximal urethra, visible to a depth of 2-3 cm, appears normal.

The prostate is normal in size (1.15 cm in width) and shape. Parenchyma is homogenous. The prostatic urethra appears normal without evidence of dilation or obstruction.

The left kidney is normal in size (5.95 cm in length) with a normal shape, architecture and smooth peripheral margins. There is a normal 1:3 cortex to medulla ratio with mild loss of corticomedullary distinction. There is no evidence of pyelectasia, nephroliths, infarcts or hydroureter.

The right kidney is normal in size (5.71 cm in length) with a normal shape, architecture and smooth peripheral margins. There is a normal 1:3 cortex to medulla ratio with mild loss of corticomedullary distinction. There is no evidence of pyelectasia, nephroliths, infarcts or hydroureter.

Adrenal Glands

The left adrenal gland is normal in size (0.53 cm at cranial pole) (0.61 cm at caudal pole) (2.64 cm in length) with a normal shape and homogenous parenchyma. The glandular echogenicity and detail are unremarkable. Capsule, cortex, and medullary definition are normal. The phrenicoabdominal vein and surrounding vasculature are normal.

The right adrenal gland is in normal size (1.36cm at cranial pole) (0.59 cm at caudal pole) with a normal shape and homogenous parenchyma. The glandular echogenicity and detail are unremarkable. Capsule, cortex, and medullary definition are normal. The phrenicoabdominal vein and surrounding vasculature are normal.

Spleen

The spleen is normal in size (1.27 cm in width at the level of the hilus) with a normal capsular contour. There is appropriate echogenicity and echotexture. No focal lesions are observed. Splenic vasculature is normal.

Liver

The liver is subjectively normal in size with normal contours and structure. There is appropriate echogenicity and echotexture. No overt structural evidence of inflammatory, infiltrative, or regenerative pathology is evident. Vascular and biliary tracts are of normal volume with no evidence of congestion. No pathological hepatic lymphadenopathy observed.

The gall bladder lumen is moderately distended. The wall is thin and smooth. A small amount of suspended echogenic debris is observed within the lumen. The cystic and common bile ducts are normal/not seen.

Gastrointestinal

The gastric lumen is moderately distended with fluid and gas in the region of the pyloric antrum. Irregular shadowing material is visualized and extends through the pyloric outflow tract and into the small intestinal. The gastric wall and pylorus are normal to borderline thickened (up to 0.50 cm). Linear foreign

material is observed within the small intestinal lumen. In these segments, the bowel is plicated; and the wall is thickened (up to 0.56 cm). Surrounding mesentery is hyperechoic. Distal to the foreign material, the small intestinal segments are empty. The colonic wall is normal.

Pancreas
The right limb of the pancreas is visible with normal curvilinear peripheral contours. The parenchyma is largely isoechoic relative to surrounding omental fat and slightly mottled in appearance. The pancreatic duct is visible but not overtly dilated. There is no evidence of peripancreatic inflammation or effusion.

Free Abdomen
There is no obvious evidence of free fluid. The abdominal lymph nodes are normal/not visible.

ULTRASONOGRAPHIC FINDINGS

Primary Findings

- Suspected linear foreign body extending from the stomach into the small intestines, with bowel plication/obstruction and regional peritonitis.

- Urinary bladder mass in the ventral cystourethral junction. Differentials include neoplasia (i.e., transitional cell carcinoma) versus a focal inflammatory process.

Secondary Findings

- The pancreatic changes are most consistent with age-related parenchymal remodeling, potentially secondary to a prior inflammatory episode, early fibrosis or chronic pancreatitis.

INTERPRETATION OF THE FINDINGS & FURTHER RECOMMENDATIONS

- An abdominal exploratory is recommended to remove the gastrointestinal foreign body. Three-view thoracic radiographs should be performed prior to anesthesia to assess for occult aspiration pneumonia.

- Regarding the urinary bladder mass, a biopsy of the lesion can be considered at the time of surgery. Alternatively, a urine BRAF test can be performed to noninvasively assess for lower urinary tract neoplasia. A positive BRAF test confirms neoplasia. However, a negative test does not rule out the possibility of cancer.

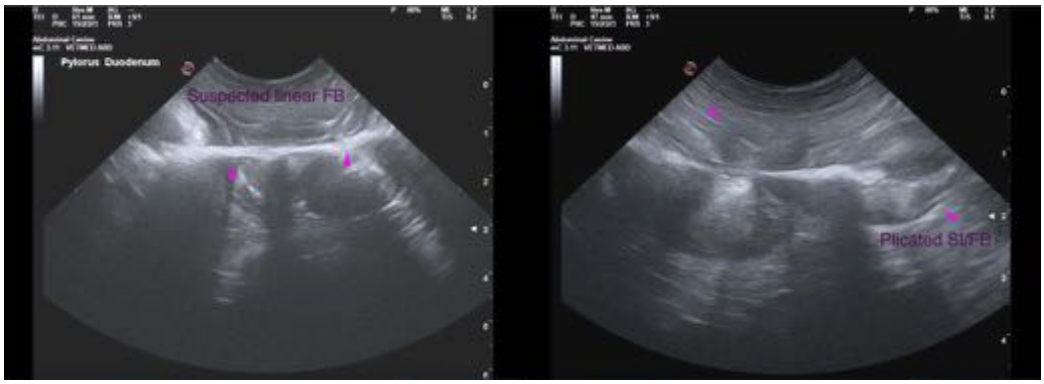

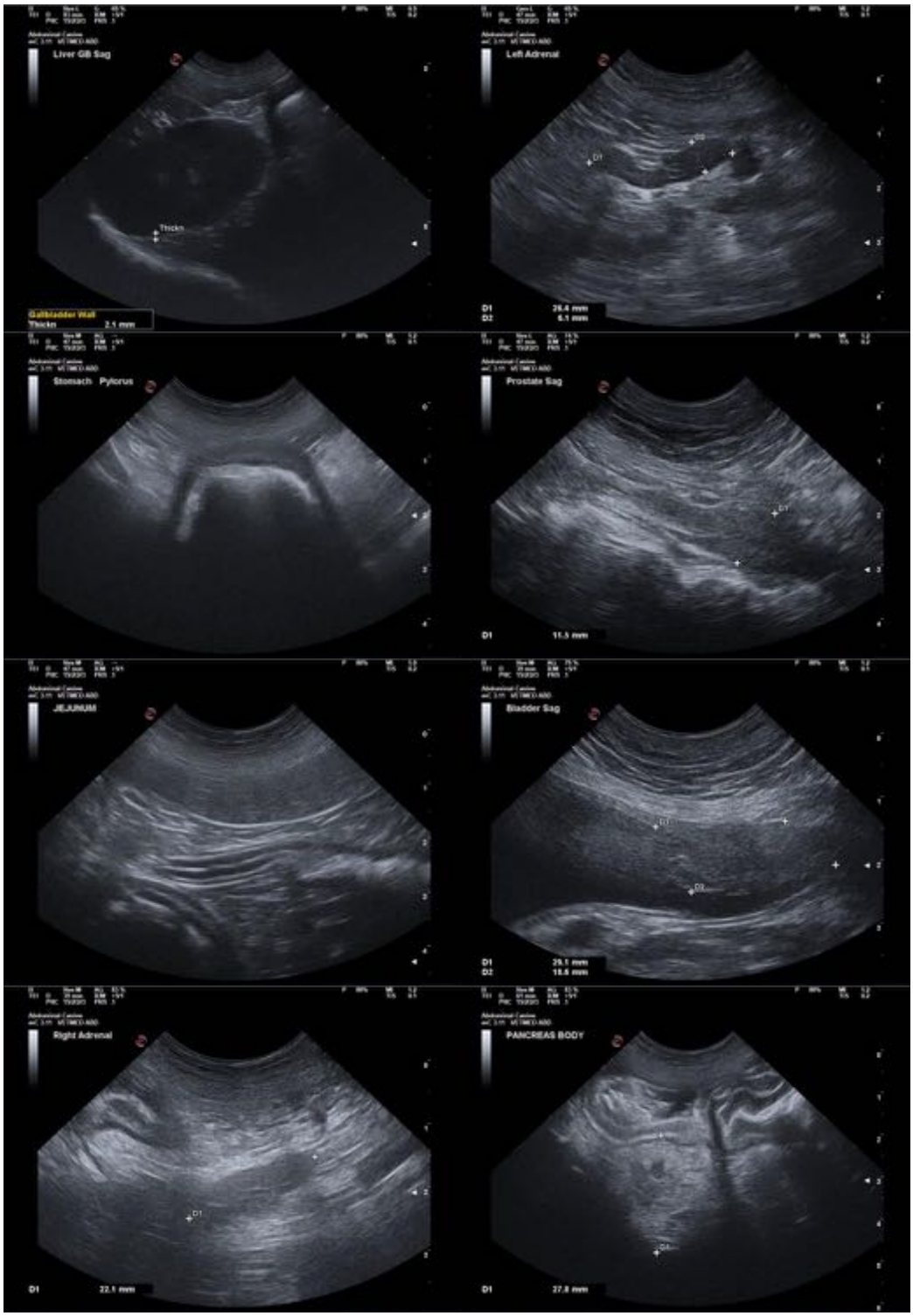
Liver GB Sag
Thickn
Gallbladder Wall
Thickn 2.1 mm
Left Adrenal
D1 26.4 mm
D2 6.1 mm
Stomach Pylorus
Prostate Sag
D1 11.1 mm
JEJUNUM
Bladder Sag
D1 29.1 mm
D2 18.8 mm
Right Adrenal
D1 22.1 mm
PANCREAS BODY
D1 27.8 mm

The information and recommendations provided are based on the images presented by the referring veterinarian/sonographer. No evaluation can be communicated regarding pathology that was not visible in the image/video clips provided.

Thank you for this referral. If the clinical or image interpretation does not parallel your findings or if I can be of any further assistance, please contact me.

Andrea Nicastro, MPH, DVM, Diplomate DACVIM (Small Animal Internal Medicine)
info@SonoPath.com