



**PATIENT PRESENTING CLINICAL SIGNS**

Carley Edwards Zoskey

History: presented 2d ago for wt loss of about 6wk duration, and inappetence -bloodwork consistent with hyperthyroidism -responded to mirtazapine and transdermal codeine yesterday but end of the day was no longer eating and not eating today

**SPECIES**

Feline

Abnormal PE/Chem/CBC/UA Results: T4>257nmol/L -mild non-responsive anemia -ALT 433 (12-130U/L) -Alk phos 219 (14-111U/L) -GGT 5 (0-4U/L) -creatinine 63 (71-212U/L)

**BREED**

DSH

**ULTRASONOGRAPHIC EXAMINATION OF THE ABDOMEN**

**SEX**

Spayed Female

**Urinary System**

The urinary bladder, trigone, and pelvic urethra are normal in thickness and the mucosal surface is smooth. The bladder lumen is moderately distended with anechoic urine. No masses, inflammatory changes or calculi are observed. Ureteral papillae and visualized portion of the proximal urethra, visible to a depth of 2 cm, are normal.

**AGE**

17 years

The left kidney is normal size (3.45 cm in length); normal shape and architecture with smooth peripheral margins. There is a normal 1:3 cortex to medulla ratio with minimal to mild loss of corticomedullary distinction. A hyperechoic medullary band is observed at adjacent to the corticomedullary junction. There is no evidence of pyelectasia, nephroliths, infarcts or hydroureter. Renal vasculature is normal.

**WEIGHT**

2.66 kg

The right kidney is normal size (3.24 cm in length); normal shape and architecture with smooth peripheral margins. There is a normal 1:3 cortex to medulla ratio with minimal to mild loss of corticomedullary distinction. A hyperechoic medullary band is observed at adjacent to the corticomedullary junction. Hyperechoic shadowing diverticular foci are visualized. A questionable cortical infarct is observed at at the cranial pole. There is no evidence of pyelectasia or hydroureter.

**INTERPRETED BY**

Andrea Nicastro, DVM,  
Diplomate ACVIM  
(Small Animal Internal  
Medicine)

**Adrenal Glands**

The region of the adrenal glands is evaluated. No obvious pathology is observed.

**IMAGING PERFORMED BY**

Crystal Hill

**Spleen**

The spleen is normal in size (0.57 cm in width at the level of the hilus) with a normal capsular contour. There is appropriate echogenicity and echotexture. No focal lesions are observed. Splenic vasculature is normal.

**HOSPITAL NAME**

Grand River VH

**Liver**

The liver is subjectively enlarged with slightly swollen peripheral contours. The parenchyma is hyperechoic relative to the spleen and diffusely homogeneous in appearance. No distinct focal lesions are observed. Vascular and biliary tracts are of normal volume with no evidence of congestion. The gall bladder lumen is moderately distended. The wall is thin and smooth. A small amount of aggregated echogenic partially dependent debris is observed within the lumen. The cystic and common bile ducts are normal/not seen.

**REFERRING VET**

Dr.Robinson

**INVOICE**

10490

The gall bladder lumen is moderately distended. The wall is thin and smooth. A small amount of echogenic debris is observed within the lumen. The cystic and common bile ducts are normal.

**DATE**

3/3/22

**Gastrointestinal**

The stomach and intestine are free of stasis and exhibit normal peristaltic activity. The gastric lumen is not distended. The gastric wall and pylorus are normal in thickness with a normal layering



**PATIENT**

Carley Edwards Zoskey

pattern. The pyloric outflow tract is patent. The small intestinal lumen is not dilated. The small intestinal wall thickness is normal with a normal layering pattern and appropriate mural detail. Discreet masses are not identified. The colonic wall is normal. No obstructive disease is noted.

**SPECIES**

Feline

**Pancreas**

The region of the pancreas is isoechoic relative to surrounding omental fat. No obvious parenchymal abnormalities are observed. There is no evidence of regional inflammation or effusion.

**BREED**

DSH

**Free Abdomen**

A small to moderate amount of free fluid is present. The mesentery throughout the abdomen is mildly hyperechoic. The abdominal lymph nodes are normal/not visible.

**SEX**

Spayed Female

**Other**

Pericardial effusion is noted on brief visualization of the thorax.

A few dilated tortuous vessels are observed in the left mid- to caudal abdomen.

**ULTRASONOGRAPHIC FINDINGS**

**AGE**

17 years

**Primary Findings**

- Pericardial effusion. Possible differentials include congestive heart failure, systemic inflammatory disease, cardiac neoplasia, other.
- The hepatic parenchymal changes are non-specific and could be secondary to passive congestion, an inflammatory hepatopathy (i.e., bacterial cholangiohepatitis, lymphoplasmacytic hepatitis), hepatic lipidosis, infiltrative neoplasia (i.e., lymphoma), other hepatopathy.
- The ascites may be secondary due to increased hydrostatic pressure (i.e., due to congestive heart failure), increased vascular permeability, or low oncotic pressure (if applicable).
- The dilated tortuous vessels in the mid- to caudal abdomen may be secondary to increased hydrostatic pressure (i.e., due to congestive heart failure), acquired shunting, congenital malformation, other.

**IMAGING PERFORMED BY**

Crystal Hill

**Secondary Findings**

- Bilateral age-related renal changes with right dystrophic mineralization and nonobstructive nephrolithiasis.

**HOSPITAL NAME**

Grand River VH

**INTERPRETATION OF THE FINDINGS & FURTHER RECOMMENDATIONS**

**REFERRING VET**

Dr.Robinson

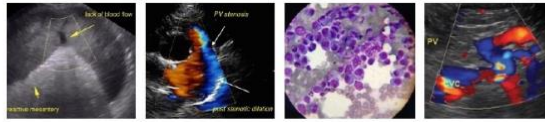
- Three-view thoracic radiographs and an echocardiogram (+/- blood pressure and ECG) are recommended to further evaluate for cardiovascular disease.
- Depending on the cardiac findings, further workup to investigated the elevated liver values may be warranted. Consider hepatic tissue sampling (i.e., fine-needle aspirate or surgical biopsy). Clotting times (i.e., PT/PTT) should be performed prior to any sampling procedure. If surgical biopsies are pursued, aerobic and anaerobic bile cultures are also recommended. If hepatic tissue sampling is not to be pursued and passive congestion of the liver is ruled out, consider empirical treatment for bacterial cholangiohepatitis (i.e., broad-spectrum antibiotics, hepatic antioxidants). If liver values do not improve within 5-7 days of initiating therapy, antibiotics should be discontinued, and hepatic tissue sampling revisited.

**INVOICE**

10490

**DATE**

3/3/22



**PATIENT**

Carley Edwards Zoskey

**SPECIES**

Feline

**BREED**

DSH

**SEX**

Spayed Female

**AGE**

17 years

**WEIGHT**

2.66 kg

**INTERPRETED BY**

Andrea Nicastro, DVM,  
Diplomate ACVIM  
(Small Animal Internal  
Medicine)

**IMAGING  
PERFORMED BY**

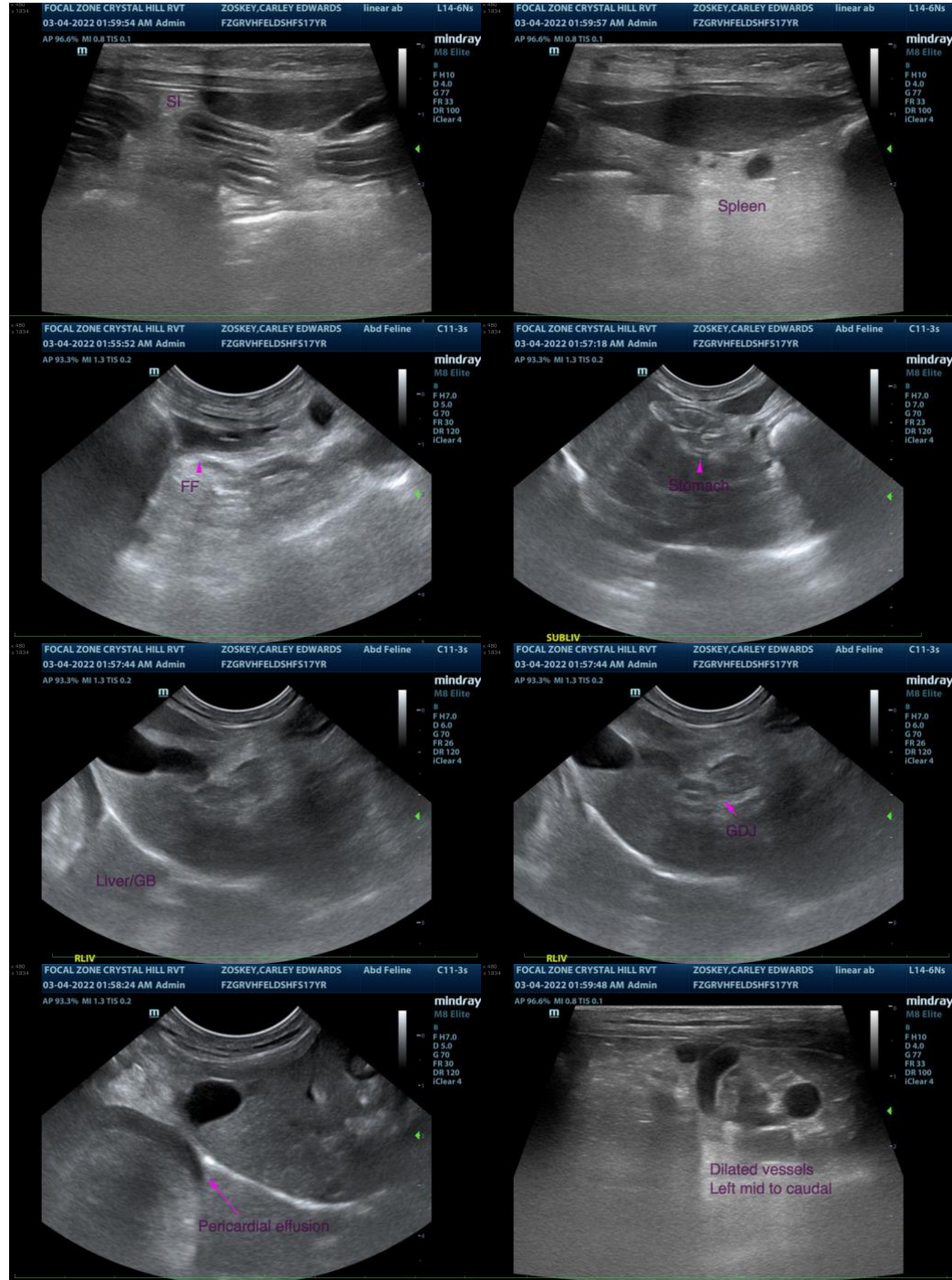
Crystal Hill

**HOSPITAL NAME**

Grand River VH

**REFERRING VET**

Dr. Robinson



The information and recommendations provided are based on the images presented by the referring veterinarian/sonographer. No evaluation can be communicated regarding pathology that was not visible in the image/video clips provided.

Thank you for this referral. If the clinical or image interpretation does not parallel your findings or if I can be of any further assistance, please contact me.

**INVOICE**

10490

**DATE**

3/3/22



**PATIENT**

Andrea Nicastro, DVM, Diplomate DACVIM (Small Animal Internal Medicine)  
info@SonoPath.com

Carley Edwards Zoskey

**SPECIES**

Feline

**BREED**

DSH

**SEX**

Spayed Female

**AGE**

17 years

**WEIGHT**

2.66 kg

**INTERPRETED BY**

Andrea Nicastro, DVM,  
Diplomate ACVIM  
(Small Animal Internal  
Medicine)

**IMAGING  
PERFORMED BY**

Crystal Hill

**HOSPITAL NAME**

Grand River VH

**REFERRING VET**

Dr.Robinson

**INVOICE**

10490

**DATE**

3/3/22