



PATIENT

Leonidas Calvert

PRESENTING CLINICAL SIGNS

Presentation: Anorexia, vomiting without production, lethargy. Not eating and drinking for several days. Tries to vomit, but not productive.

SPECIES

Feline

Abnormal lab-work values:

3/29/23: Alkp 155 (10-90), alt 202 (20-100), Tbil 1.7 (0.1-0.6), BUN 7 (10-30)

3/25/23: Alkp 197 (10-90), alt 228 (20-100), Tbil 1.3 (0.1-0.6), BUN 7 (10-30), K 3.6 (3.7-5.8)

3/22/23: Alkp 265 (10-90), alt 184 (20-100), Tbil 1.6 (0.1-0.6), BUN 8 (10-30), K 3.6 (3.7-5.8)

BREED

DMS-Tuxedo

3/29/23

ALT 202. ALP 166. tBili 1.7. BUN 7. Liver values have not improved with hospitalization, antibiotics and supportive care. CBC on 3/22/23 was unremarkable.

SEX

Neutered Male

Current treatments: fluid therapy

Current Medications: Ursodiol 62.5mg qd, Amoxi 50mg qd, Zeniquin 25mg qd

ULTRASONOGRAPHIC EXAMINATION OF THE ABDOMEN

AGE

03/22/2012

Urinary System

The urinary bladder wall is normal in thickness and the mucosal surface is smooth. The bladder is mildly to moderately distended. A small moderate amount of suspended echogenic debris is observed within the lumen. No cystic calculi are observed. The region of the trigone and the proximal urethra, visible to a depth of 2 cm, are normal.

WEIGHT

12 lbs, 6 oz

The left kidney is normal in size (3.99 cm in length) with a normal shape, architecture and smooth peripheral margins. There is a normal 1:3 cortex to medulla ratio with mild loss of corticomedullary distinction. There is no evidence of pyelectasia, nephroliths, infarcts or hydroureter. Renal vasculature is normal.

INTERPRETED BY

Andrea Nicastro, DVM,
Diplomate ACVIM (Small
Animal Internal Medicine)

The right kidney is normal in size (4.05 cm in length) with a normal shape, architecture and smooth peripheral margins. There is a normal 1:3 cortex to medulla ratio with normal corticomedullary distinction. There is no evidence of pyelectasia, nephroliths, infarcts or hydroureter. Renal vasculature is normal.

IMAGING PERFORMED BY

Andrea Nicastro, DVM,
Diplomate ACVIM (Small
Animal Internal Medicine)

Adrenal Glands

The left adrenal gland is normal size (0.38 cm width). Normal shape and glandular echogenicity. The phrenicoabdominal vein and surrounding vasculature are normal.

The right adrenal gland is normal size (0.36cm width). Normal shape and glandular echogenicity. The phrenicoabdominal vein and surrounding vasculature are normal.

HOSPITAL NAME

Central VH
Summerville

Spleen

The spleen is prominent to enlarged (1.21 cm in width at the level of the hilus) with a swelling of the medial contour and rounding at the poles. The spleen is folded. The parenchyma is homogenous. No focal lesions are observed. Splenic vasculature is normal with no evidence of thrombosis.

REFERRING VET

Arden Cordoza

Liver

The liver is subjectively prominent to enlarged with normal curvilinear peripheral contours. The parenchyma is hyperechoic relative to the spleen and diffusely homogeneous in appearance. No distinct focal lesions are observed. Vascular and biliary tracts are of normal volume with no evidence of congestion. The portal vein to caudal vena cava ratio is approximately 1: 1.

INVOICE

12556

The gall bladder lumen is moderately distended. The wall is thin and smooth. A small amount of echogenic debris is observed within the lumen. The cystic and common bile ducts are visible but not overtly dilated.

DATE

3.29.23

The common bile duct measures 0.31 cm in diameter and can be followed to the level of the duodenal papilla (which is normal in size / 0.48 cm in width). There is no obvious evidence of an intraluminal obstruction.

Gastrointestinal

The stomach and intestine are free of stasis and exhibit normal peristaltic activity. The gastric lumen is not distended. The gastric wall and pylorus are normal in thickness with a normal layering pattern. The pyloric outflow tract is patent. The small intestinal lumen is not dilated. The small intestinal wall thickness is normal with a normal layering pattern and appropriate mural detail. There is disruption in the normal 1:3 muscularis: mucosal ratio in several segments. Discreet masses are not identified. The ileocecal colic junction and colonic wall are normal. No obstructive disease is noted.

Pancreas

The left limb of the pancreas is visible/prominent with normal curvilinear peripheral contours. The parenchyma is hypoechoic relative to surrounding omental fat. The pancreatic duct is visible but not overtly dilated. There is no evidence of peripancreatic inflammation or effusion.

Free Abdomen

The peritoneal cavity is normal. There is no evidence of inflammation or effusion. The abdominal lymph nodes are normal/not visible.

Other

A brief echocardiogram reveals no evidence of pericardial effusion or obvious right atrial/auricular mass.

ULTRASONOGRAPHIC FINDINGS

Primary Findings

- Hepatic changes are non-specific and could be consistent with hepatic lipidosis, inflammatory/infectious disease, infiltrative neoplasia, or other hepatopathy.
- Bowel pattern consistent with inflammatory bowel disease with some potential for emerging lymphoma. However, bowel neoplasia is considered unlikely at this time.
- The pancreatic changes are most consistent with age-related parenchymal remodeling, potentially secondary to a prior inflammatory episode, early fibrosis or chronic pancreatitis.
- The splenomegaly could be consistent with lymphoid hyperplasia, extramedullary hematopoiesis, antigenic stimulation, splenitis or infiltrative neoplasia (i.e., lymphoma).

*Given the sonographic changes "triaditis" is a consider in this patient.

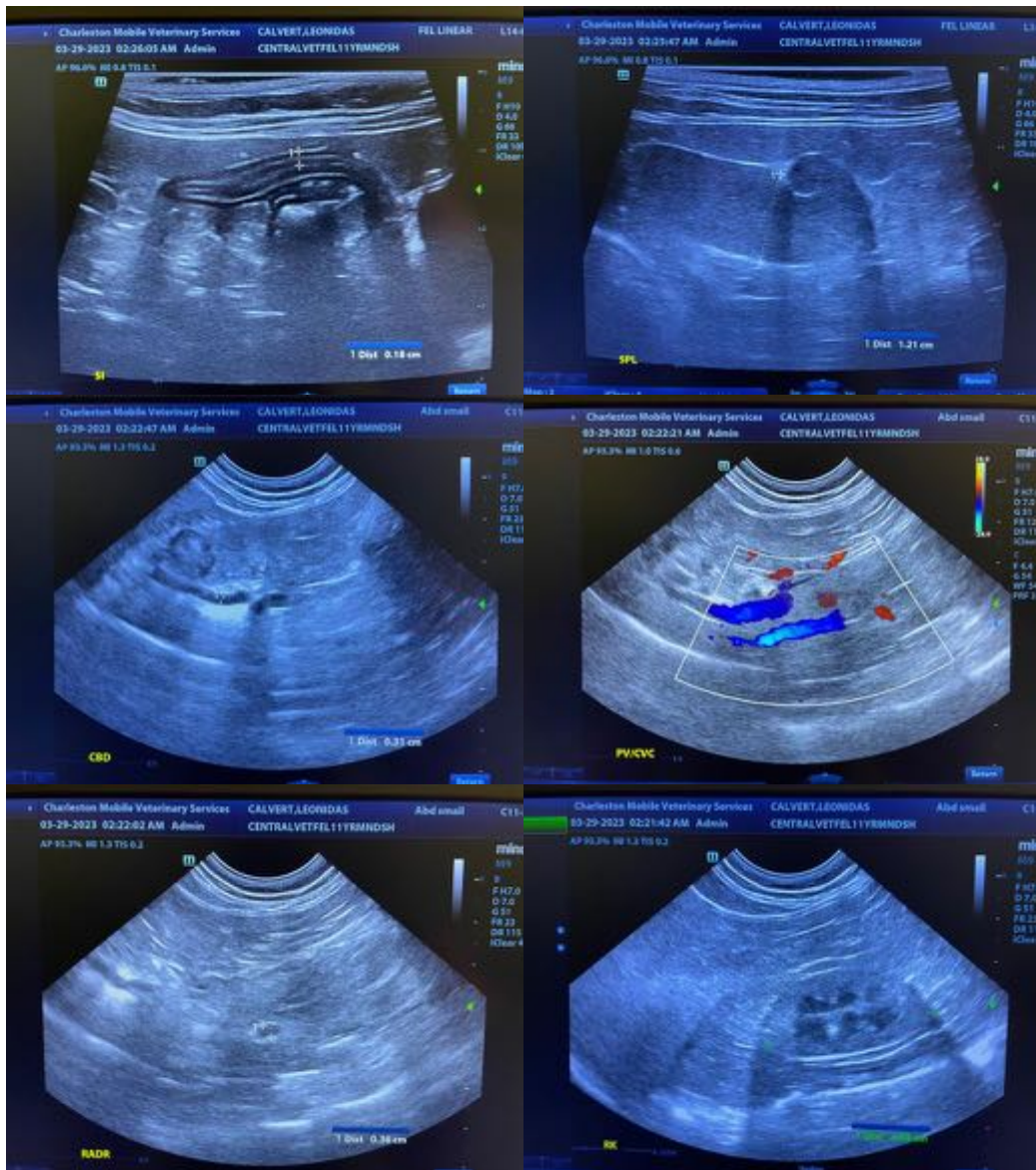
Secondary Findings

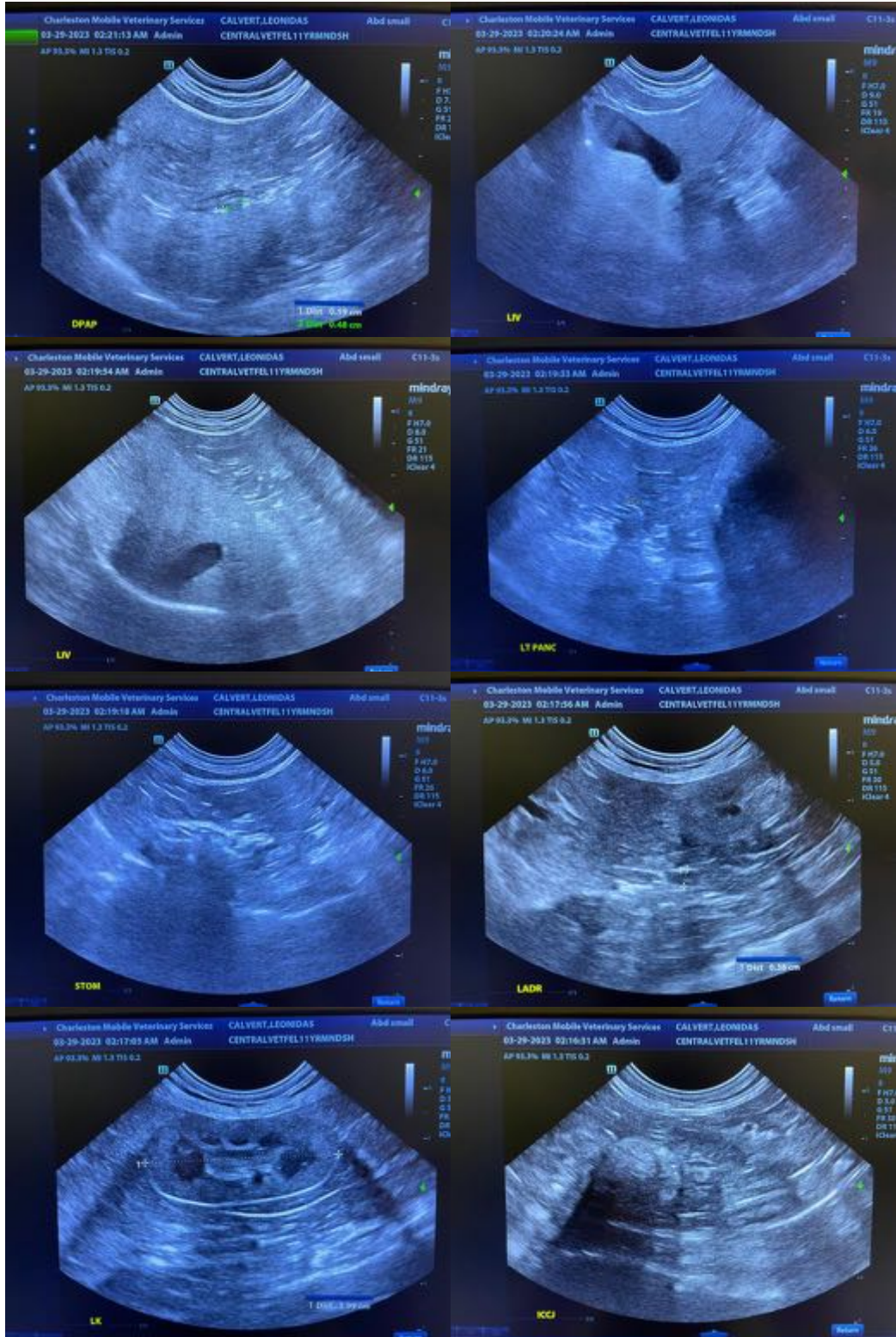
- Mild bilateral age-related renal changes

INTERPRETATION OF THE FINDINGS & FURTHER RECOMMENDATIONS

- Consider fine-needle aspirates of the liver and spleen (if clotting status is appropriate). Twenty-five gauge-needles should be used. If the cytology results are inconclusive, liver biopsies with aerobic and anaerobic bile cultures can be considered.

- Consider nutritional support (i.e., via temporary feeding tube) to help prevent/treat hepatic lipidosis.
- A malabsorption panel, including serum cobalamin and folate, TLI and PLI should also be considered.
- Consider toxoplasmosis testing, particularly if the pts goes outdoors.





The information and recommendations provided are based on the images presented by the referring veterinarian/sonographer. No evaluation can be communicated regarding pathology that was not visible in the image/video clips provided.

Thank you for this referral. If the clinical or image interpretation does not parallel your findings or if I can be of any further assistance, please contact me.

Andrea Nicastro, MPH, DVM, Diplomate DACVIM (Small Animal Internal Medicine)
info@SonoPath.com