


**PATIENT PRESENTING CLINICAL SIGNS**

**Korra Anderson** History: p has not been eating for 2 days, drinking small amounts but less than usual. Vomiting 2days, most of the time nothing comes up, sometimes water/saliva. lethargic 2 days. HX of anemia HCT 23% at pDVM in Feb

**SPECIES**

Feline

Abnormal PE/Chem/CBC/UA Results: EPOC: Gluc 138 iCa 1.20. PCV/TS: 38 /6.4

**ULTRASONOGRAPHIC EXAMINATION OF THE ABDOMEN**
**BREED**
**Urinary System**

DLH

The urinary bladder wall is normal in thickness and the mucosal surface is smooth. The bladder is moderately distended. Luminal contents are anechoic. No cystic calculi are observed. The region of the trigone and visible portion of the proximal urethra are normal.

**SEX**

Spayed Female

The left kidney is normal in size (3.58 cm in length) with a normal shape, architecture and smooth peripheral margins. There is a normal 1:3 cortex to medulla ratio with minimal to mild loss of corticomedullary distinction. There is no evidence of pyelectasia, nephroliths, infarcts or hydroureter. Renal vasculature is normal.

**AGE**

9 years

The right kidney is normal in size (3.48 cm in length) with a normal shape, architecture and smooth peripheral margins. There is a normal 1:3 cortex to medulla ratio with minimal to mild loss of corticomedullary distinction. There is no evidence of pyelectasia, nephroliths, infarcts or hydroureter. Renal vasculature is normal.

**WEIGHT**

2.19 kg

**Adrenal Glands**

The left adrenal gland is normal size (0.39 cm width). Normal shape and glandular echogenicity. The phrenicoabdominal vein and surrounding vasculature are normal.

**INTERPRETED BY**

 Andrea Nicastro, DVM,  
 Diplomate ACVIM (*Small  
 Animal Internal Medicine*)

The right adrenal gland is normal size (0.25 cm width). Normal shape and glandular echogenicity. The phrenicoabdominal vein and surrounding vasculature are normal.

**IMAGING PERFORMED BY**

 Brittany Gardner,  
 DVM

**Spleen**

The spleen is normal in size (0.55 cm in width at the level of the hilus) with a normal capsular contour. There is appropriate echogenicity and echotexture. No focal lesions are observed. Splenic vasculature is normal.

**HOSPITAL NAME**

Wilvet Salem

**Liver**

The liver is subjectively normal in size with normal contours and structure. There is appropriate echogenicity and echotexture. No overt structural evidence of inflammatory, infiltrative, or regenerative pathology is evident. Vascular and biliary tracts are of normal volume with no evidence of congestion. No pathological hepatic lymphadenopathy observed.

**REFERRING VET**

 Brittany Gardner,  
 DVM

The gall bladder lumen is moderately distended. The wall is thin and smooth. A small amount of mostly gravity-dependent echogenic debris is observed within the lumen. The cystic and common bile ducts are normal/not seen.

**INVOICE**

12546

**Gastrointestinal**

The gastric lumen is moderately distended. Irregular shadowing material is observed within the lumen. Linear foreign material appears to extend into the duodenum, causing plication. In the remaining small intestinal segments, the lumen is gas-distended. The colonic lumen is normal.

**DATE**

3.29.23

### ***Pancreas***

The pancreas is partially obscured by the gastric distention. In the visualized portion of the left limb, the pancreas is normal to slightly prominent in size with minimal deviation from the normal peripheral contours. The parenchyma is mildly hypoechoic relative to surrounding omental fat and homogenous in appearance. The pancreatic duct is not overtly dilated.

### ***Free Abdomen***

Trace free fluid is observed. The abdominal lymph nodes are normal/not visible.

## **ULTRASONOGRAPHIC FINDINGS**

### **Primary Findings**

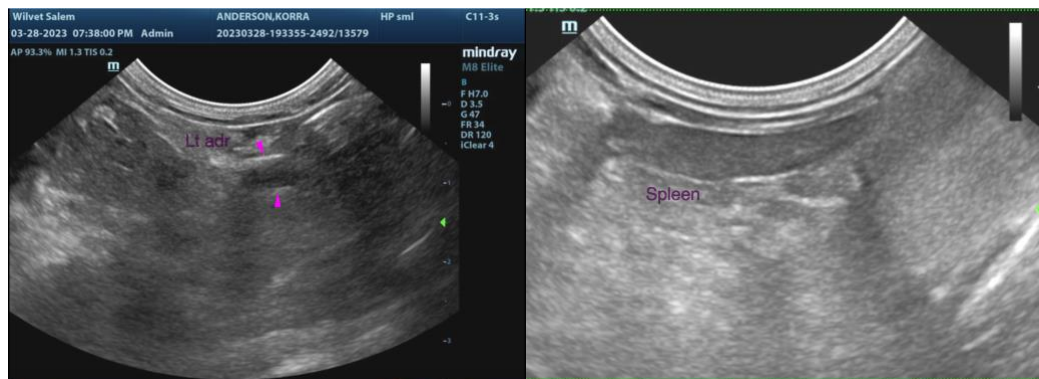
- Suspected linear foreign body within the stomach with extension into the duodenum.
- The ascites is likely secondary to peritonitis.

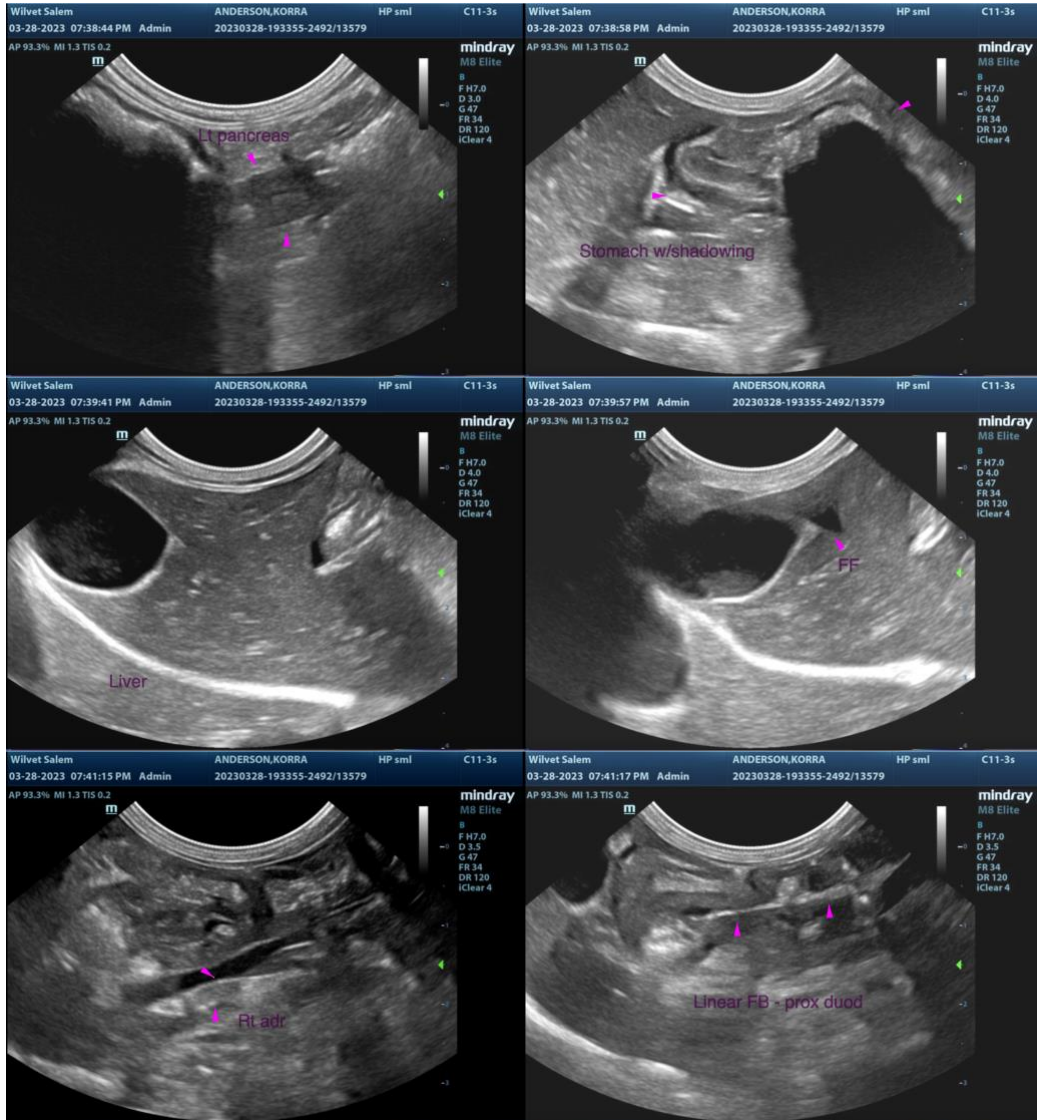
### **Secondary Findings**

- The pancreatic changes may be a normal variant for this patient or could be consistent with mild, chronic pancreatitis. Correlation with clinical findings is recommended.
- Minor bilateral age-related renal changes

## **INTERPRETATION OF THE FINDINGS & FURTHER RECOMMENDATIONS**

- An abdominal exploratory is recommended to remove gastrointestinal foreign material.
- Consider three-view thoracic radiographs prior to anesthesia to assess for occult aspiration pneumonia.





The information and recommendations provided are based on the images presented by the referring veterinarian/sonographer. No evaluation can be communicated regarding pathology that was not visible in the image/video clips provided.

Thank you for this referral. If the clinical or image interpretation does not parallel your findings or if I can be of any further assistance, please contact me.

**Andrea Nicastro, MPH, DVM, Diplomate DACVIM (Small Animal Internal Medicine)**  
[info@SonoPath.com](mailto:info@SonoPath.com)