



**PATIENT PRESENTING CLINICAL SIGNS**

**Roxy Martinez** History: The patient presented for an abdominal ultrasound to evaluate the bladder. Pt had a previous UTI and while collecting urine by cystocentesis noticed a suspicious mass in the bladder and wanted to further evaluate. The previous UTI got treated successfully with enrofloxacin.

**SPECIES**

Canine

Abnormal PE/Chem/CBC/UA Results/PE: BCS 4/9 February 15-2023 BW: CBC: Lymphocytes ( 0.45 )1.05 - 5.10 K/ $\mu$ L CHEM: Amylase (441) 500 - 1,500 U/L

**BREED**

Mixed

**Urinary System**

The urinary is mildly distended. An approximately 1.77 cm irregular mass effect is observed at the caudal aspect, in the region of the cystourethral junction. The mass appears to extend into the proximal urethra.

**SEX**

Female Spayed

Foci of mineralization are observed throughout the mass. The remaining urinary bladder wall is of appropriate thickness for the level of repletion. The luminal surface is slightly irregular. No cystic calculi are observed. A scant amount of echogenic debris is suspended within the lumen.

**AGE**

14 years

The left kidney is normal in size (6.83 cm in length) with a normal shape, architecture and smooth peripheral margins. There is a normal 1:3 cortex to medulla ratio with minimal to mild loss of corticomedullary distinction. There is no evidence of pyelectasia, nephroliths, infarcts or hydroureter.

**WEIGHT**

38 lbs

The right kidney is normal in size (7.03 cm in length) with a normal shape, architecture and smooth peripheral margins. There is a normal 1:3 cortex to medulla ratio with minimal to mild loss of corticomedullary distinction. There is no evidence of pyelectasia, nephroliths, infarcts or hydroureter.

**INTERPRETED BY**

Andrea Nicastro, DVM,  
Diplomate ACVIM  
(Small Animal Internal  
Medicine)

**Adrenal Glands**

The left adrenal gland is borderline enlarged (0.71 cm at cranial pole) (0.70 cm at caudal pole) (2.61 cm in length) with a normal shape and homogenous parenchyma. The glandular echogenicity and detail are unremarkable. Capsule, cortex, and medullary definition are normal. The phrenicoabdominal vein and surrounding vasculature are normal.

The right adrenal gland is borderline enlarged (1.76 cm at cranial pole) (0.69 cm at caudal pole) (2.83 cm in length) with a normal shape and homogenous parenchyma. The glandular echogenicity and detail are unremarkable. Capsule, cortex, and medullary definition are normal. The phrenicoabdominal vein and surrounding vasculature are normal.

**IMAGING PERFORMED BY**

Dr. Ferrer DVM

**Spleen**

The spleen is normal in size (1.55 cm in width at the level of the hilus) with a normal capsular contour. There is appropriate echogenicity and echotexture. No focal lesions are observed. Splenic vasculature is normal.

**HOSPITAL NAME**

Paseos VC

**Liver**

The liver is subjectively prominent in size with slightly irregular peripheral contours. Numerous, varying-sized hypoechoic-to-slightly heterogenous masses (some of which are coalescing) are observed throughout the organ. Several of the lesions cause capsular expansion. Hepatic vasculature and intrahepatic biliary tracts are of normal volume with no evidence of congestion.

**REFERRING VET**

Dr. Gabriel Ferrer

**INVOICE**

12553

The gall bladder lumen is moderately distended. The wall is thin and smooth. A small to moderate amount of echogenic-to-mineralized debris/sludge is observed within the lumen (most of which is gravity-dependent and some of which is suspended). The cystic and common bile ducts are normal/not seen.

**DATE**

3.28.23

### ***Gastrointestinal***

The stomach and intestine are free of stasis and exhibit normal peristaltic activity. The gastric lumen is not distended. The gastric wall and pylorus are normal in thickness with a normal layering pattern. The pyloric outflow tract is patent. The small intestinal lumen is not dilated. The small intestinal wall is normal in thickness with a normal layering pattern and appropriate mural detail. Discreet masses are not identified. The colonic wall is normal. There is no evidence of an obstructive pattern.

### ***Pancreas***

The right limb is visible/prominent with minimal deviation from the normal peripheral contours. The parenchyma is hypoechoic relative to surrounding omental fat. The pancreatic duct is not overtly dilated. (See also "Other" category).

### ***Free Abdomen***

There is no obvious evidence of free fluid. Two medial iliac lymph nodes are visualized (the largest measuring 2.45 cm in length). The nodes are slightly hypoechoic and mildly irregular in appearance. Two-three enlarged, rounded hypoechoic lymph nodes are observed in the cranial abdomen (the largest measuring approximately 3.00 cm in length). (See also "Other" category).

### ***Other***

A >7.00 cm irregular hypoechoic-to-heterogenous mass is observed in the cranial to midabdominal. Surrounding mesentery is hyperechoic.

### **Primary Findings**

- Large cranial- to midabdominal mass (the origin of which is unclear). It may be arising from lymph nodes, pancreas, mesentery, other. Neoplasia is suspected with a lower possibility of a severe focal inflammatory process.
- The diffuse hepatic masses are concerning for metastatic disease, with a lower possibility of multifocal inflammatory disease.
- The urinary bladder mass is most consistent with a neoplastic process. Transitional cell carcinoma is the top differential. It appears to be extending into the proximal urethra.
- The medial iliac lymphadenopathy may represent reactive change or metastatic disease from the urinary bladder.
- The cranial abdominal lymphadenopathy likely represents metastatic disease with a lower possibility of reactive change.

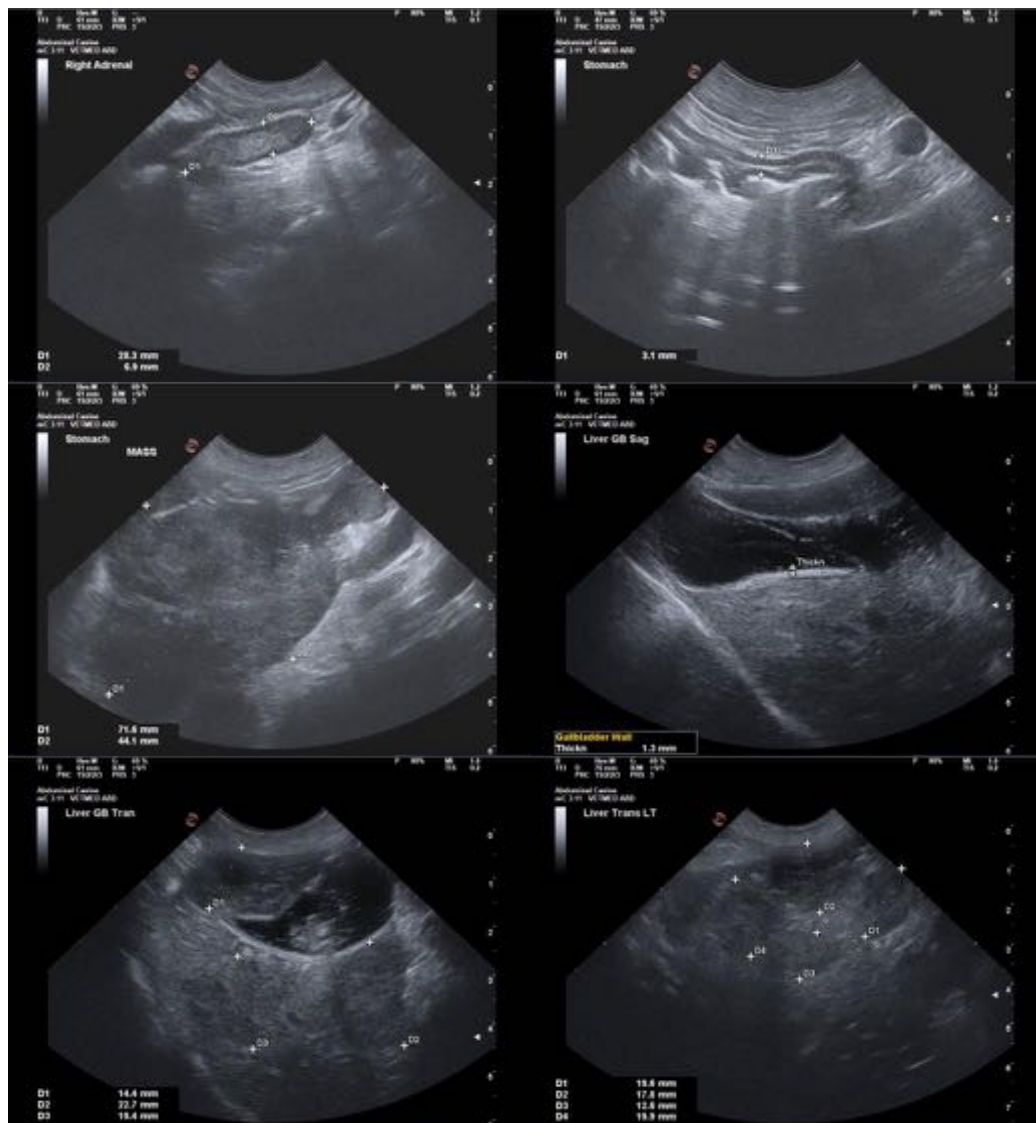
### **Secondary Findings**

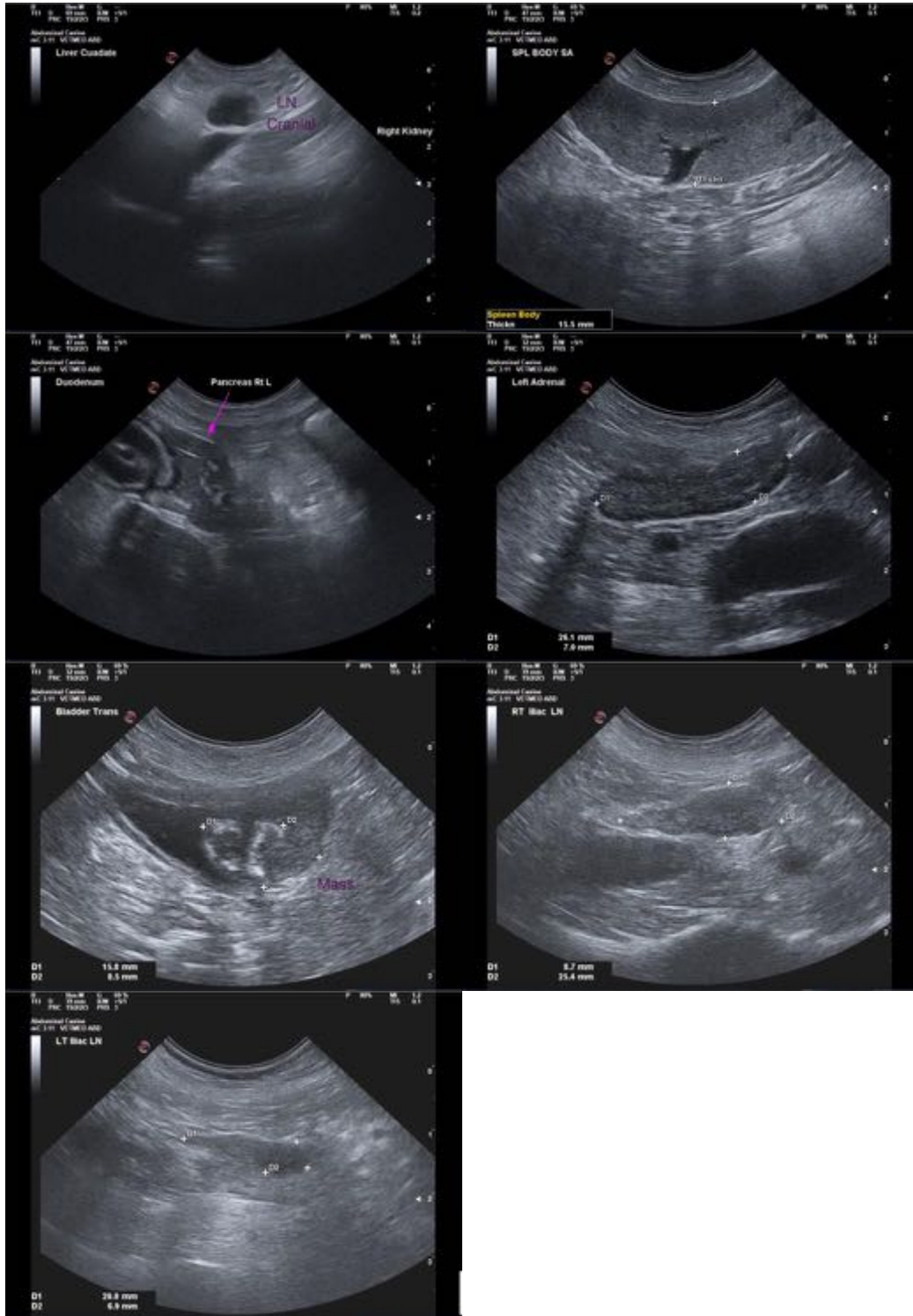
- Minor bilateral age-related renal changes
- The pancreatic changes may be a normal variant for this patient or could be consistent with mild, chronic pancreatitis. Correlation with clinical findings is recommended.
- Borderline bilateral adrenomegaly

\*It is unclear whether the urinary bladder mass is related to the liver and cranial abdominal masses. This is not the typical location for transitional cell carcinoma to metastasize to. However, this possibility cannot be completely excluded.

### INTERPRETATION OF THE FINDINGS & FURTHER RECOMMENDATIONS

- Three-view thoracic radiographs are recommended to assess for pulmonary metastases.
- Fine-needle aspirates of the hepatic and cranial abdominal masses can be considered (if clotting status is appropriate). Twenty-five gauge-needles should be used. A urine BRAF test can also be considered to confirm lower urinary tract neoplasia. However, given the likelihood of multifocal neoplasia, the prognosis is considered guarded and palliative care should be considered for this patient in lieu of aggressive diagnostics/treatments.





The information and recommendations provided are based on the images presented by the referring veterinarian/sonographer. No evaluation can be communicated regarding pathology that was not visible in the image/video clips provided.

Thank you for this referral. If the clinical or image interpretation does not parallel your findings or if I can be of any further assistance, please contact me.

**Andrea Nicastro**, MPH, DVM, Diplomate DACVIM (Small Animal Internal Medicine)  
[info@SonoPath.com](mailto:info@SonoPath.com)