



PATIENT PRESENTING CLINICAL SIGNS

Snow Miller

- P seen at rDVM 3/4/26 for annual exam and vaccines. P had not been eating well for 2 weeks before then. 3/2025 p weight was 12.06 pounds. 3/4 rDVM p weighed 10.06 pounds. Owner notes continued hyporexia (total of 4-6 weeks ne well). P has continued weight loss. P today is 4.19 kg (9.21 pounds). History of dental disease, UTI, crystalluria, and otitis.

SPECIES

Feline

- Concern for weight loss, continued hyporexia, liver disease, primary GI disease, other

BREED

DSH

Abnormal PE/Chem/CBC/UA Results: PE: doughy abdomen, generalized muscle wasting, un-thrifty, unkempt hair coat rDVM 3/4/26 CBC: hgb 10.2 L, platelets 87,000 L w/ adequate number & clumping noted on manual review chem: creatinine 0.7 L, TP 8.9 H, globulin 6.0 H, ALT 26 L, AST 15 L, ALP 9 L, t bilirubin 0.8 H u/a: color dark yellow, clarity clear, USG 1.054, pH 6.0, protein 2+; sediment unremarkable fecal O & P: negative; Idexx fecal antigen: negative T4: 1.6

SEX

Neutered Male

ULTRASONOGRAPHIC EXAMINATION OF THE ABDOMEN

AGE

12

Urinary System

The urinary bladder wall is normal in thickness. The mucosal surface is smooth. The bladder is mildly- to moderately distended. A scant amount of suspended echogenic debris is observed within the lumen. No cystic calculi are observed. The region of the trigone and visible portion of the proximal urethra are normal.

WEIGHT

4.19 kg

The left kidney is normal in size (4.07 cm in length) with a normal shape, architecture and smooth peripheral margins. There is a normal 1:3 cortex to medulla ratio with mild loss of corticomedullary distinction. A hyperechoic medullary band is observed adjacent to the corticomedullary junction. There is no evidence of pyelectasia, nephroliths, infarcts or hydroureter. Renal vasculature is normal.

INTERPRETED BY

Andrea Nicastro, DVM,
Diplomate ACVIM
(Small Animal Internal
Medicine)

The right kidney is normal in size (4.28 cm in length) with a normal shape, architecture and smooth peripheral margins. There is a normal 1:3 cortex to medulla ratio with mild loss of corticomedullary distinction. A hyperechoic medullary band is observed adjacent to the corticomedullary junction. There is no evidence of pyelectasia, nephroliths, infarcts or hydroureter. Renal vasculature is normal.

IMAGING PERFORMED BY

Melissa Randolph

Adrenal Glands

The region of the adrenal glands is evaluated. No obvious pathology is observed in this region.

HOSPITAL NAME

Shores VEC

Spleen

The spleen is normal in size (0.73 cm in width at the level of the hilus) with a normal capsular contour. There is appropriate echogenicity and echotexture. No focal lesions are observed. Splenic vasculature is normal.

REFERRING VET

Logan Law

Liver

The liver is subjectively normal in size with normal curvilinear peripheral contours. The parenchyma is isoechoic relative to the spleen and diffusely homogeneous in appearance. No distinct focal lesions are observed. Vascular and biliary tracts are of normal volume with no evidence of congestion.

INVOICE

22739

The gallbladder lumen is moderately distended. The wall is thin and smooth. Luminal contents are mostly anechoic. The cystic and common bile ducts are normal/not seen.

DATE

3-26-26

Gastrointestinal

The stomach and intestine are free of stasis and exhibit normal peristaltic activity. The gastric lumen is not distended. The gastric wall and pylorus are normal in thickness with a normal layering pattern. The pyloric outflow tract is patent. The small intestinal lumen is not dilated. The small intestinal wall thickness is



PATIENT

normal. There is disruption in the normal 1:3 muscularis: mucosal ratio. Discreet masses are not identified. The ileocecal colic junction and colonic wall are normal. No obstructive disease is noted.

Snow Miller

SPECIES

Pancreas

The region of the pancreas is isoechoic relative to surrounding omental fat. No obvious parenchymal abnormalities are observed. There is no evidence of regional inflammation or effusion.

Feline

BREED

Lymph Nodes

A few prominent mesenteric lymph nodes are visualized (one measuring 1.82 x 0.45 cm). Surrounding mesentery is mildly hyperechoic.

DSH

SEX

Free Abdomen

There is no obvious evidence of free fluid.

Neutered Male

ULTRASONOGRAPHIC FINDINGS

AGE

Primary Findings

12

- The small intestinal wall changes could be consistent with inflammatory bowel disease, normal variation, or less likely, emerging lymphoma.

WEIGHT

4.19 kg

- The prominent abdominal lymph nodes are most consistent with reactive lymphadenitis or lymphoid hyperplasia. Neoplastic infiltration is considered less likely.

INTERPRETED BY

Secondary Findings

Andrea Nicastro, DVM,
Diplomate ACVIM
(Small Animal Internal
Medicine)

- Bilateral nonspecific age-related renal changes

*An obvious cause for the patient's clinical signs is not definitively identified in this study. Considerations include maldigestion/malabsorption, underlying metabolic issue, occult neoplasia, orthopedic or neurologic disease, dental disease, other.

IMAGING PERFORMED BY

Melissa Randolph

INTERPRETATION OF THE FINDINGS & FURTHER RECOMMENDATIONS

HOSPITAL NAME

Given the vague clinical signs, consider the following:

Shores VEC

1. Orthopedic and neurologic examinations
2. Oral examination to assess for dental disease
3. Three-view thoracic radiographs to assess cardiopulmonary status
4. GI panel including serum cobalamin and folate, TLI and PLI
5. Depending on the results of the above diagnostics, further work-up (i.e., GI biopsies) may be warranted.

REFERRING VET

Logan Law

INVOICE

22739

DATE

3-26-26



PATIENT

Snow Miller

SPECIES

Feline

BREED

DSH

SEX

Neutered Male

AGE

12

WEIGHT

4.19 kg

INTERPRETED BY

Andrea Nicastro, DVM,
Diplomate ACVIM
(Small Animal Internal
Medicine)

**IMAGING
PERFORMED BY**

Melissa Randolph

HOSPITAL NAME

Shores VEC

REFERRING VET

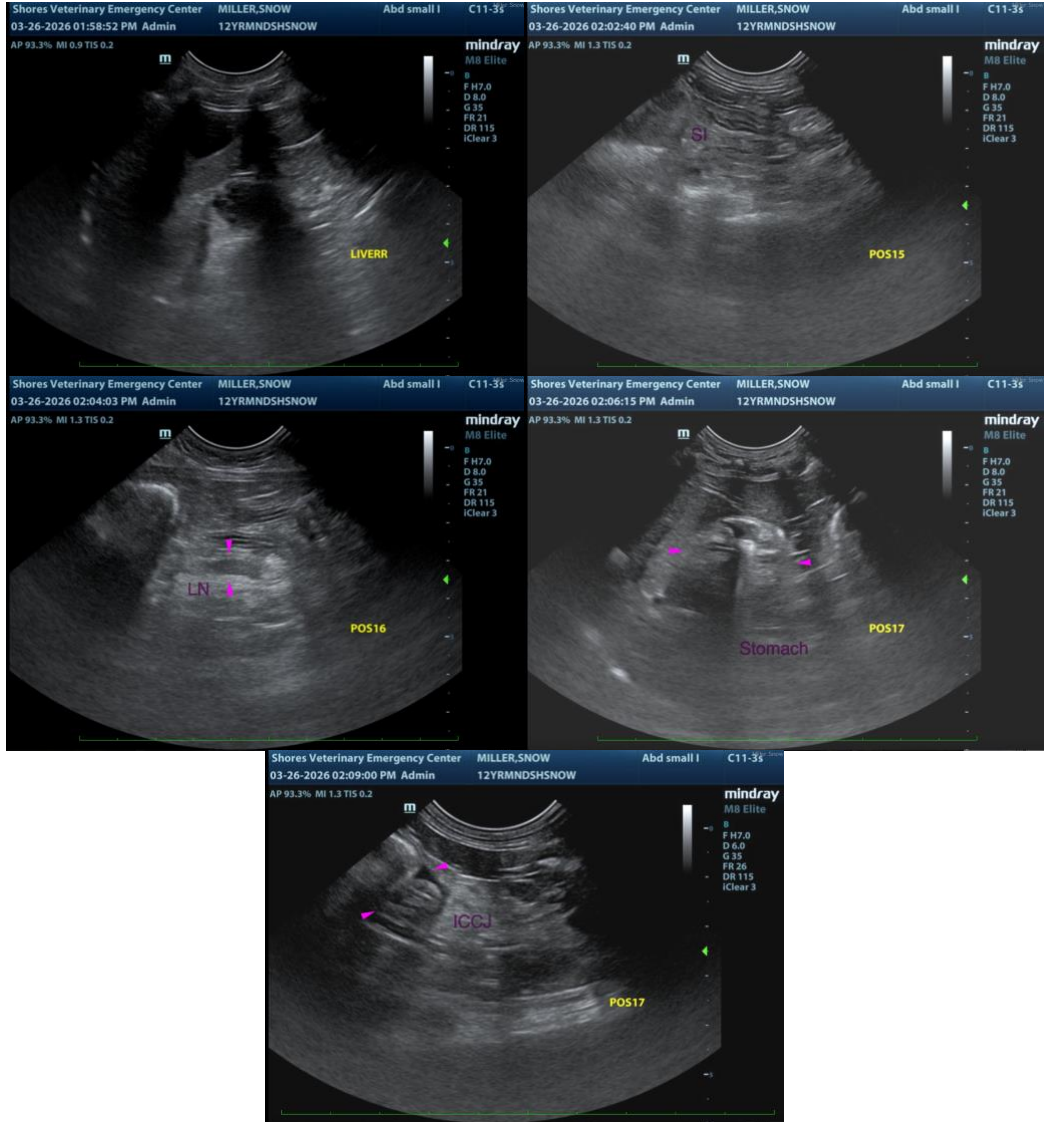
Logan Law

INVOICE

22739

DATE

3-26-26



The information and recommendations provided are based on the images presented by the referring veterinarian/sonographer. No evaluation can be communicated regarding pathology that was not visible in the image/video clips provided.

Thank you for this referral. If the clinical or image interpretation does not parallel your findings or if I can be of any further assistance, please contact me.

Andrea Nicastro, MPH, DVM, Diplomate DACVIM (Small Animal Internal Medicine)
info@SonoPath.com