



PATIENT PRESENTING CLINICAL SIGNS

Cholula Camacho History: Patient presents for urinary incontinence inspire of being on Prion. Mild elevations of creatinine, SDMA. USG from today normal. Otherwise apparently healthy.

SPECIES ULTRASONOGRAPHIC EXAMINATION OF THE ABDOMEN

Canine

Urinary System

BREED

The urinary bladder wall is normal in thickness. The mucosal surface is smooth. The bladder is moderately distended. Luminal contents are anechoic. No cystic calculi are observed. The region of the trigone and the proximal urethra, visible to a depth of 2 cm, are normal.

German Shepherd

SEX

The left kidney is normal-in-size (6.45 cm in length) with a normal shape, architecture and smooth peripheral margins. There is a normal 1:3 cortex to medulla ratio with minimal loss of corticomedullary distinction. There is no evidence of pyelectasia, nephroliths, infarcts or hydroureter.

Female Spayed

AGE

The right kidney is normal in size (6.85 cm in length) with a normal shape, architecture and smooth peripheral margins. There is a normal 1:3 cortex to medulla ratio with minimal loss of corticomedullary distinction. There is no evidence of pyelectasia, nephroliths, infarcts or hydroureter.

8

WEIGHT

Adrenal Glands

The region of the adrenal glands is evaluated. No obvious pathology is observed in this region.

69.8

Spleen

INTERPRETED BY

The spleen is subjectively normal-in-size with a normal capsular contour. There is appropriate echogenicity and echotexture. No focal lesions are observed. Splenic vasculature is normal.

Andrea Nicastro, DVM,
Diplomate ACVIM
(Small Animal Internal
Medicine)

Liver

The liver is subjectively normal in size with normal contours and structure. There is appropriate echogenicity and echotexture. No overt structural evidence of inflammatory, infiltrative, or regenerative pathology is evident. Vascular and biliary tracts are of normal volume with no evidence of congestion.

IMAGING PERFORMED BY

Mario

The gallbladder is of normal contours and contains some dependent echogenic debris. The wall is normal in thickness. No choleliths are observed. The cystic and common bile ducts are normal/not seen.

HOSPITAL NAME

Gastrointestinal

The gastric lumen is mildly gas-distended. The gastric wall is normal in thickness with a normal layering pattern. The small intestinal lumen is segmentally gas-distended. The small intestinal wall is normal in thickness with a normal layering pattern and appropriate mural detail. Discreet masses are not identified. The colonic wall is normal. There is no evidence of an obstructive pattern.

TLC Animal Hospital

REFERRING VET

Pancreas

The region of the pancreas is isoechoic relative to surrounding omental fat. No obvious parenchymal abnormalities are observed. There is no evidence of regional inflammation or effusion.

Cristina Ramirez DVM

INVOICE

Lymph Nodes

The abdominal lymph nodes are normal/not visible.

22733

DATE

Free Abdomen

The peritoneal cavity is normal. There is no evidence of inflammation or effusion.

3-25-26



PATIENT ULTRASONOGRAPHIC FINDINGS

Cholula Camacho

Structurally unremarkable abdomen. An obvious cause for the patient's urinary incontinence is not identified in this study. Considerations include urethral sphincter mechanism incompetence, urinary tract infection, underlying metabolic issue, primary neurologic disease, other.

SPECIES

Canine

INTERPRETATION OF THE FINDINGS & FURTHER RECOMMENDATIONS

BREED

German Shepherd

- A neurologic examination is recommended to assess for deficits.
- A urine culture and sensitivity are recommended to assess for occult infection. If results are negative, consider additional medical management for urethral sphincter mechanism incompetence.

SEX

Female Spayed

AGE

8

WEIGHT

69.8

INTERPRETED BY

Andrea Nicastro, DVM,
Diplomate ACVIM
(Small Animal Internal
Medicine)

IMAGING PERFORMED BY

Mario

HOSPITAL NAME

TLC Animal Hospital

REFERRING VET

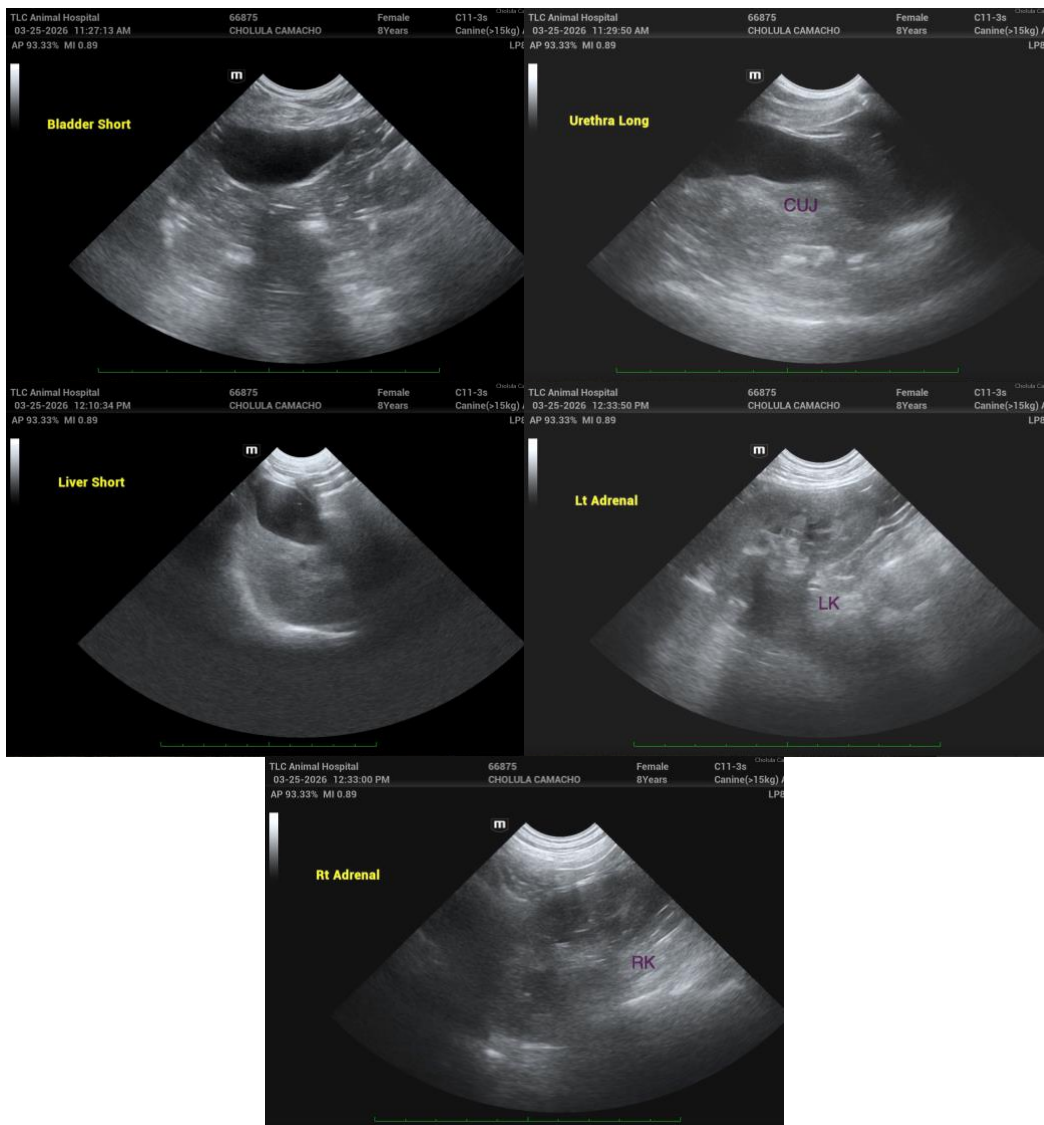
Cristina Ramirez DVM

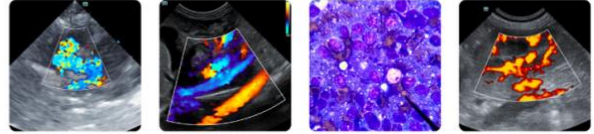
INVOICE

22733

DATE

3-25-26





PATIENT

Cholula Camacho

The information and recommendations provided are based on the images presented by the referring veterinarian/sonographer. No evaluation can be communicated regarding pathology that was not visible in the image/video clips provided.

SPECIES

Canine

Thank you for this referral. If the clinical or image interpretation does not parallel your findings or if I can be of any further assistance, please contact me.

BREED

German Shepherd

Andrea Nicastro, MPH, DVM, Diplomate DACVIM (Small Animal Internal Medicine)
info@SonoPath.com

SEX

Female Spayed

AGE

8

WEIGHT

69.8

INTERPRETED BY

Andrea Nicastro, DVM,
Diplomate ACVIM
(Small Animal Internal
Medicine)

IMAGING PERFORMED BY

Mario

HOSPITAL NAME

TLC Animal Hospital

REFERRING VET

Cristina Ramirez DVM

INVOICE

22733

DATE

3-25-26