

PATIENT

Nugget Byers

SPECIES

Canine

BREED

Chihuahua

SEX

Spayed Female

AGE

3/18/2013

WEIGHT

12 lb

INTERPRETED BY

Andrea Nicastro,
DVM, Diplomate
ACVIM (Small Animal
Internal Medicine)

IMAGING PERFORMED BY

Andrea Nicastro,
DVM, Diplomate
ACVIM (Small Animal
Internal Medicine)

HOSPITAL NAME

Vet. Dental Care

REFERRING VET

Dr. Susan Shanno

INVOICE

10608

DATE

3/25/22

PRESENTING CLINICAL SIGNS

Clinical Exam Findings:

Vomiting- 2-3 episodes since Tuesday. Still eating but very slowly. Tense abdomen. Ate double sided tape Monday. Found tape in vomit and stool. Stools are normal

Current Medications: none

Radiographic Findings: none

ULTRASONOGRAPHIC EXAMINATION OF THE ABDOMEN

Urinary System

The urinary bladder, trigone, and pelvic urethra are normal in thickness and the mucosal surface is smooth. The bladder lumen is moderately distended with anechoic urine. No masses, inflammatory changes or calculi are observed. Ureteral papillae and visualized portion of the proximal urethra, visible to a depth of 2 cm, are normal.

The left kidney presented normal size (3.87 cm in length); normal shape and architecture with smooth peripheral margins. There is a normal 1:3 cortex to medulla ratio with normal corticomedullary distinction. There is no evidence of pyelectasia, nephroliths, infarcts or hydronephrosis. Renal vasculature is normal.

The right kidney presented normal size (3.44 cm in length); normal shape and architecture with smooth peripheral margins. There is a normal 1:3 cortex to medulla ratio with normal corticomedullary distinction. There is no evidence of pyelectasia, nephroliths, infarcts or hydronephrosis. Renal vasculature is normal.

Adrenal Glands

The left adrenal gland is normal size (0.42 cm at cranial pole) (0.50 cm at caudal pole) (0.82 cm in length); normal shape; homogenous parenchyma. The glandular echogenicity and detail are unremarkable. Capsule, cortex, and medullary definition are normal. The phrenicoabdominal vein and surrounding vasculature are normal.

The right adrenal gland is normal size (0.56 cm at cranial pole) (0.45 cm at caudal pole) (0.58 cm in length); normal shape; homogenous parenchyma. The glandular echogenicity and detail are unremarkable. Capsule, cortex, and medullary definition are normal. The phrenicoabdominal vein and surrounding vasculature are normal.

Spleen

The spleen is normal in size (0.94 cm in width at the level of the hilus) with a normal capsular contour. There is appropriate echogenicity and echotexture. No focal lesions are observed. Splenic vasculature is normal.

Liver

The liver is subjectively normal in size with normal contours and structure. There is appropriate echogenicity and echotexture. No overt structural evidence of inflammatory, infiltrative or regenerative pathology is evident. Vascular and biliary tracts are of normal volume with no evidence of congestion. No pathological hepatic lymphadenopathy observed.

The gall bladder lumen is moderately distended. The wall is thin and smooth. Luminal contents are anechoic. The cystic and common bile ducts are normal.



PATIENT

Nugget Byers

SPECIES

Canine

BREED

Chihuahua

SEX

Spayed Female

AGE

3/18/2013

WEIGHT

12 lb

INTERPRETED BY

Andrea Nicastro,
DVM, Diplomate
ACVIM (Small Animal
Internal Medicine)

IMAGING PERFORMED BY

Andrea Nicastro,
DVM, Diplomate
ACVIM (Small Animal
Internal Medicine)

HOSPITAL NAME

Vet. Dental Care

REFERRING VET

Dr. Susan Shanno

INVOICE

10608

DATE

3/25/22

Gastrointestinal

The gastric lumen is distended with irregular, hard, shadowing foreign material. The gastric wall and pylorus are normal in thickness with a normal layering pattern. There is no obvious evidence of foreign material within the pyloric outflow tract at this time. The small intestinal lumen is segmentally dilated with chyme. The small intestinal wall thickness is normal with a normal layering pattern and appropriate mural detail. Discreet masses are not identified. The colonic wall is normal.

Pancreas

The region of the pancreas is isoechoic relative to surrounding omental fat. No obvious parenchymal abnormalities are observed. There is no evidence of regional inflammation or effusion.

Free Abdomen

The peritoneal cavity is normal. There is no evidence of inflammation or effusion. The abdominal lymph nodes are normal/not visible.

Other

A brief echocardiogram reveals no evidence of pericardial effusion.

ULTRASONOGRAPHIC FINDINGS

Primary Findings

- Gastric foreign material. Given patient history, tape ingestion fits with sonograph changes.

INTERPRETATION OF THE FINDINGS & FURTHER RECOMMENDATIONS

- A gastrotomy with removal of the foreign material is recommended. Just prior to surgery, check the stomach via ultrasound, if possible, to ensure that the material is still in the stomach.



PATIENT

Nugget Byers

SPECIES

Canine

BREED

Chihuahua

SEX

Spayed Female

AGE

3/18/2013

WEIGHT

12 lb

INTERPRETED BY

Andrea Nicastro,
DVM, Diplomate
ACVIM (Small Animal
Internal Medicine)

IMAGING PERFORMED BY

Andrea Nicastro,
DVM, Diplomate
ACVIM (Small Animal
Internal Medicine)

HOSPITAL NAME

Vet. Dental Care

REFERRING VET

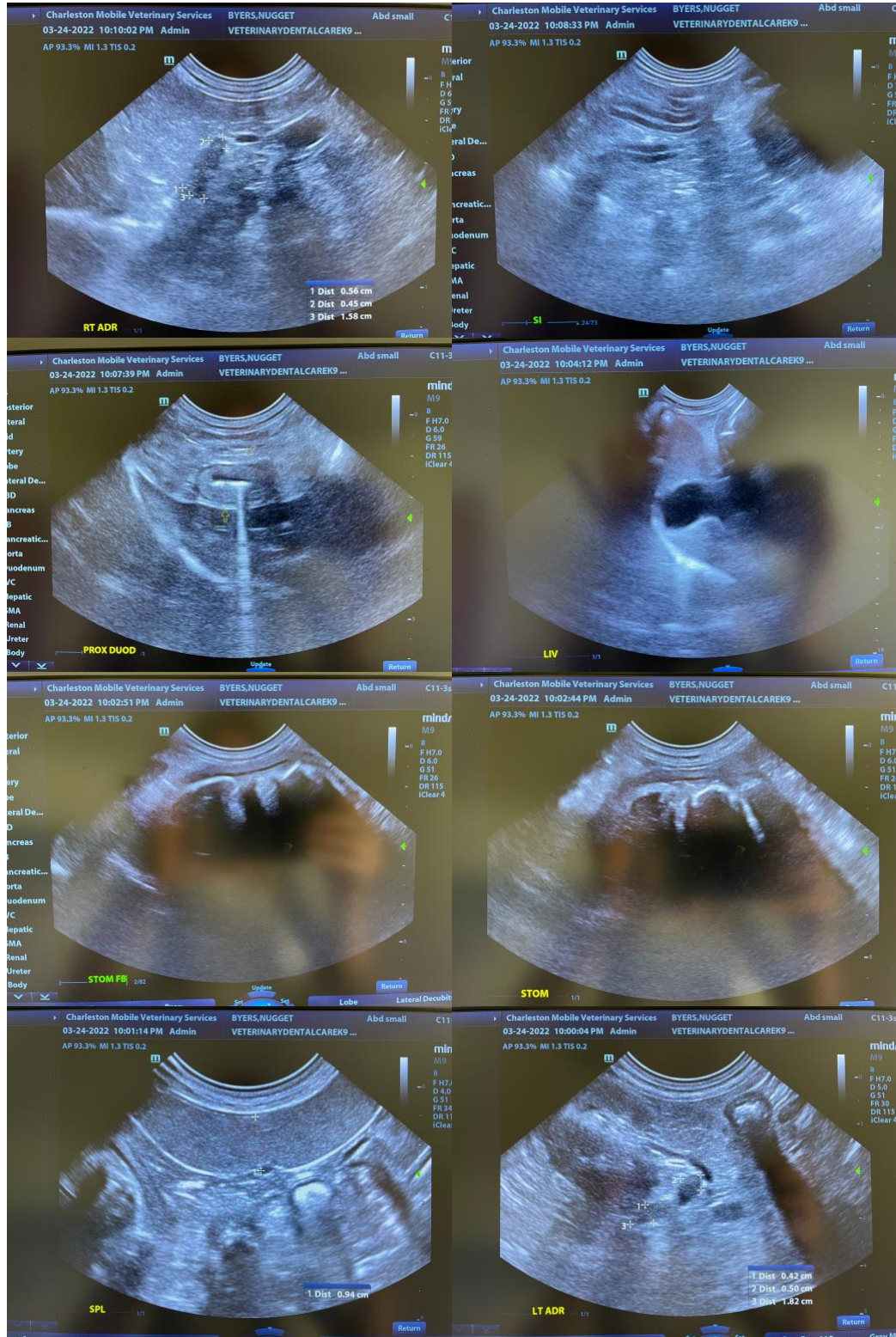
Dr. Susan Shanno

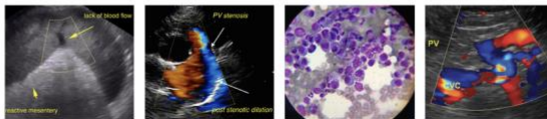
INVOICE

10608

DATE

3/25/22





PATIENT

Nugget Byers

The information and recommendations provided are based on the images presented by the referring veterinarian/sonographer. No evaluation can be communicated regarding pathology that was not visible in the image/video clips provided.

SPECIES

Canine

Thank you for this referral. If the clinical or image interpretation does not parallel your findings or if I can be of any further assistance, please contact me.

BREED

Chihuahua

Andrea Nicastro, DVM, Diplomate DACVIM (Small Animal Internal Medicine)
info@SonoPath.com

SEX

Spayed Female

AGE

3/18/2013

WEIGHT

12 lb

INTERPRETED BY

Andrea Nicastro,
DVM, Diplomate
ACVIM (Small Animal
Internal Medicine)

IMAGING PERFORMED BY

Andrea Nicastro,
DVM, Diplomate
ACVIM (Small Animal
Internal Medicine)

HOSPITAL NAME

Vet. Dental Care

REFERRING VET

Dr. Susan Shanno

INVOICE

10608

DATE

3/25/22