



PATIENT PRESENTING CLINICAL SIGNS

Keey Swearingen Clinical Exam Findings: BAR. slightly overweight- has gained 1/2# since last visit (11/16/2022). oral- heavy tartar, grade 2 dental disease. pink mm. e/e/n wnl. c/s wnl. normal mentation and ambulation. abdo palp wnl.

SPECIES

Canine

Abnormal lab-work values:

On 3/17/23: ALB 2.1 g/dL

On 3/10/23: ALB 1.9 g/dL

BREED

Jack Russel Terrier

UA was clear of UTI and had good SG, but slight protein.

Emailing a copy of the records.

Current Medications: Trazodone 50mg

ULTRASONOGRAPHIC EXAMINATION OF THE ABDOMEN

SEX

Female Spayed

Urinary System

The urinary bladder wall is normal in thickness and the mucosal surface is smooth. The bladder is moderately distended. Luminal contents are anechoic. No cystic calculi are observed. The region of the trigone and the proximal urethra, visible to a depth of 2 cm, are normal.

AGE

12/12/2017

The left kidney is normal in size (3.73 cm in length) with a normal shape, architecture and smooth peripheral margins. There is a normal 1:3 cortex to medulla ratio with normal corticomedullary distinction. There is no evidence of pyelectasia, nephroliths, infarcts or hydronephrosis. Renal vasculature is normal.

WEIGHT

16 lbs

The right kidney is normal in size (4.34 cm in length) with a normal shape, architecture and smooth peripheral margins. There is a normal 1:3 cortex to medulla ratio with normal corticomedullary distinction. There is no evidence of pyelectasia, nephroliths, infarcts or hydronephrosis. Renal vasculature is normal.

INTERPRETED BY

Andrea Nicastro, DVM,
Diplomate ACVIM (*Small
Animal Internal Medicine*)

Adrenal Glands

The left adrenal gland is normal in size (0.33 cm at cranial pole) (0.36 cm at caudal pole) with a normal shape and homogenous parenchyma. The glandular echogenicity and detail are unremarkable. Capsule, cortex, and medullary definition are normal. The phrenicoabdominal vein and surrounding vasculature are normal.

IMAGING PERFORMED BY

Andrea Nicastro, DVM,
Diplomate ACVIM (*Small
Animal Internal Medicine*)

The right adrenal gland is in normal size (1.14 cm at cranial pole) (0.49 cm at caudal pole) with a normal shape and homogenous parenchyma. The glandular echogenicity and detail are unremarkable. Capsule, cortex, and medullary definition are normal. The phrenicoabdominal vein and surrounding vasculature are normal.

HOSPITAL NAME

West Ashley VC

Spleen

The spleen is normal in size (1.42 cm in width at the level of the hilus) with a normal capsular contour. There is appropriate echogenicity and echotexture. No focal lesions are observed. Splenic vasculature is normal.

REFERRING VET

Dr. Grayson Hudgins

Liver

The liver is subjectively normal in size with normal contours and structure. There is appropriate echogenicity and echotexture. No overt structural evidence of inflammatory, infiltrative, or regenerative pathology is evident. Vascular and biliary tracts are of normal volume with no evidence of congestion. No pathological hepatic lymphadenopathy observed. The portal vein to caudal vena cava ratio is approximately 1: 1.

INVOICE

12494

The gall bladder is of normal contours and contains some dependent echogenic debris. The wall is normal in thickness. No choleliths are observed. The cystic and common bile ducts are normal/not seen.

DATE

3.24.23

Gastrointestinal

The gastric lumen is not distended. The gastric wall and pylorus are normal in thickness with a normal layering pattern. The pyloric outflow tract is patent. The small intestinal lumen is not dilated. The small intestinal wall is diffusely thickened (up to 0.40 cm) with retention of the normal layering pattern. There is evidence of mucosal fogging in several segments. Discreet masses are not identified. The colonic wall is normal. There is no evidence of an obstructive pattern.

Pancreas

The right limb of the pancreas is visible with normal curvilinear peripheral contours. The parenchyma is largely isoechoic relative to surrounding omental fat and slightly mottled in appearance. The pancreatic duct is visible but not overtly dilated. There is no evidence of peripancreatic inflammation or effusion.

Free Abdomen

Trace free fluid is observed. The abdominal lymph nodes are normal/not visible.

Other

A brief echocardiogram reveals no evidence of pericardial effusion or obvious right atrial/auricular mass.

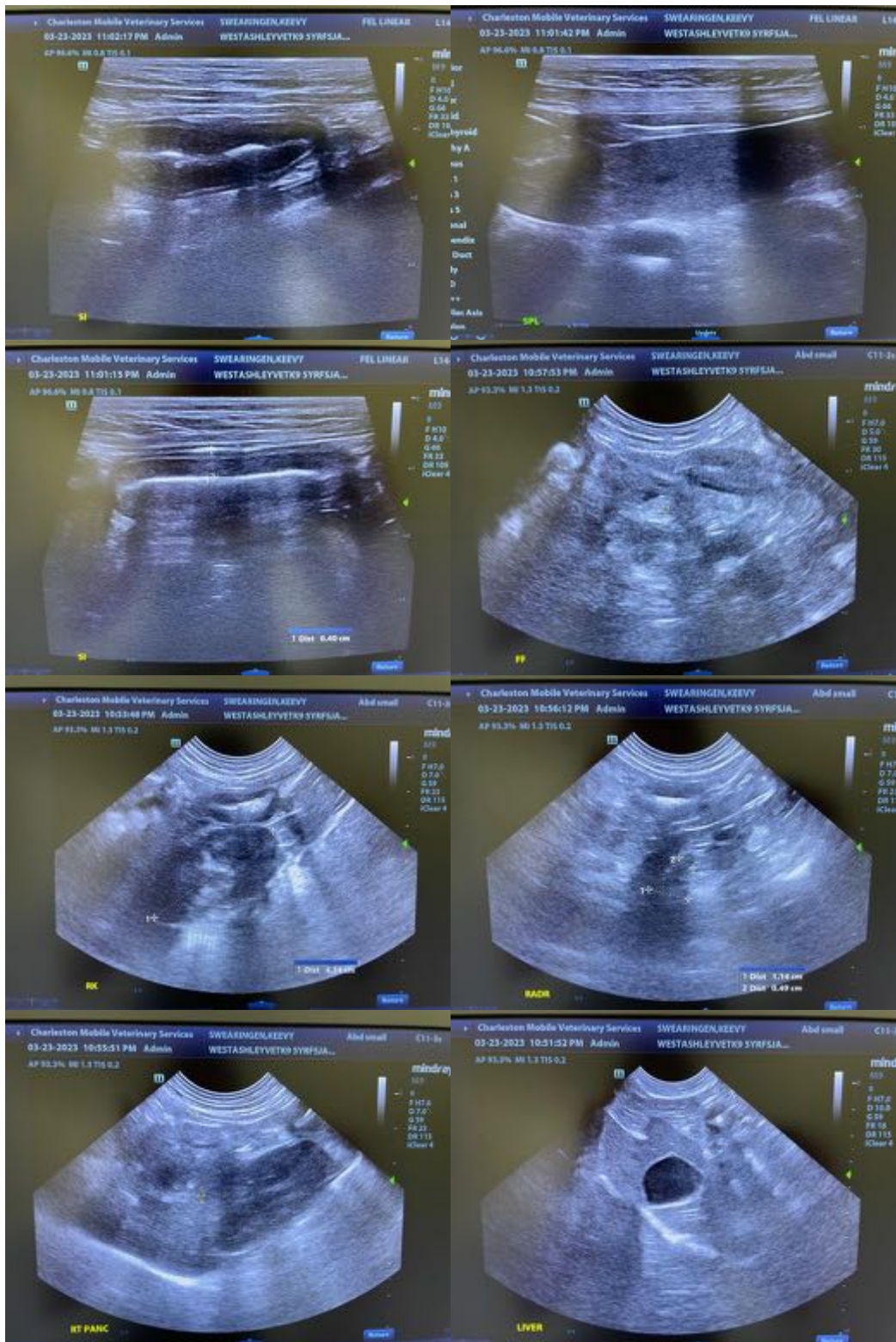
ULTRASONOGRAPHIC FINDINGS

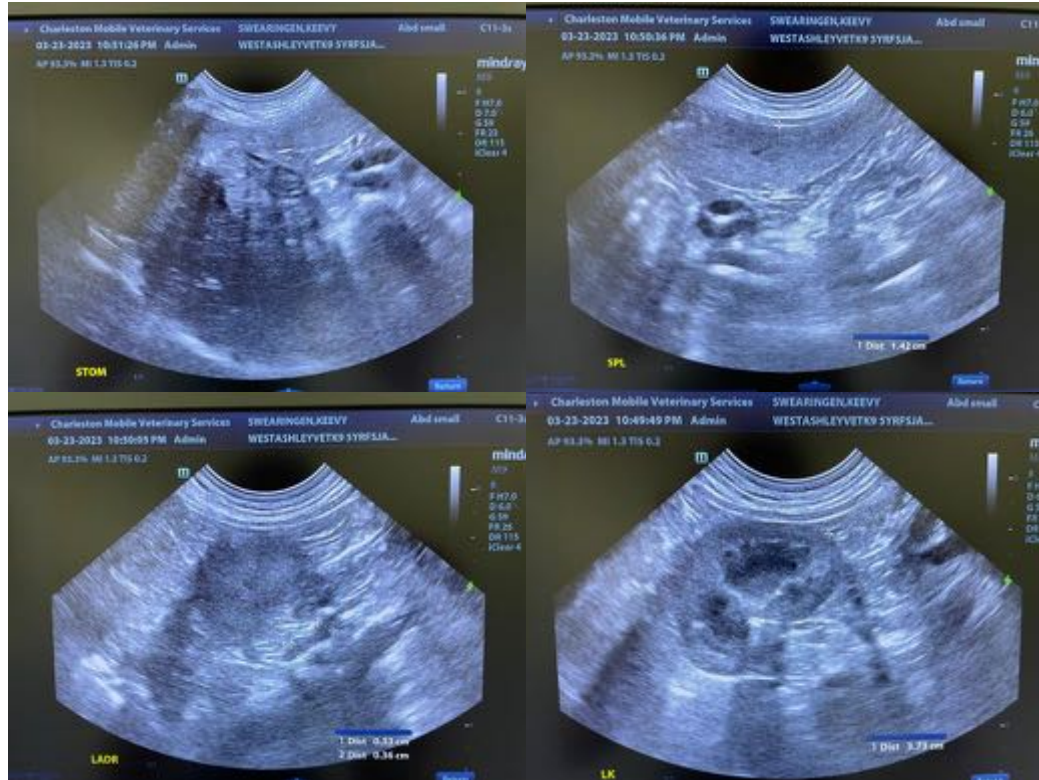
Findings

- Given the patient's clinical history and sonographic changes, a protein-losing enteropathy is suspected. Top differentials include inflammatory bowel disease, lymphangiectasia and infectious/parasitic disease, with a lower possibility of infiltrative neoplasia (i.e., lymphoma), fungal infection, or other enteropathies.
- The trace ascites is likely secondary to hypoalbuminemia and/or bowel pathology.

INTERPRETATION OF THE FINDINGS & FURTHER RECOMMENDATIONS

- Fecal evaluation for ova and Giardia (if not already performed).
- A malabsorption panel, including serum cobalamin and folate, TLI, PLI and resting cortisol level is recommended (send to Texas A&M).
- A UPC and serum bile acids should also be considered to rule out other causes of hypoalbuminemia.
- Consider initiation of a low-fat, hypoallergenic diet.
- Depending on the results of the above diagnostics, GI biopsies may be necessary to get a definitive diagnosis. If biopsies are not pursued, diet and corticosteroids can be used as empirical treatment for lymphangiectasia/inflammatory bowel disease (as long as the client understands the risks of treatment without a definitive diagnosis).





The information and recommendations provided are based on the images presented by the referring veterinarian/sonographer. No evaluation can be communicated regarding pathology that was not visible in the image/video clips provided.

Thank you for this referral. If the clinical or image interpretation does not parallel your findings or if I can be of any further assistance, please contact me.

Andrea Nicastro, MPH, DVM, Diplomate DACVIM (Small Animal Internal Medicine)
info@SonoPath.com