



PATIENT

Harley Kugle

SPECIES

Canine

BREED

Pitbull mix

SEX

Female, spayed

AGE

7 Yrs.

WEIGHT

57.6 lbs.

INTERPRETED BY

Andrea Nicastro, DVM,
Diplomate ACVIM
(Small Animal Internal
Medicine)

IMAGING PERFORMED BY

Kevin Moon, DVM

HOSPITAL NAME

Shiloh VH

REFERRING VET

Dr. Onstott

INVOICE

13625

DATE

3/23/26

PRESENTING CLINICAL SIGNS

History:

- BCS 6/9
 - P had surgery 2/20 for 2 growth removals: R axilla & R lower lip. The U/S pertains to the R lower lip: ~1/2 cm round, textured, pigmented mass (first noted 1/13). It was surgically excised with minimal margins and submitted for bx. Bx for oral mass returned as oral melanoma
- Abnormal PE/Chem/CBC/UA Results: Pre-op CBC/Chem/T4/UA normal

ULTRASONOGRAPHIC EXAMINATION OF THE ABDOMEN

Urinary System

The urinary bladder wall is normal in thickness and the mucosal surface is smooth. The bladder is moderately distended. Luminal contents are mostly anechoic. No cystic calculi are observed. The region of the trigone and the visible portion of the proximal urethra are normal.

The cranial portion of the prostate is visualized and is normal in size (1.44 cm in width) with smooth peripheral contours. The parenchyma is homogeneous. The prostatic urethra is not overtly dilated.

The left kidney is normal in size (6.51 cm in length) with a normal shape, architecture and smooth peripheral margins. There is a normal 1:3 cortex to medulla ratio with minimal loss of corticomedullary distinction. There is no evidence of pyelectasia, nephroliths, infarcts or hydroureter. Renal vasculature is normal.

The right kidney is normal in size (7.17 cm in length) with a normal shape, architecture and smooth peripheral margins. There is a normal 1:3 cortex to medulla ratio with minimal loss of corticomedullary distinction. There is no evidence of pyelectasia, nephroliths, infarcts or hydroureter. Renal vasculature is normal.

Adrenal Glands

The left adrenal gland is normal in size (0.48 cm at cranial pole) (0.47 cm at caudal pole) with a normal shape and homogenous parenchyma. The glandular echogenicity and detail are unremarkable. Capsule, cortex, and medullary definition are normal. The phrenicoabdominal vein and surrounding vasculature are normal.

The caudal pole of the right adrenal gland is visualized and is normal in size (0.67 cm in width) with a normal shape, glandular echogenicity and detail. Surrounding vasculature appears normal.

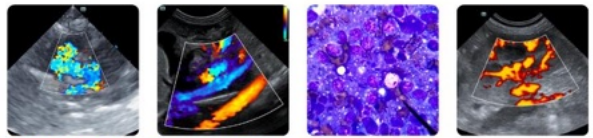
Spleen

The spleen is subjectively normal in size with a normal capsular contour. There is appropriate echogenicity and echotexture. No focal lesions are observed. Splenic vasculature is normal.

Liver

The liver is subjectively normal in size with normal contours and structure. There is appropriate echogenicity and echotexture. No overt structural evidence of inflammatory, infiltrative, or regenerative pathology is evident. Vascular and biliary tracts are of normal volume with no evidence of congestion.

The gall bladder lumen is moderately distended. The wall is thin and smooth. Luminal contents are mostly anechoic. The cystic and common bile ducts are normal/not seen.



PATIENT

Harley Kugle

SPECIES

Canine

BREED

Pitbull mix

SEX

Female, spayed

AGE

7 Yrs.

WEIGHT

57.6 lbs.

INTERPRETED BY

Andrea Nicastro, DVM,
Diplomate ACVIM
(Small Animal Internal
Medicine)

IMAGING PERFORMED BY

Kevin Moon, DVM

HOSPITAL NAME

Shiloh VH

REFERRING VET

Dr. Onstott

INVOICE

13625

DATE

3/23/26

Gastrointestinal

The gastric lumen is not distended. The gastric wall is normal in thickness with a normal layering pattern. The small intestinal lumen is not dilated. The small intestinal wall thickness is normal with a normal layering pattern and appropriate mural detail. Discreet masses are not identified. The colonic wall is normal. There is no evidence of an obstructive pattern.

Pancreas

The region of the pancreas is isoechoic relative to surrounding omental fat. No obvious parenchymal abnormalities are observed. There is no evidence of regional inflammation or effusion.

Lymph nodes

The abdominal lymph nodes are normal/not visible.

Free Abdomen

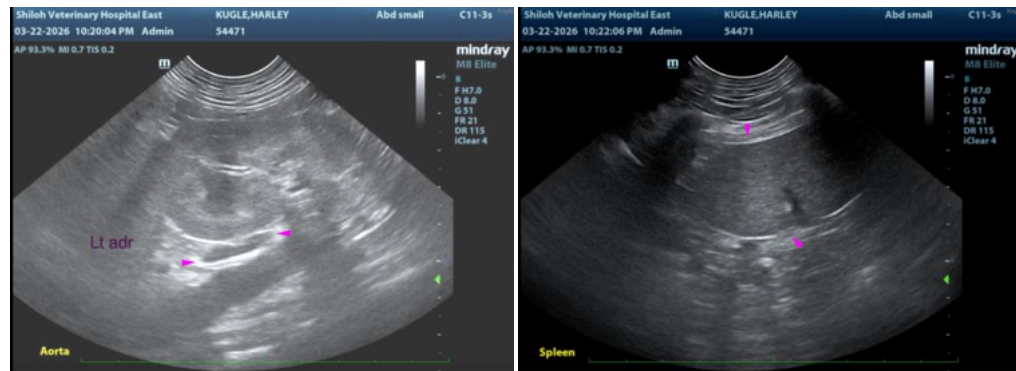
The peritoneal cavity is normal. There is no evidence of inflammation or effusion.

ULTRASONOGRAPHIC FINDINGS

Structurally unremarkable abdomen. There is no obvious evidence of metastatic disease on today's study.

INTERPRETATION OF THE FINDINGS & FURTHER RECOMMENDATIONS

1. Three-view thoracic radiographs are recommended to assess for pulmonary metastases.
2. Consider consultation with a board-certified oncologist for further recommendations.





PATIENT

Harley Kugle

SPECIES

Canine

BREED

Pitbull mix

SEX

Female, spayed

AGE

7 Yrs.

WEIGHT

57.6 lbs.

INTERPRETED BY

Andrea Nicastro, DVM,
Diplomate ACVIM
(Small Animal Internal
Medicine)

IMAGING PERFORMED BY

Kevin Moon, DVM

HOSPITAL NAME

Shiloh VH

REFERRING VET

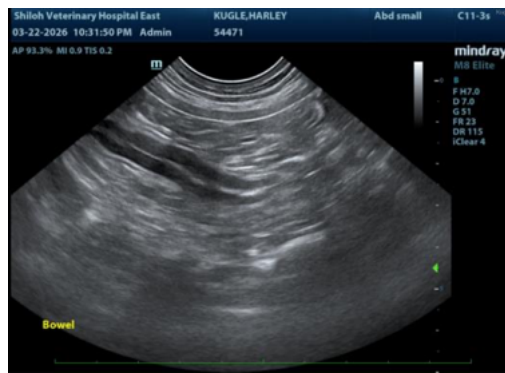
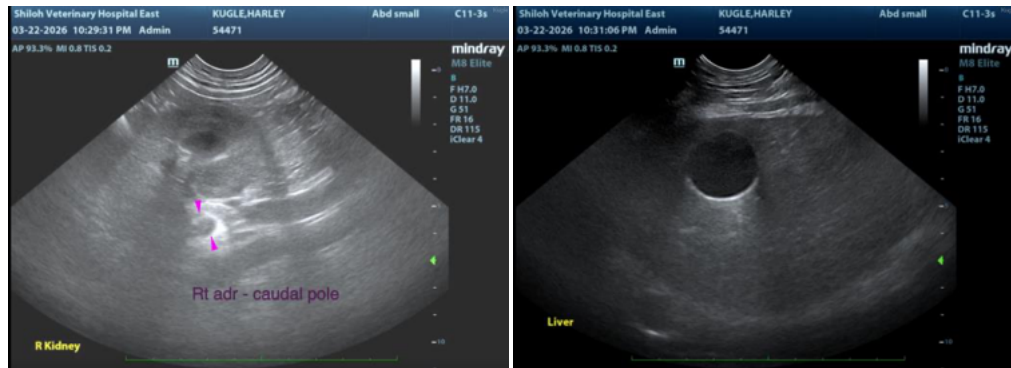
Dr. Onstott

INVOICE

13625

DATE

3/23/26



The information and recommendations provided are based on the images presented by the referring veterinarian/sonographer. No evaluation can be communicated regarding pathology that was not visible in the image/video clips provided.

Thank you for this referral. If the clinical or image interpretation does not parallel your findings or if I can be of any further assistance please contact me.

Andrea Nicastro, MPH, DVM, Diplomate DACVIM (Small Animal Internal Medicine)
info@SonoPath.com