



PATIENT PRESENTING CLINICAL SIGNS

Oak Rain History: Diagnosed with diabetes mellites 2-3 weeks ago. Is still PU/PD despite increasing the insulin dose. Is currently on 11 units of Vetsulin twice a day. Blood glucose is still high. No vomiting or diarrhea. Voracious appetite.

SPECIES

Recent lab-work results not available.

Canine

ULTRASONOGRAPHIC EXAMINATION OF THE ABDOMEN

BREED

Urinary System

Labradoodle

The urinary bladder is mildly distended. The wall is diffusely thickened (up to 0.58 cm) with a slightly irregular mucosal surface. A scant amount of suspended echogenic debris is observed within the lumen. No cystic calculi are observed. The region of the trigone and the proximal urethra, visible to a depth of 2 cm, are normal.

SEX

Neutered Male

The prostate is normal in size (1.29 cm in width) and shape. Parenchyma is homogenous. The prostatic urethra appears normal without evidence of dilation or obstruction.

AGE

12/3/2012

The left kidney is normal in size (7.14 cm in length) with a normal shape, architecture and smooth peripheral margins. There is a normal 1:3 cortex to medulla ratio with mild loss of corticomedullary distinction. A thin hyperechoic medullary band is observed at the corticomedullary junction. The cortex is isoechoic relative to the spleen. There is no evidence of pyelectasia, nephroliths, infarcts or hydroureter. Renal vasculature is normal.

WEIGHT

46 lbs

The right kidney is normal in size (7.22 cm in length) with a normal shape, architecture and smooth peripheral margins. There is a normal 1:3 cortex to medulla ratio with mild loss of corticomedullary distinction. A thin hyperechoic medullary band is observed at the corticomedullary junction. The cortex is isoechoic relative to the spleen. There is no evidence of pyelectasia, nephroliths, infarcts or hydroureter. Renal vasculature is normal.

INTERPRETED BY

Andrea Nicastro, DVM,
Diplomate ACVIM (*Small Animal Internal Medicine*)

Adrenal Glands

The left adrenal gland is enlarged at the cranial pole (1.49 cm) and normal in size at the caudal pole (0.64 cm) (2.15 cm in length). A 2.15 x 1.49 cm hyperechoic nodule is observed at the cranial aspect. Glandular echogenicity and detail at the caudal aspect are normal. The phrenicoabdominal vein and surrounding vasculature are normal.

IMAGING PERFORMED BY

Andrea Nicastro, DVM,
Diplomate ACVIM (*Small Animal Internal Medicine*)

The right adrenal gland is in normal size (1.32 cm at cranial pole) (0.66 cm at caudal pole) with a normal shape and homogenous parenchyma. The glandular echogenicity and detail are unremarkable. Capsule, cortex, and medullary definition are normal. The phrenicoabdominal vein and surrounding vasculature are normal.

HOSPITAL NAME

Trinity Island VC

Spleen

The spleen is normal in size (1.25 cm in width at the level of the hilus) with a normal capsular contour. There is appropriate echogenicity and echotexture. No focal lesions are observed. Splenic vasculature is normal.

REFERRING VET

Kristi Oldham, DVM

Liver

The liver is subjectively enlarged with swollen peripheral contours. The parenchyma is hyperechoic relative to the spleen and attenuating. No distinct focal lesions are observed. Hepatic vasculature and intrahepatic biliary tracts are of normal volume with no evidence of congestion. The portal vein to caudal vena cava ratio is approximately 1: 1.

INVOICE

12476

DATE

3.23.23

The gall bladder lumen is moderately distended. The wall is thin and smooth. A moderate amount of aggregated, echogenic, mostly gravity-dependent debris/sludge is observed within the lumen. The cystic and common bile ducts are normal/not seen.

Gastrointestinal

The stomach and intestine are free of stasis and exhibit normal peristaltic activity. The gastric lumen is mildly distended with ingesta. The gastric wall and pylorus are normal in thickness with a normal layering pattern. The pyloric outflow tract is patent. The small intestinal lumen is segmentally dilated with chyme. The small intestinal wall is normal in thickness with a normal layering pattern and appropriate mural detail. Discreet masses are not identified. The colonic wall is normal. There is no evidence of an obstructive pattern.

Pancreas

The right limb is prominent in size with minimal deviation from the normal peripheral contours. The parenchyma is slightly hypoechoic relative to surrounding omental fat. No distinct focal lesions are observed. The pancreatic duct is not overtly dilated.

Free Abdomen

The peritoneal cavity is normal. There is no evidence of inflammation or effusion. The abdominal lymph nodes are normal/not visible.

Other

A brief echocardiogram reveals no evidence of pericardial effusion or obvious right atrial/auricular mass.

ULTRASONOGRAPHIC FINDINGS

Primary Findings

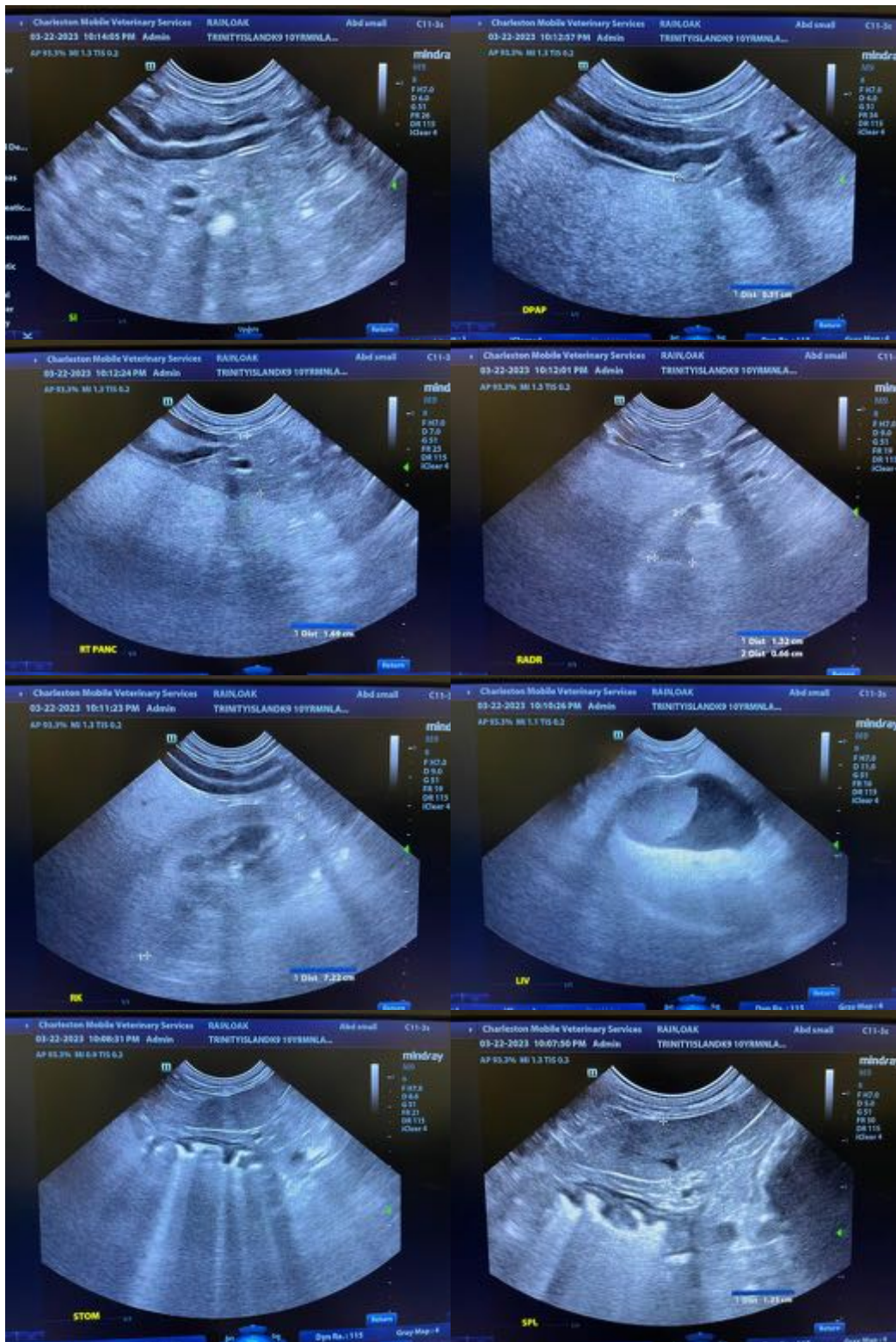
- The left adrenal nodule could be consistent with benign macronodular hyperplasia or an emerging tumor (adenoma, adenocarcinoma, pheochromocytoma).
- The hepatic parenchymal changes are most consistent with diabetic hepatopathy. Other differentials include inflammatory disease or less likely, infiltrative neoplasia. Correlation with the patient's liver values is recommended.
- Gall bladder sludge – non-mucocele

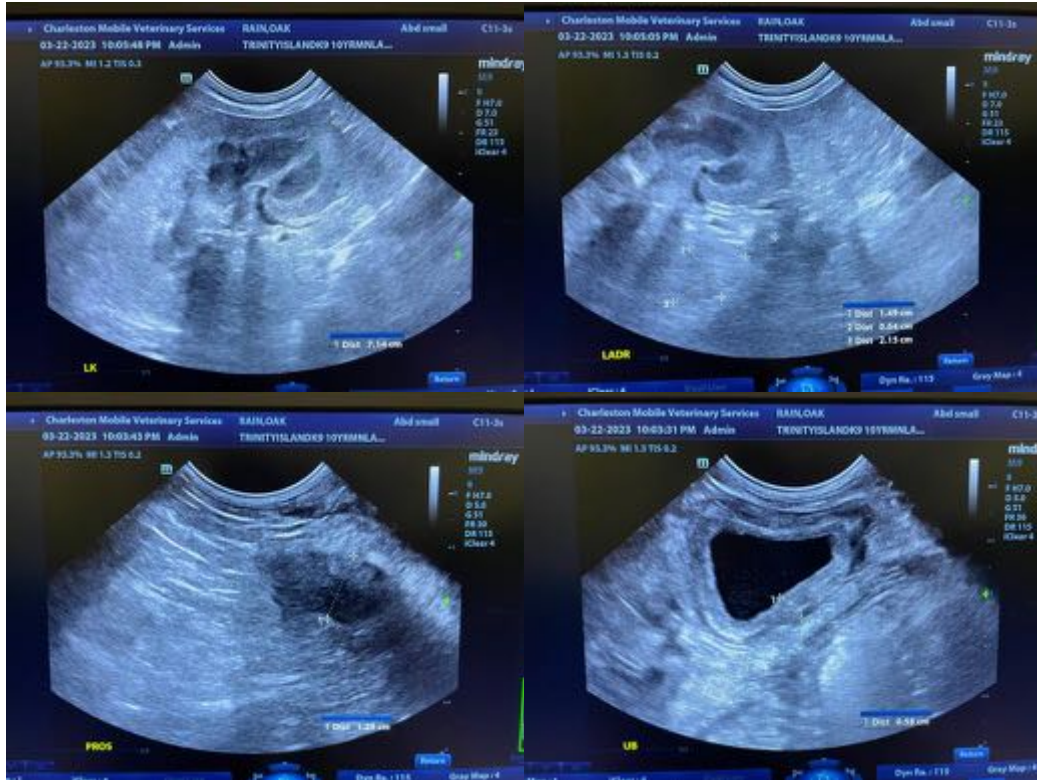
Secondary Findings

- The bilateral renal changes are most consistent with a diabetic nephropathy.
- The pancreatic changes may be a normal variant for this patient or could be consistent with mild, chronic pancreatitis. Correlation with clinical findings is recommended.

INTERPRETATION OF THE FINDINGS & FURTHER RECOMMENDATIONS

- Baseline lab work (including a CBC, chemistry panel, urinalysis, T4 and urine culture and sensitivity) is recommended. Depending on these results, additional diagnostics and/or treatments may be warranted.
- Consider increasing the patient's insulin dose by two units, and then performing a blood glucose curve in 7-10 days. Further adjustments in insulin dose should be based on the glucose curve results.





The information and recommendations provided are based on the images presented by the referring veterinarian/sonographer. No evaluation can be communicated regarding pathology that was not visible in the image/video clips provided.

Thank you for this referral. If the clinical or image interpretation does not parallel your findings or if I can be of any further assistance, please contact me.

Andrea Nicastro, MPH, DVM, Diplomate DACVIM (Small Animal Internal Medicine)
info@SonoPath.com