**DATE PRESENTING CLINICAL SIGNS**

3.23.23 Presented for worsening lethargy today. Tested POS on routine 4DX last week for Anaplasmosis. Previous sarcoma removed in 2021.

PATIENT

Copenhagen
Bethman

Current Medications: None.
 Lab Results: In house labs HCT 30%; WBC 20.98 (High).
 Date of Previous IntraPet Ultrasound: 9/22/21 attached.
 Sedation: Not required to complete full diagnostic ultrasound.
 Stat Report: Requested/Approved.
 Imaging Performed By: Stephanie Pearce, RDCS, RVT.

SPECIES

Canine

ULTRASONOGRAPHIC EXAMINATION OF THE ABDOMEN**BREED**

Portug Water Dog

Urinary System

The urinary bladder and visible portion of the pelvic urethra are normal for the degree of luminal distension. The urine is anechoic with no evidence of debris. Cystic calculi and discrete masses are not observed. The region of the trigone and visible portion of the proximal urethra are normal.

SEX

Neutered Male

The region of the prostate is not visualized due to its pelvic location.

AGE

11-7-11

The left kidney is normal in size (6.52 cm in length) with a normal shape, architecture and smooth peripheral margins. There is a normal 1:3 cortex to medulla ratio with mild to moderate loss of corticomedullary distinction. The cortex is isoechoic relative to the spleen. A small cortical cyst is seen. There is no evidence of pyelectasia, nephroliths, infarcts or hydroureter. Renal vasculature is normal.

WEIGHT

70.2 lbs

The right kidney is normal in size (6.34 cm in length) with a normal shape, architecture and smooth peripheral margins. There is a normal 1:3 cortex to medulla ratio with mild to moderate loss of corticomedullary distinction. The cortex is isoechoic relative to the spleen. There is no evidence of pyelectasia, nephroliths, infarcts or hydroureter. Renal vasculature is normal.

INTERPRETED BY

Andrea Nicastro, DMV,
Diplomate DACVIM
(Small Animal
Internal Medicine)

Adrenal Glands

The left adrenal gland is normal in size (0.79 cm at cranial pole) (0.75 cm at caudal pole) (3.37 cm in length) with a normal shape and homogenous parenchyma. The glandular echogenicity and detail are unremarkable. Capsule, cortex, and medullary definition are normal. The phrenicoabdominal vein and surrounding vasculature are normal.

HOSPITAL NAME

Frederick Road VH

The right adrenal gland is in normal size (0.77 cm at cranial pole) (0.82 cm at caudal pole) (3.68 cm in length) with a normal shape and homogenous parenchyma. The glandular echogenicity and detail are unremarkable. Capsule, cortex, and medullary definition are normal. The phrenicoabdominal vein and surrounding vasculature are normal.

REFERRING VET

Dr. Cannon

Spleen

The spleen is overall normal in size with swelling at the head of the spleen. An approximately 2.42 cm isoechoic-to-slightly-heterogenous, ill-defined nodule/mass is observed at the head of the spleen. The lesion causes mild capsular swelling. The remaining parenchyma is homogenous. Splenic vasculature is normal with no evidence of thrombosis.

INVOICE

3.23.23

Liver

The liver is subjectively normal in size with irregular peripheral contours. Numerous, varying-sized nodules/masses are observed throughout the organ (the largest measuring 3.53 cm). Several of the lesions cause capsular expansion. Some of the lesions are hyperechoic with hypoechoic-to-cavitated centers. Other

lesions are hypoechoic-to-cavitated. Hepatic vasculature and intrahepatic biliary tracts are of normal volume with no evidence of congestion.

The gall bladder lumen is mildly to moderately distended. The wall is thin and smooth. A small amount of suspended echogenic debris is observed within the lumen. The cystic and common bile ducts are normal/not seen.

Gastrointestinal

The lumen is not distended. The gastric wall is normal in thickness with a normal layering pattern. The small intestinal lumen is not dilated. The small intestinal wall thickness is normal with a normal layering pattern and appropriate mural detail. Discreet masses are not identified. The colonic wall is normal. There is no evidence of an obstructive pattern.

Pancreas

The region of the pancreas is isoechoic relative to surrounding omental fat. No obvious parenchymal abnormalities are observed. There is no evidence of regional inflammation or effusion.

Free Abdomen

The mesentery in the cranial-to-midabdominal is hyperechoic. A small to moderate amount of free fluid is present. The abdominal lymph nodes are normal/not visible.

Other

A brief echocardiogram reveals no evidence of pericardial effusion or obvious right atrial/auricular mass.

ULTRASONOGRAPHIC FINDINGS

Primary Findings

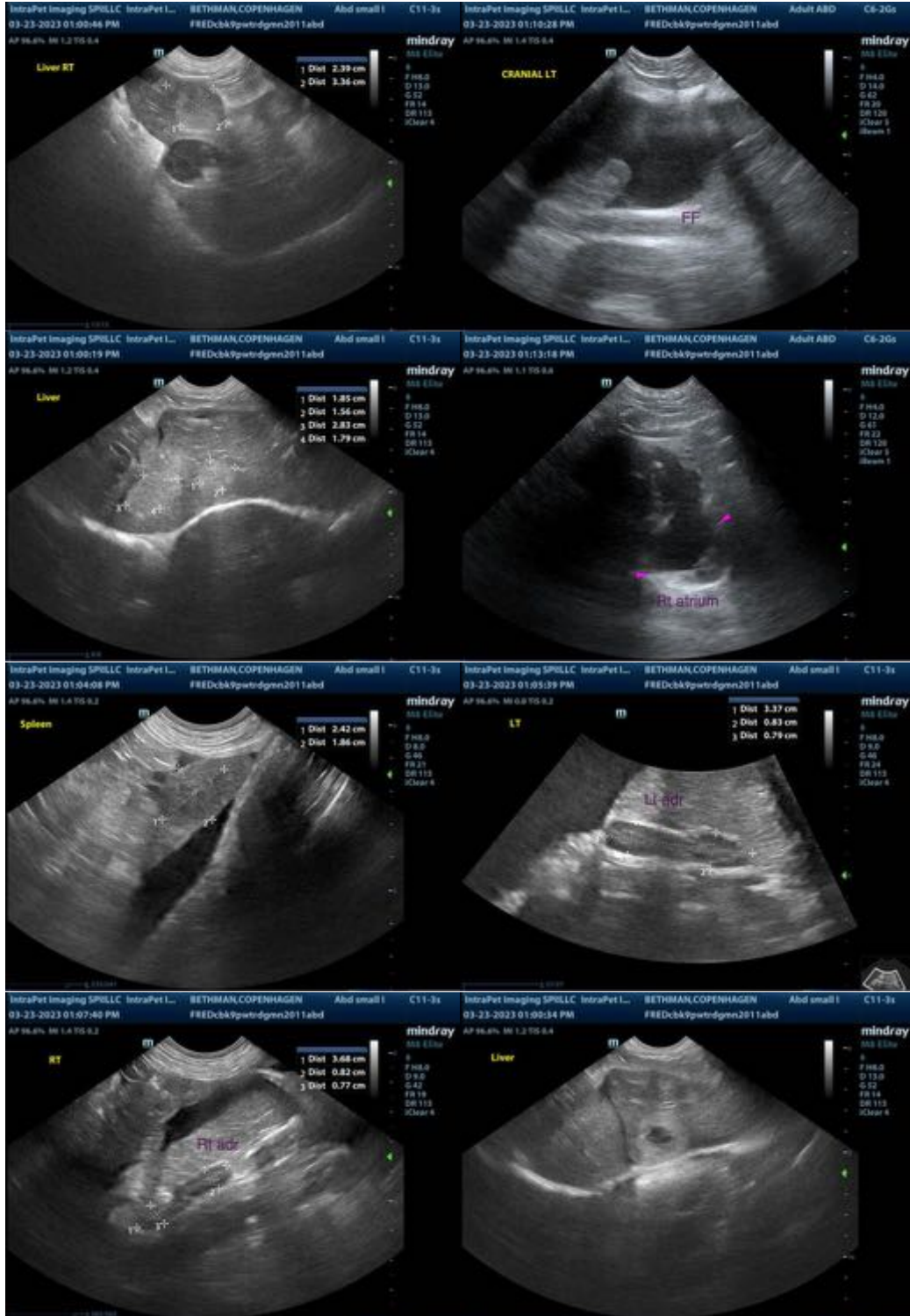
- The hepatic nodules/masses are concerning for a neoplastic process (i.e., hemangiosarcoma, adenocarcinoma, round cell neoplasia) with a lower possibility of a multifocal inflammatory process.
- The splenic nodule/mass could be consistent with a metastatic disease lesion or a focal benign process (i.e., extramedullary hematopoiesis, lymphoid hyperplasia, or similar).
- Ascites, likely secondary to hepatic pathology

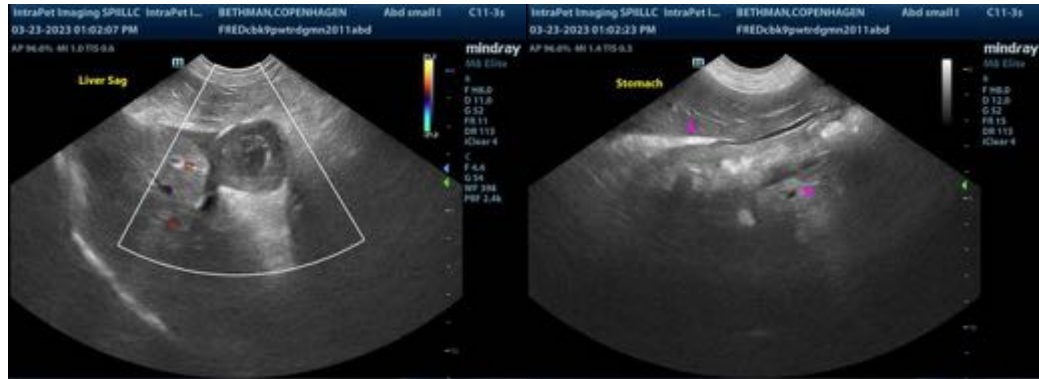
Secondary Findings

- Bilateral chronic age-related renal changes

INTERPRETATION OF THE FINDINGS & FURTHER RECOMMENDATIONS

- Three-view thoracic radiographs are recommended to assess for pulmonary metastases.
- If an aggressive approach is desired, consider fine-needle aspirates of the hepatic and splenic lesions (if clotting status is appropriate). Twenty-five gauge-needles should be used.
- Also consider cytology evaluation and PCV assessment of the abdominal fluid.
- Given the guarded prognosis for this patient, palliative care (i.e., Yunnan Bayaio, symptomatic treatment) should be considered in lieu of aggressive diagnostics/treatments.





The information and recommendations provided are based on the images presented by the referring veterinarian/sonographer. No evaluation can be communicated regarding pathology that was not visible in the image/video clips provided.

Thank you for this referral. If the clinical or image interpretation does not parallel your findings or if I can be of any further assistance, please contact me.

Andrea Nicastro, MPH, DVM, Diplomate DACVIM (Small Animal Internal Medicine)
info@SonoPath.com