

**PATIENT**

Sebastian Breit

**PRESENTING CLINICAL SIGNS****SPECIES**

Feline

**BREED**

DSH

**SEX**

Neutered Male

History: Patient History (required): Sebastian a 14y 7m, CM, Domestic Short Hair (Feline) has a jejunal mass suspect of intestinal lymphoma that was identified on 2/11/22 via ultrasound at his rDVM. Clinically he has been lethargic, and uncomfortable in his abdomen since approximately November 2021. In February 2022, he developed v/d with a very foul odor. Was started on Prednisone and Metronidazole since February - his diarrhea has improved significantly, and he is no longer vomiting. His appetite has been fairly low despite medication. His energy is still low. Current Medications: Prednisone 3mg/ml - 1 ml PO SID dislikes this Metronidazole 250mg - 1/4 t PO SID Comfort Plus BID Relevant Exam/labs/imaging results/treatments: 1/27/22: CBC: RBC 5.69 (L); Retic 102k (H); Chem: TP and ALB decreased; Spec fPL - 3.8. 2/11/22 AUS report: 1. Enteropathy/ diffuse intestinal thickening- ddx: IBD vs. small cell GI lymphoma vs. high grade lymphoma vs. other; 2. Focal jejunal mass; 3. Splenomegaly ; 4. Abdominal lymphadenopathy

**ULTRASONOGRAPHIC EXAMINATION OF THE ABDOMEN****AGE**

14 years

**Urinary System**

The urinary bladder, trigone, and pelvic urethra are normal in thickness and the mucosal surface is smooth. The bladder lumen is moderately distended. A scant amount of suspended echogenic debris is observed within the lumen. No masses, inflammatory changes or calculi are observed. Ureteral papillae and visualized portion of the proximal urethra, visible to a depth of 2 cm, are normal.

**WEIGHT**

10.1 lbs

The left kidney is normal size (3.56 cm in length); normal shape and architecture with smooth peripheral margins. There is a normal 1:3 cortex to medulla ratio with minimal to mild loss of corticomedullary distinction. There is no evidence of pyelectasia, nephroliths, infarcts or hydronephrosis.

**INTERPRETED BY**

Andrea Nicastro, DVM,  
Diplomate ACVIM (Small  
Animal Internal Medicine)

The right kidney is normal size (3.64 cm in length); normal shape and architecture with smooth peripheral margins. There is a normal 1:3 cortex to medulla ratio with normal corticomedullary distinction. There is no evidence of pyelectasia, nephroliths, infarcts or hydronephrosis.

**IMAGING PERFORMED BY**

Kim Liedberg

**Adrenal Glands**

The left adrenal gland is normal size (0.42 cm width). Normal shape and glandular echogenicity. The phrenicoabdominal vein and surrounding vasculature are normal.

**HOSPITAL NAME**

SVS Imaging WI

The right adrenal gland is normal size (0.34 cm width). Normal shape and glandular echogenicity. The phrenicoabdominal vein and surrounding vasculature are normal.

**REFERRING VET**

WVRC-Dr. Schulz

**Spleen**

The spleen is normal in size (0.80 cm in width at the level of the hilus) with a normal capsular contour. There is appropriate echogenicity and echotexture. No focal lesions are observed. Splenic vasculature is normal.

**INVOICE**

10599

**Liver**

The liver is subjectively normal in size with normal contours and structure. There is appropriate echogenicity and echotexture. No overt structural evidence of inflammatory, infiltrative, or regenerative pathology is evident. Vascular and biliary tracts are of normal volume with no evidence of congestion. No pathological hepatic lymphadenopathy observed.

**DATE**

3/23/22

**PATIENT**

Sebastian Breit

The gall bladder lumen is moderately distended. The wall is thin and smooth. A small amount of suspended echogenic debris is observed within the lumen. The cystic and common bile ducts are normal.

**SPECIES**

Feline

**Gastrointestinal**

The gastric lumen is not distended. The gastric wall and pylorus are normal in thickness with a normal layering pattern. The pyloric outflow tract is patent. The small intestinal lumen is not dilated. At least one small intestinal segment appears slightly plicated, without evidence of an obstructive pattern. The small intestinal wall is diffusely thickened (up to 0.41 cm), with retention of the normal layering pattern. There is disruption in the normal 1:3 muscularis: mucosal ratio, with a > 1:1 ratio in some segments. Discreet masses are not identified. At the level of the ileocecolic junction, the muscularis layer is prominent. The colonic wall is normal. There is no evidence of an obstructive pattern.

**BREED**

DSH

**SEX**

Neutered Male

**AGE**

14 years

**Pancreas**

The right limb is visible with normal curvilinear peripheral contours. The parenchyma is hypoechoic relative to surrounding omental fat. No distinct focal lesions are observed. The pancreatic duct is visible, but not overtly dilated (0.20 cm in diameter). There is no evidence of peripancreatic inflammation or effusion.

**WEIGHT**

10.1 lbs

**Free Abdomen**

There is no evidence of free fluid. A few prominent mesenteric lymph nodes are visualized, the largest measuring 1.93 cm in length. The mesentery surrounding the nodes is mildly hyperechoic.

**INTERPRETED BY**

Andrea Nicastro, DVM,  
Diplomate ACVIM (Small  
Animal Internal Medicine)

**IMAGING PERFORMED BY**

Kim Liedberg

**ULTRASONOGRAPHIC FINDINGS****Primary Findings**

- The bowel pattern could be consistent with emerging lymphoma or severe inflammatory bowel disease.
- The prominent abdominal lymph nodes are most consistent with reactive lymphadenitis or lymphoid hyperplasia. Neoplastic infiltration is considered less likely.

\*\* The corticosteroids may be masking bowel and lymph node pathology.

**Secondary Findings**

- The pancreatic changes may be a normal variant for this patient or could be consistent with mild, chronic pancreatitis. Correlation with clinical findings is recommended.
- Minor age-related renal changes

**HOSPITAL NAME**

SVS Imaging WI

**REFERRING VET**

WVRC-Dr. Schulz

**INVOICE**

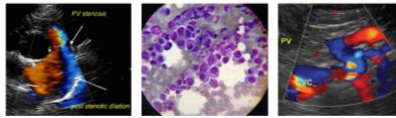
10599

**DATE**

3/23/22

**INTERPRETATION OF THE FINDINGS & FURTHER RECOMMENDATIONS**

- In order to get a definitive diagnosis, gastrointestinal biopsies, preferably surgical, would be necessary. If biopsies are pursued, the patient would ideally be weaned off corticosteroids to reduce the risk of masking of underlying gastrointestinal pathology. The mesenteric lymph



**PATIENT**

Sebastian Breit

nodes should also be biopsied at the time of surgery. Three-view thoracic radiographs should be performed prior to any anesthetic event.

**SPECIES**

Feline

- If biopsies are not to be pursued, adjustment of the patient's medications may be warranted. Regardless, a GI panel including serum cobalamin and folate TLI and PLI is recommended, along with a fecal evaluation for ova and Giardia, and a possible transition to a hypoallergenic diet, if the patient will tolerate it.

**BREED**

DSH

**SEX**

Neutered Male

**AGE**

14 years

**WEIGHT**

10.1 lbs

**INTERPRETED BY**

Andrea Nicastro, DVM,  
Diplomate ACVIM (Small  
Animal Internal Medicine)

**IMAGING PERFORMED BY**

Kim Liedberg

**HOSPITAL NAME**

SVS Imaging WI

**REFERRING VET**

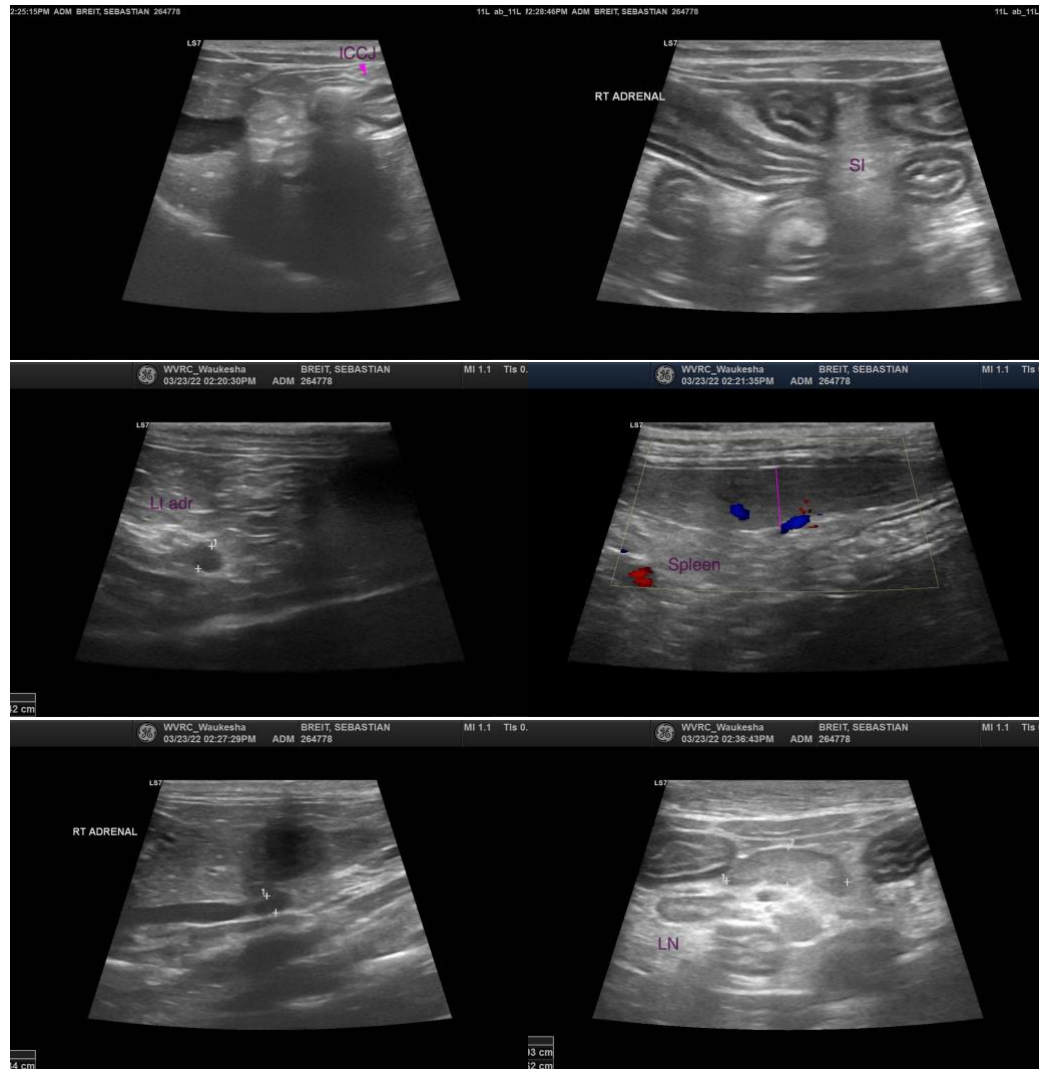
WVRC-Dr. Schulz

**INVOICE**

10599

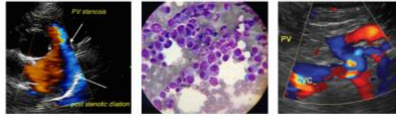

**DATE**

3/23/22



IMAGING PERFORMED BY

svsimagingqc.net 309-737-3070



Clinical Sonography & Telectology

EDUCATIONAL TELECONSULTATION SERVICES™

1-800-838-4268 info@sonopath.com SonoPath.com

**PATIENT**

Sebastian Breit

**SPECIES**

Feline

**BREED**

DSH

**SEX**

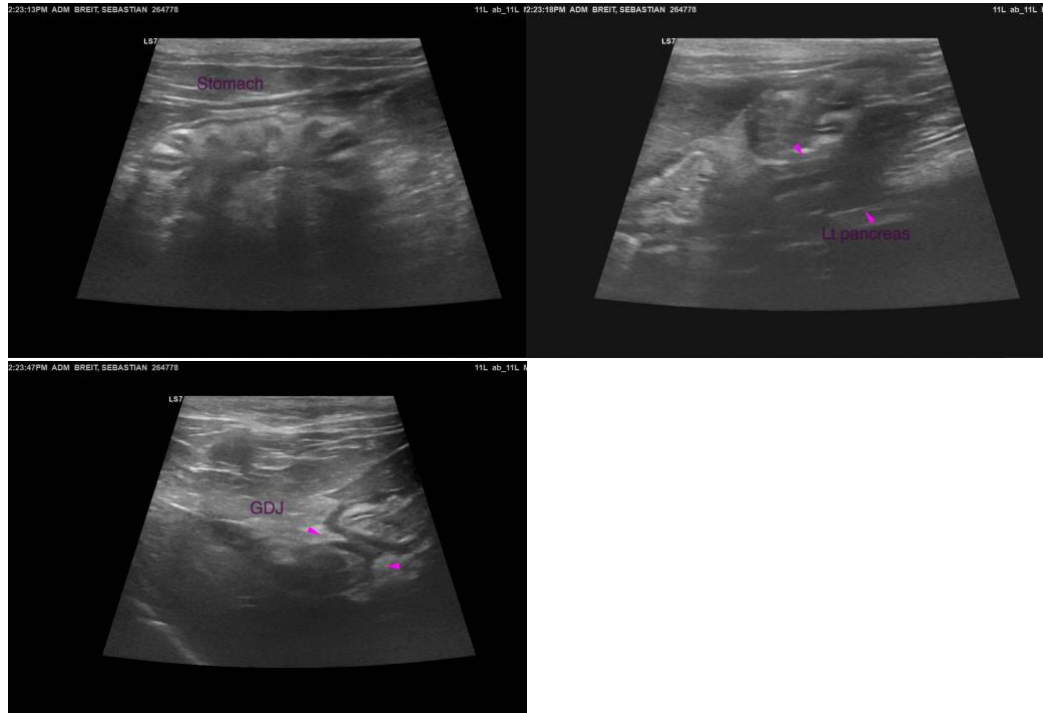
Neutered Male

**AGE**

14 years

**WEIGHT**

10.1 lbs



**INTERPRETED BY**

Andrea Nicastro, DVM,  
Diplomate ACVIM (Small  
Animal Internal Medicine)

**IMAGING PERFORMED BY**

Kim Liedberg

**HOSPITAL NAME**

SVS Imaging WI

**REFERRING VET**

WVRC-Dr. Schulz

**INVOICE**

10599

**DATE**

3/23/22

The information and recommendations provided are based on the images presented by the referring veterinarian/sonographer. No evaluation can be communicated regarding pathology that was not visible in the image/video clips provided.

Thank you for this referral. If the clinical or image interpretation does not parallel your findings or if I can be of any further assistance, please contact me.

Andrea Nicastro, DVM, Diplomate DACVIM (Small Animal Internal Medicine)  
info@SonoPath.com