


PATIENT PRESENTING CLINICAL SIGNS

Poppy Redmond History: Presented 3/21/23 for abdominal ultrasound after discovering liver changes. Patient has had normal bloodwork until 12/13/2021 when we started to notice kidney and thyroid changes. Rechecked values, T4 was stable and SDMA remained in the grey zone. Started on k/d January 2022. On 12/2022, presented for wellness and performed CBC/Chem/UA/T4 that showed stable kidney values but elevated ALT and ALP. Started her on Standard Process Hepatic Support, metronidazole 250mg (1/4 tab BID for 10 days), Denamarin Advanced (1/2 tab SID) and Convenia (patient has a sensitive stomach so we did this instead of amoxi-tri-clav). Recheck of ALT and ALP in Jan 2023 showed continued elevations. Patient is still on the Denamarin and k/d diet. She is still clinically doing well at home for an old girl.

SPECIES

Canine

BREED

Shih Tzu/Dachshund X

Abnormal PE/Chem/CBC/UA Results: bloodwork results attached.
 Most recent liver values: ALP 360. ALT 185.

SEX

Female Spayed

ULTRASONOGRAPHIC EXAMINATION OF THE ABDOMEN
Urinary System

The urinary bladder is mildly to moderately distended with anechoic urine. The wall is appropriate thickness for the level of repletion. The mucosal surface is slightly irregular. No cystic calculi are observed. The region of the trigone and visible portion of the proximal urethra are normal.

AGE

15 years

The left kidney is normal in size (3.92 cm in length) with a normal shape, architecture and smooth peripheral margins. There is a normal 1:3 cortex to medulla ratio with moderate loss of corticomedullary distinction. Several nonobstructive nephroliths are visualized. There is no evidence of pyelectasia, infarcts or hydronephrosis.

WEIGHT

18.6 lbs

The right kidney is normal in size (4.14 cm in length) with a slightly irregular, architecture and smooth peripheral margins. There is a normal 1:3 cortex to medulla ratio with moderate loss of corticomedullary distinction. A few nonobstructive nephroliths are visualized. There is no evidence of pyelectasia or hydronephrosis.

INTERPRETED BY

Andrea Nicastro, DVM,
 Diplomate ACVIM (*Small
 Animal Internal Medicine*)

Adrenal Glands

The left adrenal gland is mildly enlarged (0.59cm at cranial pole) (0.75 cm at caudal pole) with smooth peripheral contours. The parenchyma is mildly heterogenous with some loss of glandular detail. The phrenicoabdominal vein and surrounding vasculature are normal.

IMAGING PERFORMED BY

Dr. Goodman

The right adrenal gland is mildly enlarged (0.80 cm at cranial pole) (0.82 cm at caudal pole) with smooth peripheral contours. The parenchyma is mildly heterogenous with some loss of glandular detail. The phrenicoabdominal vein and surrounding vasculature are normal.

HOSPITAL NAME

Evandale-Blue Ash PH

Spleen

The spleen is normal in size (1.44 cm in width at the level of the hilus) with a normal capsular contour. There is appropriate echogenicity and echotexture. No focal lesions are observed. Splenic vasculature is normal.

REFERRING VET

Dr. Goodman

Liver

The liver is subjectively enlarged with slightly swollen peripheral contours. The parenchyma is isoechoic relative to the spleen and diffusely homogeneous in appearance. No distinct focal lesions are observed. Vascular and biliary tracts are of normal volume with no evidence of congestion.

INVOICE

12471

DATE

3.22.23

The gall bladder lumen is moderately distended. The wall is thin and smooth. A moderate to large amount of mostly gravity dependent echogenic-to-mineralized debris/sludge is observed within the lumen. The cystic and common bile ducts are normal/not seen.

Gastrointestinal

The lumen is not distended. The gastric wall is normal in thickness with a normal layering pattern. The small intestinal lumen is not dilated. The small intestinal wall thickness is normal with a normal layering pattern and appropriate mural detail. Discreet masses are not identified. The colonic wall is normal. There is no evidence of an obstructive pattern.

Pancreas

The region of the pancreas is isoechoic relative to surrounding omental fat. No obvious parenchymal abnormalities are observed. There is no evidence of regional inflammation or effusion.

Free Abdomen

The peritoneal cavity is normal. There is no evidence of inflammation or effusion. The abdominal lymph nodes are normal/not visible.

ULTRASONOGRAPHIC FINDINGS

Primary Findings

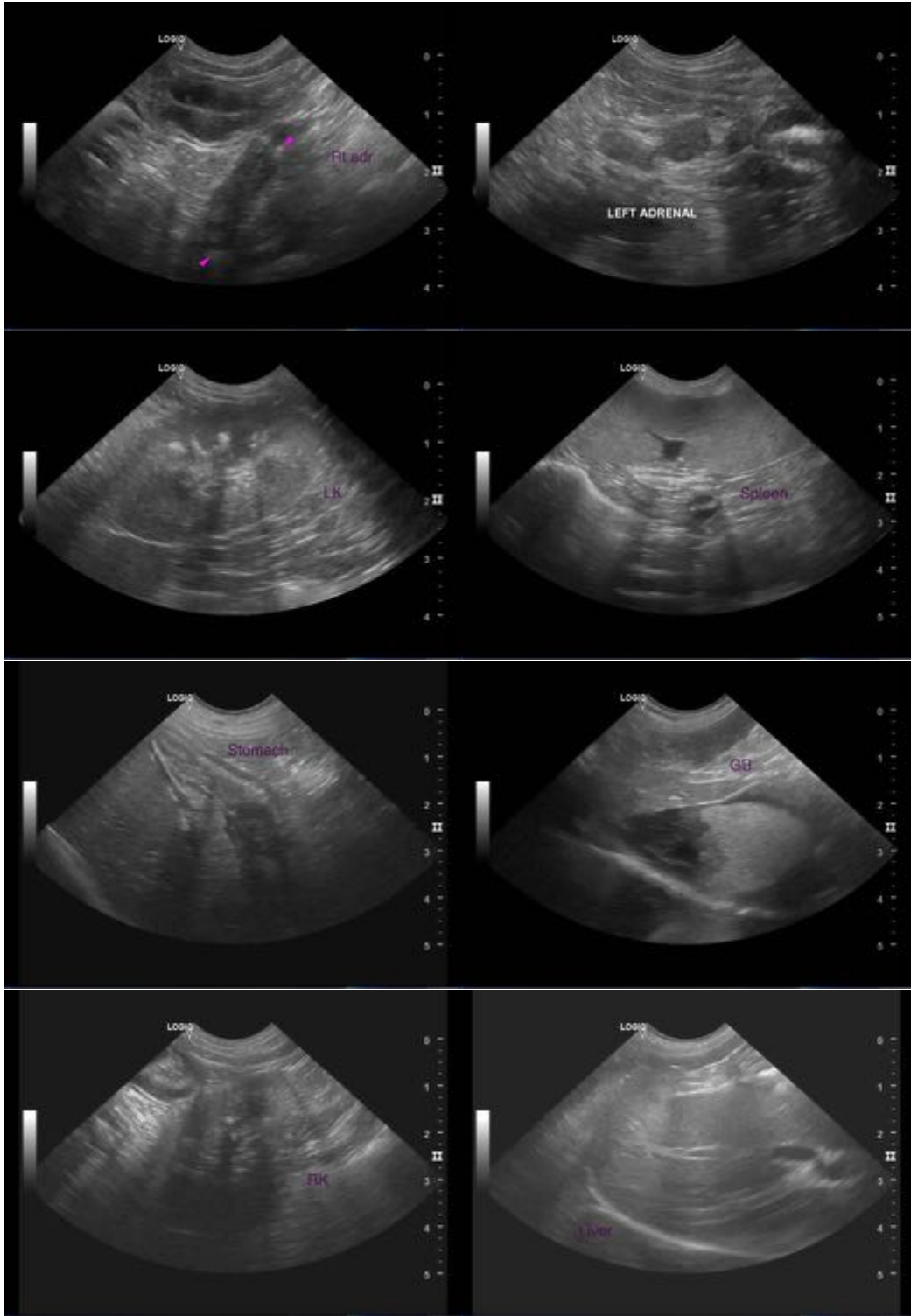
- The hepatic parenchymal changes are most consistent with a benign hepatopathy. Vacuolar hepatopathy (i.e., idiopathic/endocrine) is the top differential. In light of the liver enzyme pattern, inflammatory disease is considered less likely. Infiltrative neoplasia is possible, but also considered less likely in this patient.
- Mild bilateral adrenomegaly
- Gall bladder sludge – non-mucocele

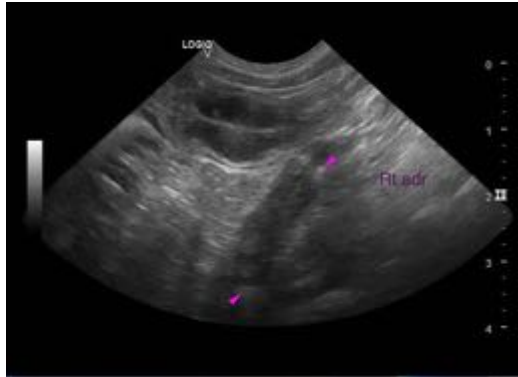
Secondary Findings

- Bilateral chronic age-related renal changes with nonobstructive nephrolithiasis, more pronounced in the left kidney

INTERPRETATION OF THE FINDINGS & FURTHER RECOMMENDATIONS

- Consider testing for hyperadrenocorticism with a low-dose dexamethasone suppression test or ACTH stimulation test if clinical signs (i.e., PU/PD) develop.
- Serial monitoring (i.e., every 3-4 months) of the patient's liver values is recommended. If values continue to increase, a repeat abdomen ultrasound +/- a more advanced hepatic work-up (i.e., tissue sampling) may be warranted.





The information and recommendations provided are based on the images presented by the referring veterinarian/sonographer. No evaluation can be communicated regarding pathology that was not visible in the image/video clips provided.

Thank you for this referral. If the clinical or image interpretation does not parallel your findings or if I can be of any further assistance, please contact me.

Andrea Nicastro, MPH, DVM, Diplomate DACVIM (Small Animal Internal Medicine)
info@SonoPath.com