



**PATIENT**

Teaka Bergeron

**PRESENTING CLINICAL SIGNS**

History: Exam for lameness and check mass left hind leg (soft cell sarcoma). Has elevated liver enzymes: ALT, 439, AST 75, ALP 183. Chest radiographs pending.

**SPECIES**

Canine

**ULTRASONOGRAPHIC EXAMINATION OF THE ABDOMEN**

*Urinary System*

The urinary bladder wall is normal in thickness and the mucosal surface is smooth. The bladder is moderately distended. Luminal contents are anechoic. No cystic calculi are observed. The region of the trigone and the visible portion of the proximal urethra are normal.

**BREED**

Labrador Retriever

**SEX**

Female, spayed

The left kidney is normal size (6.49 cm in length); normal shape and architecture with smooth peripheral margins. There is a normal 1:3 cortex to medulla ratio with minimal to mild loss of corticomedullary distinction. There is no evidence of pyelectasia, nephroliths, infarcts or hydroureter.

**AGE**

13 Yrs.

The right kidney is normal size (5.89 cm in length); normal shape and architecture with smooth peripheral margins. There is a normal 1:3 cortex to medulla ratio with minimal to mild loss of corticomedullary distinction. There is no evidence of pyelectasia, nephroliths, infarcts or hydroureter.

**WEIGHT**

70 lbs.

*Adrenal Glands*

The left adrenal gland is normal size (0.43 cm at cranial pole) (0.68 cm at caudal pole); normal shape; homogenous parenchyma. The glandular echogenicity and detail are unremarkable. Capsule, cortex, and medullary definition are normal. The phrenicoabdominal vein and surrounding vasculature are normal.

**INTERPRETED BY**

Andrea Nicastro, DVM,  
Diplomate ACVIM  
(*Small Animal Internal  
Medicine*)

The right adrenal gland is normal size (0.62 cm at cranial pole) (0.55 cm at caudal pole); normal shape; homogenous parenchyma. The glandular echogenicity and detail are unremarkable. Capsule, cortex, and medullary definition are normal. The phrenicoabdominal vein and surrounding vasculature are normal.

*Spleen*

The spleen is subjectively normal in size (1.33 cm in width at the level of the hilus) with a normal capsular contour. The parenchyma is diffusely mottled with ill-defined hypoechoic areas, the largest measuring 1.80 cm in diameter. Splenic vasculature is normal with no evidence of thrombosis.

**IMAGING PERFORMED BY**

Pamela Harrigan

*Liver*

The liver is subjectively normal in size with slightly irregular peripheral contours. The parenchyma is hypoechoic relative to the spleen and mildly and diffusely heterogeneous in appearance. A 1.80 cm septated cystic lesion is observed on the left side. There is an increase in portal markings. Vascular is of normal volume with no evidence of congestion. The gall bladder lumen is moderately distended. The wall is thin and smooth. A small amount of mostly gravity-dependent echogenic to mineralized debris is observed within the lumen. The cystic and common bile ducts are normal/not seen.

**HOSPITAL NAME**

VCA Palmer

**REFERRING VET**

Dr. Joyce Mellon

**INVOICE**

14757

*Gastrointestinal*

The stomach and intestine are free of stasis and exhibit normal peristaltic activity. The gastric lumen is not distended. The gastric wall and pylorus are normal in thickness with a normal layering pattern. The pyloric outflow tract is patent. The small intestinal lumen is not dilated. The small intestinal wall

**DATE**

3/20/23



**PATIENT**

Teaka Bergeron

thickness is normal with a normal layering pattern and appropriate mural detail. Discreet masses are not identified. The colonic wall is normal. No obstructive disease is noted.

**Pancreas**

**SPECIES**

Canine

The pancreas is normal in size with normal peripheral contours. The pancreatic duct is normal. The base and limbs of the pancreas are isoechoic to surrounding omental fat. No focal lesions are observed. There is no evidence of peripancreatic inflammation or effusion.

**BREED**

Labrador Retriever

**Free Abdomen**

The peritoneal cavity is normal. There is no evidence of inflammation or effusion. 1-2 medial iliac lymph nodes are visualized, the largest measuring 2.43 cm in length. The nodes are normal in shape and echogenicity.

**SEX**

Female, spayed

**ULTRASONOGRAPHIC FINDINGS**

**AGE**

13 Yrs.

**Primary Findings:**

- Non-specific diffuse hepatopathy. Given the patient's breed, top differentials include chronic hepatitis and hepatotoxicosis (copper). Other potential differentials include fibrosis, Leptospirosis, infiltrative neoplasia, regenerative nodular hyperplasia, other hepatopathy. The cystic hepatic lesion trends toward the benign. However, an emerging cystic or vascular tumor (i.e., biliary cystadenoma/adenocarcinoma, hemangiosarcoma, respectively) cannot be excluded.
- Gallbladder debris- incidental.

**WEIGHT**

70 lbs.

**Secondary Findings:**

- Minor bilateral age-related renal changes.
- The prominent caudal abdominal lymph nodes are most consistent with reactive lymphadenitis or lymphoid hyperplasia. Neoplastic infiltration is considered less likely.
- The splenic parenchymal changes could be consistent with a benign process (i.e., lymphoid hyperplasia, extramedullary hematopoiesis or similar). Alternatively, emerging neoplasia (i.e., round cell tumor) is possible, although considered less likely.

**INTERPRETED BY**

Andrea Nicastro, DVM,  
Diplomate ACVIM  
(Small Animal Internal  
Medicine)

**IMAGING PERFORMED BY**

Pamela Harrigan

**HOSPITAL NAME**

VCA Palmer

**INTERPRETATION OF THE FINDINGS & FURTHER RECOMMENDATIONS**

**REFERRING VET**

Dr. Joyce Mellon

- If the liver enzyme elevations are acute in nature, consider Leptospirosis testing (i.e., blood and urine PCR, serology). Also consider pre and post prandial serum bile acids to assess hepatic function.
- Laparoscopic or surgical biopsies would be necessary to get a definitive diagnosis. If pursued, multiple lobes should be biopsied to get a good representation of global hepatic pathology. Aerobic and anaerobic bile cultures should also be obtained and hepatic copper quantitation should be performed. Clotting times should be performed prior to any tissue samplings. Three-view thoracic radiographs are recommended prior to anesthesia to assess cardiopulmonary status.

**INVOICE**

14757

**DATE**

3/20/23



**PATIENT**

Teaka Bergeron

\*Hepatic aspirates can be considered. However, given the top differentials in this patient, cytologic evaluation is unlikely to provide a definitive diagnosis.

**SPECIES**

Canine

**BREED**

Labrador Retriever

**SEX**

Female, spayed

**AGE**

13 Yrs.

**WEIGHT**

70 lbs.

**INTERPRETED BY**

Andrea Nicastro, DVM,  
Diplomate ACVIM  
(Small Animal Internal  
Medicine)

**IMAGING PERFORMED BY**

Pamela Harrigan

**HOSPITAL NAME**

VCA Palmer

**REFERRING VET**

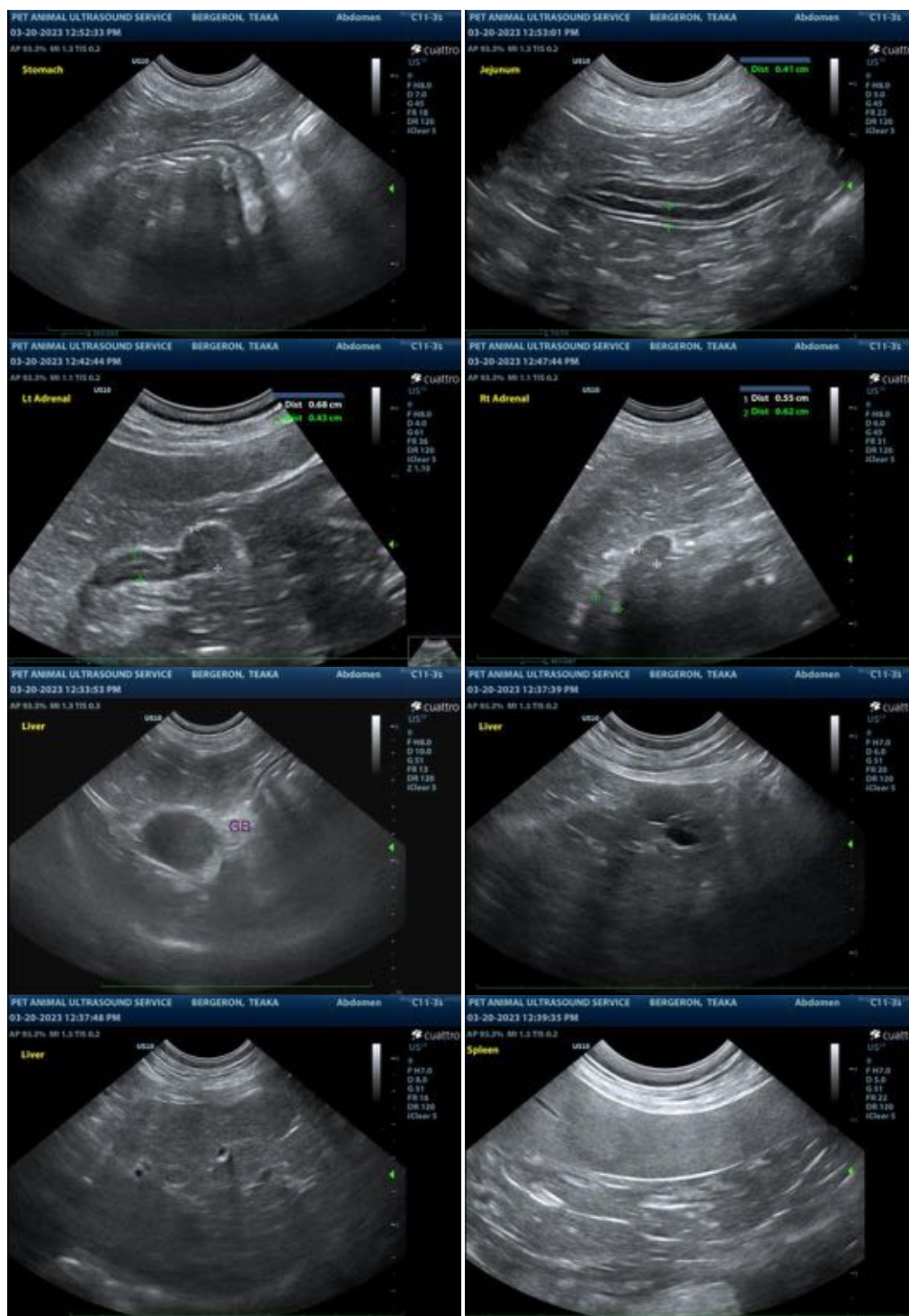
Dr. Joyce Mellon

**INVOICE**

14757

**DATE**

3/20/23





**PATIENT**

Teaka Bergeron

**SPECIES**

Canine

**BREED**

Labrador Retriever

**SEX**

Female, spayed

**AGE**

13 Yrs.

**WEIGHT**

70 lbs.

**INTERPRETED BY**

Andrea Nicastro, DVM,  
Diplomate ACVIM  
(*Small Animal Internal  
Medicine*)

**IMAGING  
PERFORMED BY**

Pamela Harrigan

**HOSPITAL NAME**

VCA Palmer

**REFERRING VET**

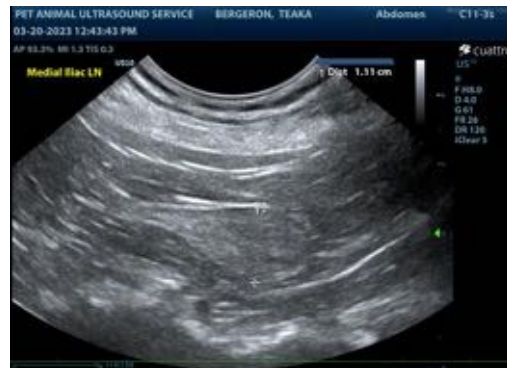Dr. Joyce Mellon

**INVOICE**

14757

**DATE**

3/20/23



The information and recommendations provided are based on the images presented by the referring veterinarian/sonographer. No evaluation can be communicated regarding pathology that was not visible in the image/video clips provided.

Thank you for this referral. If the clinical or image interpretation does not parallel your findings or if I can be of any further assistance please contact me.

Andrea Nicastro, MPH, DVM, Diplomate DACVIM (Small Animal Internal Medicine)  
[info@SonoPath.com](mailto:info@SonoPath.com)