SonoPath
Clinical Sonography & Telecytology
EDUCATIONAL TELECONSULTATION SERVICES™
1-800-838-4268 info@sonopath.com SonoPath.com

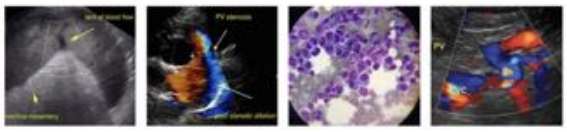

Charleston Mobile Veterinary Services
IMAGING PERFORMED BY
CharlestonMobile.Net 800.403.5408

PATIENT
Oscar Crowley

SPECIES
Feline

BREED
Ragdoll

SEX
Neutered Male

AGE
10/07/15

WEIGHT
12.8 lbs

INTERPRETED BY
Andrea Nicastro, DVM, Diplomate ACVIM (*Small Animal Internal Medicine*)

IMAGING PERFORMED BY
Andrea Nicastro, DVM, Diplomate ACVIM (*Small Animal Internal Medicine*)

HOSPITAL NAME
Flowertown AH

REFERRING VET
Dr. Guffey

INVOICE
12443

DATE
3.17.23

PRESENTING CLINICAL SIGNS

Clinical Exam Findings:
Presented for a 2-week history of lethargy and inappropriate urinations
Very firm irregular abdominal mass

Lab-work: Not performed
Current Medications: None
Radiographic Findings: Peritoneal effusion

ULTRASONOGRAPHIC EXAMINATION OF THE ABDOMEN

Urinary System

The urinary bladder wall is normal in thickness and the mucosal surface is smooth. The bladder is moderately distended. A small to moderate amount of suspended echogenic debris is observed within the lumen. No cystic calculi are observed. The region of the trigone and the proximal urethra, visible to a depth of 2 cm, are normal.

The left kidney is normal in size (4.08 cm in length) with a normal shape, architecture and smooth peripheral margins. There is a normal 1:3 cortex to medulla ratio with minimal loss of corticomedullary distinction. There is no evidence of pyelectasia, nephroliths, infarcts or hydroureter. Renal vasculature is normal.

The right kidney is upper limits of normal size (4.59 cm in length) with a normal shape, architecture and smooth peripheral margins. There is a normal 1:3 cortex to medulla ratio with minimal loss of corticomedullary distinction. There is no evidence of pyelectasia, nephroliths, infarcts or hydroureter. Renal vasculature is normal.

Adrenal Glands

The left adrenal gland is normal in size (0.34 cm width). Normal shape and glandular echogenicity. The phrenicoabdominal vein and surrounding vasculature are normal.

The right adrenal gland is normal in size (0.38 width). Normal shape and glandular echogenicity. The phrenicoabdominal vein and surrounding vasculature are normal.

Spleen

The spleen is normal in size (0.54 cm in width at the level of the hilus) with a normal capsular contour. There is appropriate echogenicity and echotexture. No focal lesions are observed. Splenic vasculature is normal.

Liver

The liver is enlarged with irregular peripheral contours. Several hyperechoic-to-heterogenous masses are observed throughout the organ (the largest measuring >4.00 cm). The remaining parenchyma is hypoechoic relative to the spleen. Hepatic vasculature and intrahepatic biliary tracts are of normal volume with no evidence of congestion.

The gall bladder lumen is moderately distended. The wall is thin and smooth. Luminal contents are mostly anechoic. The cystic and common bile ducts are normal.

Gastrointestinal

The stomach is partially obscured by the large cranial abdominal mass. In the visualized portions, the gastric wall is normal in thickness with a normal layering pattern. The lumen contains gas. The pyloric outflow tract appears patent. The small intestinal lumen is not dilated. The small intestinal wall is normal in thickness with retention of the normal layering pattern. There is disruption in the normal 1:3 muscularis: mucosal

ratio in most segments. Some of the bowel segments are slightly plicated/hyperperistaltic. Discreet masses are not identified. The ileocecocolic junction and colonic wall are normal. There is no obvious evidence of an obstructive pattern.

Pancreas
(See "Other" category).

Free Abdomen
A large amount of slightly echogenic free fluid is observed.

Lymph Nodes
(See "Other" category).

Other
A brief echocardiogram reveals no obvious evidence of pericardial effusion. There is suspected trace pleural effusion.

A >6.50 cm irregular heterogenous cavitated mass is observed in the cranial abdomen. The mass partially obscures the stomach in the pancreatic region. In addition, several echogenic masses are observed throughout the abdomen.

ULTRASONOGRAPHIC FINDINGS

Primary Findings

- Hepatic masses. Neoplasia (i.e., adenocarcinoma, sarcoma, round cell tumor) is consider likely with a lower possibility of a multi-focal inflammatory process (i.e., pyogranulomatous).
- The origin of the masses throughout the abdomen is unclear. The largest mass may be arising from pancreas, lymph node, mesentery, other. The smaller masses may represent enlarged lymph nodes or mesenteric masses. Again, differentials include neoplasia, or less likely, multi-focal pyogranulomatous inflammation.
- The ascites is likely secondary to the diffuse abdominal pathology.
- Suspected trace pleural effusion

Secondary Findings

- Bowel changes consistent with inflammatory bowel disease, with some potential for emerging lymphoma.

INTERPRETATION OF THE FINDINGS & FURTHER RECOMMENDATIONS

- Submission of the abdominal fluid (already obtained) is recommended. Also consider fine-needle aspirates of the abdominal masses (if clotting status is appropriate). Twenty-five gauge-needles should be used.
- Three-view thoracic radiographs are recommended to assess for pulmonary metastatic disease (if not already performed).

- Depending on the results of the above diagnostics, consultation with a board-certified oncologist may be warranted.

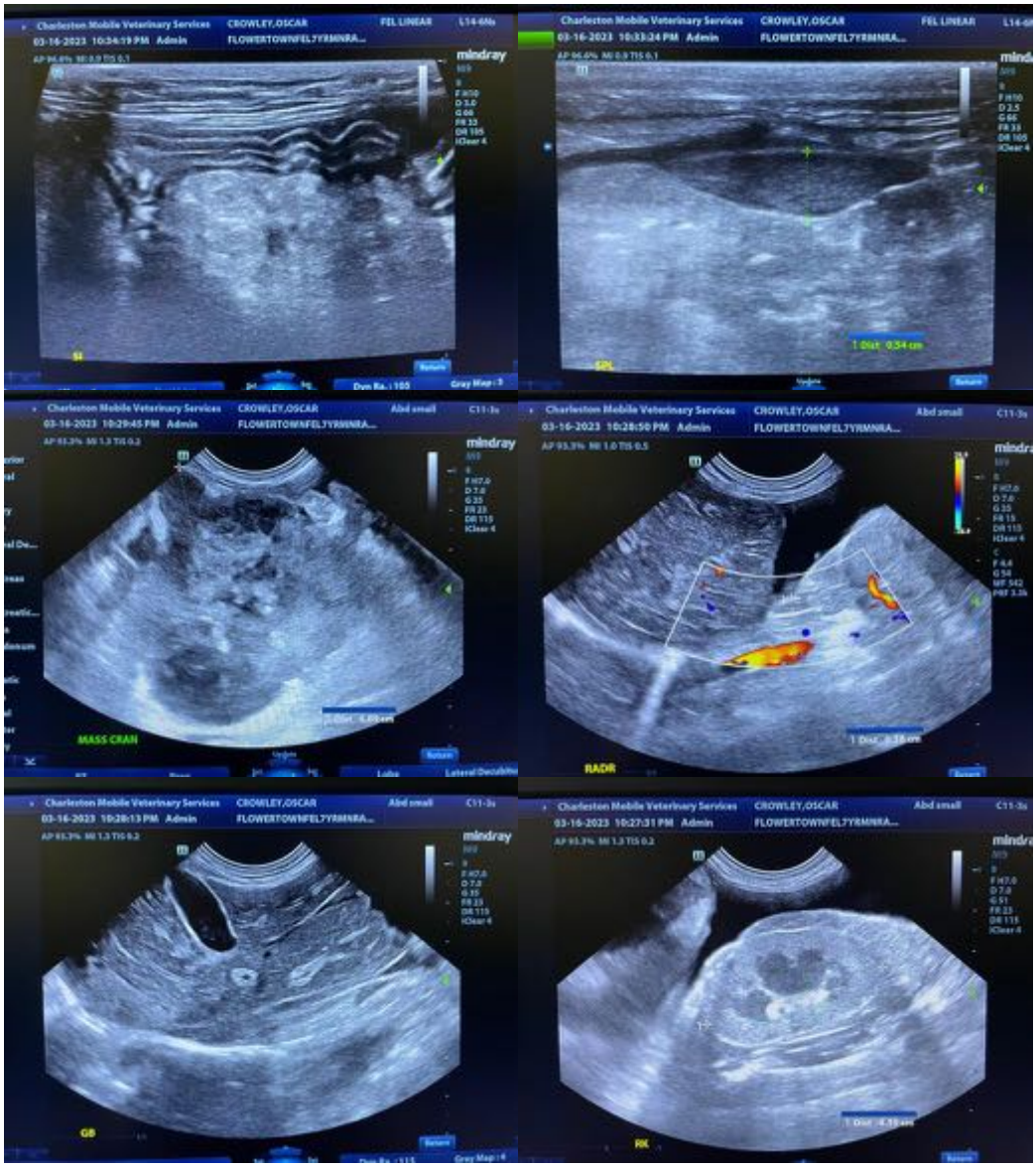

Charleston Mobile Veterinary Services
CROWLEY,OSCAR
Abd small
03-16-2023 10:27:16 PM Admin
FLOWERTOWNFEL7YRMNRA...
LIV RT MASSES
Charleston Mobile Veterinary Services
CROWLEY,OSCAR
Abd small
03-16-2023 10:25:03 PM Admin
FLOWERTOWNFEL7YRMNRA...
mindray
LIVER MASS
Charleston Mobile Veterinary Services
CROWLEY,OSCAR
Abd small
03-16-2023 10:24:45 PM Admin
FLOWERTOWNFEL7YRMNRA...
STOM
Charleston Mobile Veterinary Services
CROWLEY,OSCAR
Abd small
03-16-2023 10:23:30 PM Admin
FLOWERTOWNFEL7YRMNRA...
mindray
MASS
Charleston Mobile Veterinary Services
CROWLEY,OSCAR
Abd small
03-16-2023 10:22:04 PM Admin
FLOWERTOWNFEL7YRMNRA...
LADR
Charleston Mobile Veterinary Services
CROWLEY,OSCAR
Abd small
03-16-2023 10:21:34 PM Admin
FLOWERTOWNFEL7YRMNRA...
1 Dist 4.09 cm
LK

The information and recommendations provided are based on the images presented by the referring veterinarian/sonographer. No evaluation can be communicated regarding pathology that was not visible in the image/video clips provided.

Thank you for this referral. If the clinical or image interpretation does not parallel your findings or if I can be of any further assistance, please contact me.

Andrea Nicastro, MPH, DVM, Diplomate DACVIM (Small Animal Internal Medicine)
info@SonoPath.com