



PATIENT PRESENTING CLINICAL SIGNS

Fletcher Albers Clinical Exam Findings:
BCS 6/9
EENT: Ears/eyes clean & clear. Periodontal disease stage 2/4. MMs pink & moist, crt <2s. No nasal discharge noted.
SPECIES Integumentary: No external parasites noted.
Canine Cardiovascular: Grade III-IV/VI left apical systolic murmur. normal heart rate & rhythm. Lungs clear, normal respiratory rate.
BREED Abdomen: Soft, nonpainful. No masses palpated.
Labrador Retr Musculoskeletal: Ambulatory x 4
Neuro: Appropriate mentation.
Genitourinary: WNL.
SEX Abnormal lab-work values: CARDIOPET proBNP – CANINE. value: 1700 pmol/L
Neutered Male Current Medications: Apoquel 16mg Tablet Give 1 tablet by mouth twice daily for 7 days (unsure if O will give). Trazadone #100mg 1 tablet (O will give day of most likely for anxiety)

AGE ULTRASONOGRAPHIC EXAMINATION OF THE ABDOMEN

10-16-2013 **Urinary System**
The bladder is distended. The wall is normal in thickness with a smooth mucosal surface. A 0.81 cm cystic calculus is observed within the lumen, along with a small amount of suspended echogenic debris. The region of the trigone and the proximal urethra, visible to a depth of 2 cm, are normal.
WEIGHT 91.2 lbs
The prostate is normal in size (1.25 cm in width) and shape. Parenchyma is homogenous. The prostatic urethra appears normal without evidence of dilation or obstruction.

INTERPRETED BY

Andrea Nicastro, DVM,
Diplomate ACVIM (*Small Animal Internal Medicine*)

IMAGING PERFORMED BY

Andrea Nicastro, DVM,
Diplomate ACVIM (*Small Animal Internal Medicine*)

HOSPITAL NAME

Salt Marsh AH

REFERRING VET

Dr. Christie Wiles

INVOICE

12445

DATE

3.17.23

The left kidney is normal in size (7.47 cm in length) with a normal shape, architecture and smooth peripheral margins. There is a normal 1:3 cortex to medulla ratio with minimal loss of corticomedullary distinction. There is no evidence of pyelectasia, nephroliths, infarcts or hydroureter. Renal vasculature is normal.

The right kidney is normal in size (7.64 cm in length) with a normal shape, architecture and smooth peripheral margins. There is a normal 1:3 cortex to medulla ratio with minimal loss of corticomedullary distinction. There is no evidence of pyelectasia, nephroliths, infarcts or hydroureter. Renal vasculature is normal.

Adrenal Glands

The left adrenal gland is normal in size (0.66 cm at cranial pole) (0.49 cm at caudal pole) with a normal shape and homogenous parenchyma. The glandular echogenicity and detail are unremarkable. Capsule, cortex, and medullary definition are normal. The phrenicoabdominal vein and surrounding vasculature are normal.

The right adrenal gland is in normal size (1.04 cm at cranial pole) (0.53 cm at caudal pole) with a normal shape and homogenous parenchyma. The glandular echogenicity and detail are unremarkable. Capsule, cortex, and medullary definition are normal. The phrenicoabdominal vein and surrounding vasculature are normal.

Spleen

The spleen is prominent in size (3.37 cm in width at the level of the hilus) with normal curvilinear peripheral contours. A light micronodular pattern is observed throughout the parenchyma. Splenic vasculature appears normal with no evidence of thrombosis.

Liver

The liver is subjectively normal in size with normal curvilinear peripheral contours. The parenchyma is hypoechoic relative to the spleen with minor changes consistent with age-related remodeling. No focal lesions are observed. Hepatic vasculature and biliary tracts are of normal volume with no evidence of congestion.

The gall bladder lumen is moderately distended. The wall is thin and smooth. A small to moderate amount of mostly gravity dependent echogenic debris is observed within the lumen. The cystic and common bile ducts are normal/not seen.

Gastrointestinal

The gastric lumen is minimally distended. A 2.20 cm slightly irregular shadowing structure is observed within the lumen. The pyloric outflow tract appears patent. The gastric wall is normal in thickness with a normal layering pattern. The small intestinal lumen is not dilated. The small intestinal wall is normal in thickness with a normal layering pattern and appropriate mural detail. Discreet masses are not identified. The colonic wall is normal. There is no evidence of an obstructive pattern.

Pancreas

The region of the pancreas is isoechoic relative to surrounding omental fat. No obvious parenchymal abnormalities are observed. There is no evidence of regional inflammation or effusion.

Free Abdomen

The peritoneal cavity is normal. There is no evidence of inflammation or effusion. The abdominal lymph nodes are normal/not visible.

ULTRASONOGRAPHIC FINDINGS

Primary Findings

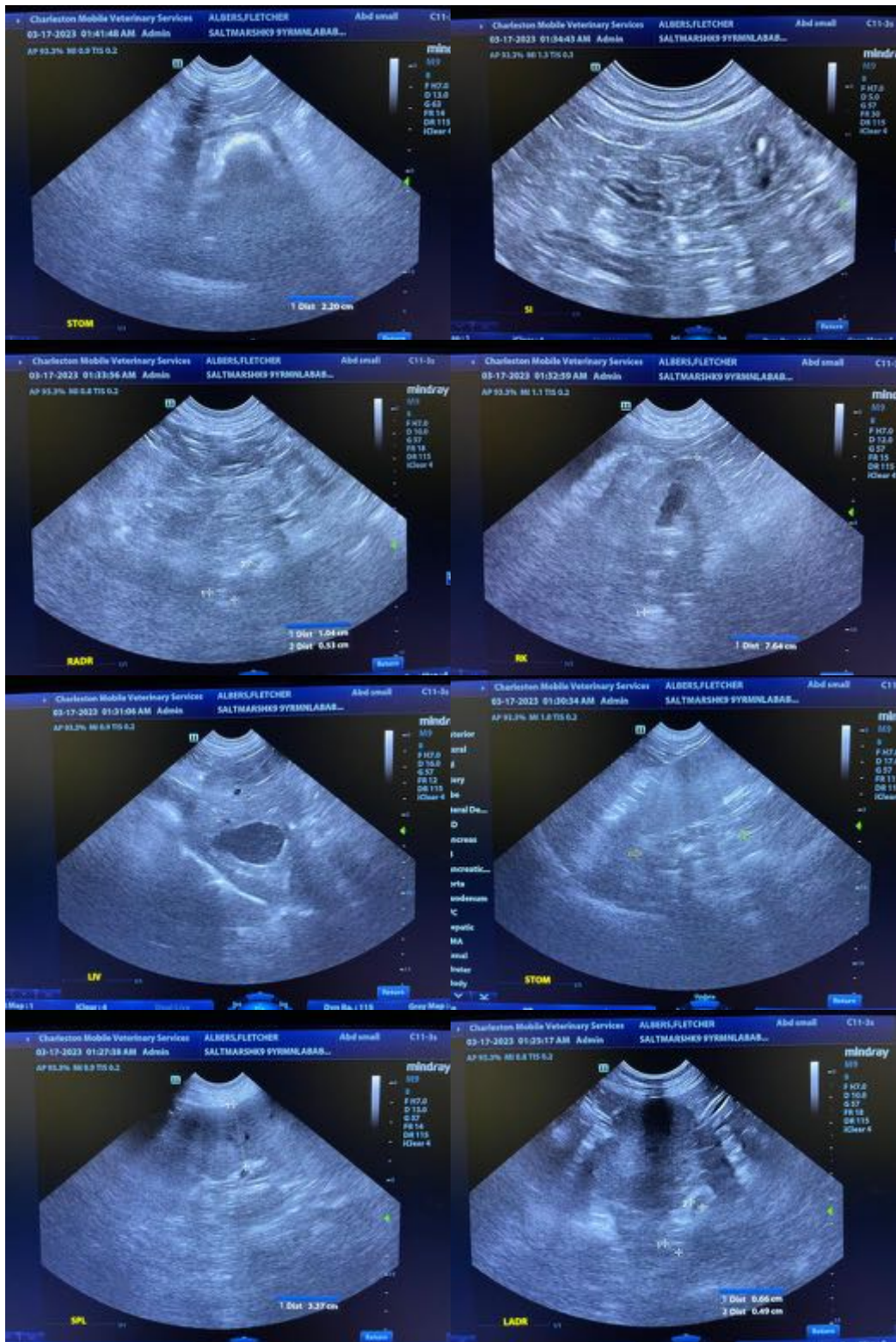
- Small cystic calculus. The calculus is similar in size compared to the previous sonogram.
- The splenic parenchymal changes are most consistent with a benign process such as lymphoid hyperplasia, extramedullary hematopoiesis, splenitis or antigenic stimulation with a low possibility of infiltrative neoplasia (i.e., lymphoma, mast cell neoplasia). Changes are similar to the previous sonogram.

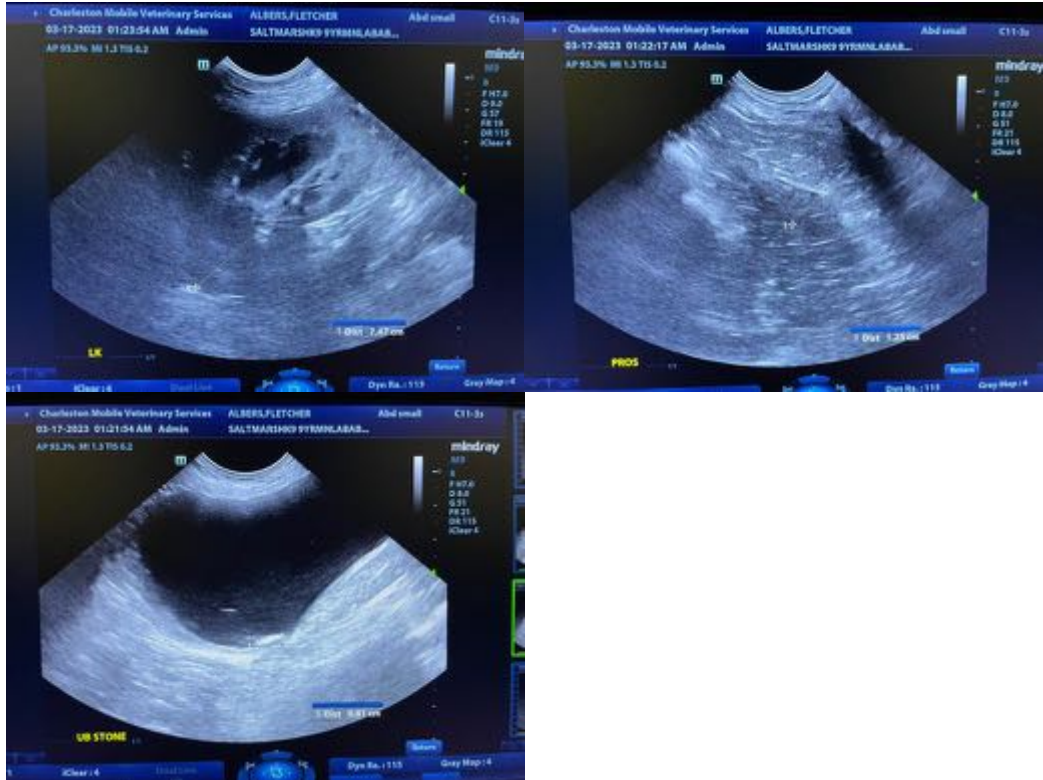
Secondary Findings

- The hepatic changes are consistent with age-related parenchymal remodeling. However, correlation with the patient's liver values is recommended.
- The shadowing material within the gastric lumen may represent ingesta and/or foreign material. It appears nonobstructive at the time of this study.

INTERPRETATION OF THE FINDINGS & FURTHER RECOMMENDATIONS

- Regarding the cystic calculus, if an aggressive approach is desired, consider a cystotomy with stone removal, analysis and culture. Otherwise, consider serial sonographic monitoring (i.e., every 3-6 months) to assess for growth of the stone. Continuation of the urinary diet is also recommended.





The information and recommendations provided are based on the images presented by the referring veterinarian/sonographer. No evaluation can be communicated regarding pathology that was not visible in the image/video clips provided.

Thank you for this referral. If the clinical or image interpretation does not parallel your findings or if I can be of any further assistance, please contact me.

Andrea Nicastro, MPH, DVM, Diplomate DACVIM (Small Animal Internal Medicine)
info@SonoPath.com