



## PATIENT PRESENTING CLINICAL SIGNS

**PATIENT** Blair Corrigan  
**SPECIES** History: Presented for recurrent bloody vaginal discharges, non-responsive to oral antibiotics. Abnormal PE/Chem/CBC/UA Results: Palpable abdominal mass - suspect mammary gland. Vaginal exam: no palpable mass, but significant amount of frank blood on pelvic vaginal canal. On Ultrasound, canal was inflamed, but no obvious masses on the visible field.

Canine

## ULTRASONOGRAPHIC EXAMINATION OF THE ABDOMEN

### BREED

#### Urinary System

**BREED** Rottweiler Mix  
**SEX** Female Spayed  
 The urinary bladder is moderately distended. The wall in the region of the apex is normal in thickness with a smooth mucosal surface. In the region of the dorsal and ventral cystourethral junction and proximal urethra, the wall is thickened up to 0.84 cm (cystourethral junction) and up to 1.3 cm (urethra) and irregular, with loss of wall layering. There appears to be fluid dissection within the wall in this region. Echogenic material is observed within the proximal urethral lumen. The mesentery effacing the serosal surface in this region is hyperechoic. There is no evidence of cystic calculi.

### AGE

12

The left kidney is normal in size (6.52 cm in length) with a normal shape, architecture and smooth peripheral margins. There is a normal 1:3 cortex to medulla ratio with minimal loss of corticomedullary distinction. Moderate pyelectasia is present (0.70 cm in the longitudinal plane). There is no evidence of nephroliths, infarcts or hydroureter. Renal vasculature is normal. A small amount of subcapsular fluid is present. Perirenal fat is hyperechoic.

### WEIGHT

27.5 kg

The right kidney is normal in size (6.60 cm in length) with a normal shape, architecture and smooth peripheral margins. There is a normal 1:3 cortex to medulla ratio with minimal loss of corticomedullary distinction. Mild- to moderate pyelectasia is present (0.37 cm in the longitudinal plane). There is no evidence of nephroliths, infarcts or hydroureter. Renal vasculature is normal. Trace subcapsular is present. Perirenal fat is hyperechoic. A scant amount of retroperitoneal fluid is observed.

## INTERPRETED BY

Andrea Nicastro, DVM,  
 Diplomate ACVIM  
 (Small Animal Internal  
 Medicine)

#### Adrenal Glands

The left adrenal gland is mildly enlarged (0.79 cm at cranial pole) (0.84 cm at caudal pole) with a slightly irregular shape. Glandular echogenicity and detail are normal. Surrounding vasculature appears normal.

## IMAGING PERFORMED BY

Natalia Franco

The right adrenal gland is mildly enlarged (0.77 cm at cranial pole) (0.84 cm at caudal pole) with a slightly irregular shape. The parenchyma is hypoechoic- to slightly heterogenous in appearance, with some loss of glandular detail. Surrounding vasculature appears normal.

## HOSPITAL NAME

Eagleson VC

#### Spleen

The spleen is normal in size (1.61 cm in width at the level of the hilus) with a normal capsular contour. The parenchyma is diffusely mottled in appearance. A few, small, myelolipomas are observed in the region of the hilus. Splenic vasculature is normal.

## REFERRING VET

Mohamed Ammar

#### Liver

The liver is subjectively normal in size with normal contours and structure. There is appropriate echogenicity and echotexture. No overt structural evidence of inflammatory, infiltrative, or regenerative pathology is evident. Vascular and biliary tracts are of normal volume with no evidence of congestion.

## INVOICE

22699

## DATE

3-16-26

The gallbladder lumen is moderately distended. The wall is thin and smooth. Luminal contents are mostly anechoic. The cystic and common bile ducts are normal/not seen.



**PATIENT** *Gastrointestinal*

Blair Corrigan

The gastric lumen is not distended. The gastric wall is normal in thickness with a normal layering pattern. The small intestinal lumen is not dilated. The small intestinal wall is normal in thickness with a normal layering pattern and appropriate mural detail. Discreet masses are not identified. The colonic wall is normal. There is no evidence of an obstructive pattern.

**SPECIES**

Canine

*Pancreas*

The region of the pancreas is isoechoic relative to surrounding omental fat. No obvious parenchymal abnormalities are observed. There is no evidence of regional inflammation or effusion.

**BREED**

Rottweiler Mix

*Lymph Nodes*

The abdominal lymph nodes are normal/not visible.

**SEX**

Female Spayed

*Free Abdomen*

Trace retroperitoneal fluid is observed.

**AGE**

12

**ULTRASONOGRAPHIC FINDINGS**

**Primary Findings**

**WEIGHT**

27.5 kg

- The urinary bladder wall changes in the region of the cystourethral junction, along with the urethral wall changes are concerning for infiltrative neoplasia (i.e., transitional cell carcinoma) with a lower possibility of an inflammatory process. Mild adjacent retroperitonitis is present.
- The bilateral pyelectasia may be secondary to distal ureteral obstruction at the level of the trigone, pyelonephritis, parenchymal remodeling, PU/PD (if applicable), or some combination thereof. There is evidence of cranial retroperitonitis, which may be secondary interstitial nephritis, pyelonephritis, emerging neoplasia (less likely), other.

**INTERPRETED BY**

Andrea Nicastro, DVM,  
Diplomate ACVIM  
(Small Animal Internal  
Medicine)

**Secondary Findings**

**IMAGING PERFORMED BY**

Natalia Franco

- The splenic parenchyma changes are most consistent with a benign process such as lymphoid hyperplasia, extramedullary hematopoiesis or splenitis with a lower possibility of infiltrative neoplasia (i.e., lymphoma, mast cell neoplasia).

**HOSPITAL NAME**

Eagleson VC

- Bilateral adrenomegaly

**INTERPRETATION OF THE FINDINGS & FURTHER RECOMMENDATIONS**

**REFERRING VET**

Mohamed Ammar

A minimum database (including a CBC, chemistry panel, urinalysis, and T4) is recommended to assess overall metabolic function (if not already performed). Other considerations include the following:

**INVOICE**

22699

1. Urine culture and sensitivity
2. Urine BRAF test to further evaluate for lower urinary tract neoplasia
3. Three-view thoracic radiographs are recommended to assess for pulmonary metastases.
4. Depending on the results of the above diagnostics, consultation with a board-certified oncologist and/or additional work-up (i.e., cystoscopy with biopsies) may be warranted.

**DATE**

3-16-26



**PATIENT**

Blair Corrigan

**SPECIES**

Canine

**BREED**

Rottweiler Mix

**SEX**

Female Spayed

**AGE**

12

**WEIGHT**

27.5 kg

**INTERPRETED BY**

Andrea Nicastro, DVM,  
Diplomate ACVIM  
(Small Animal Internal  
Medicine)

**IMAGING  
PERFORMED BY**

Natalia Franco

**HOSPITAL NAME**

Eagleson VC

**REFERRING VET**

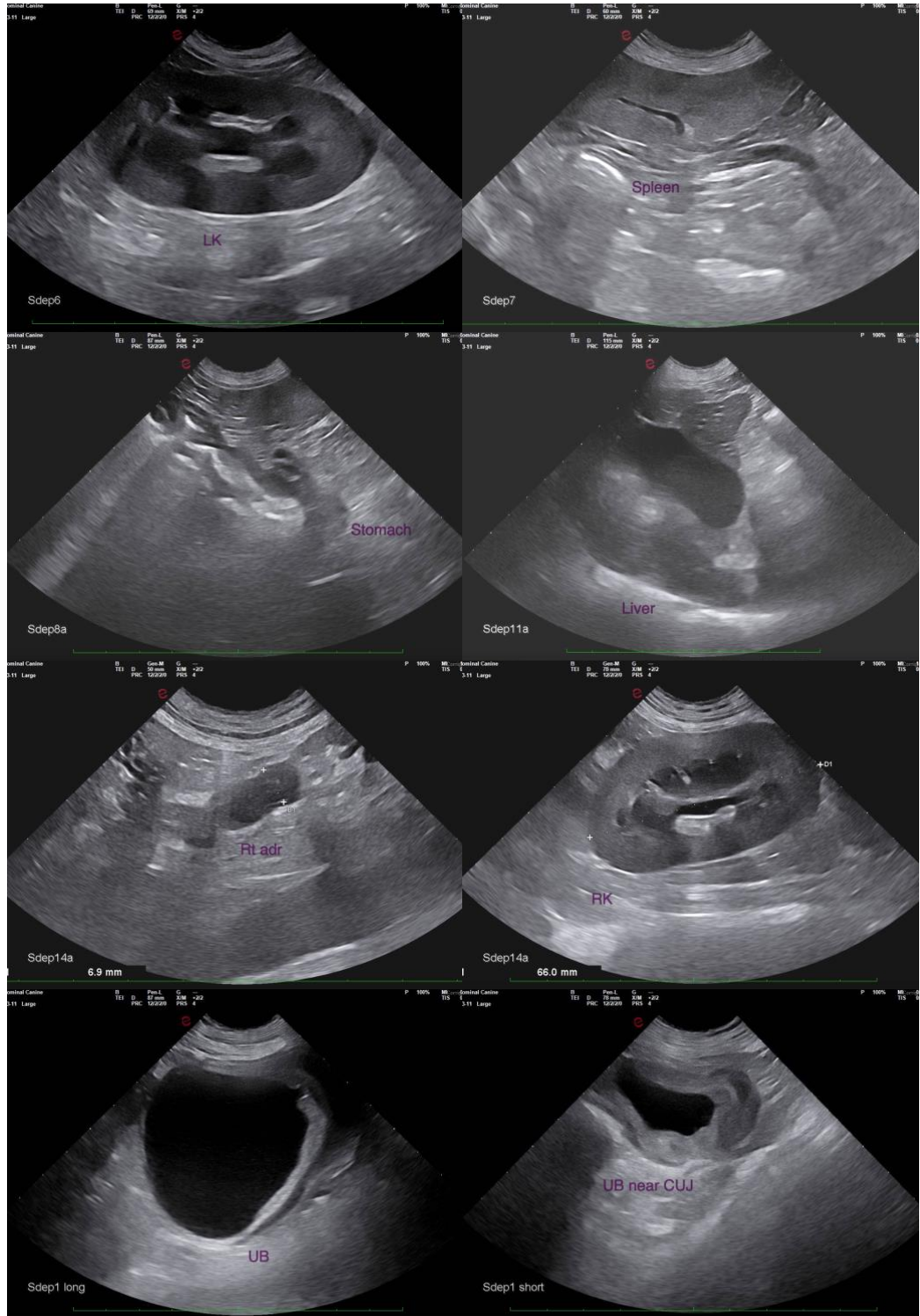
Mohamed Ammar

**INVOICE**

22699

**DATE**

3-16-26





## PATIENT

Blair Corrigan

## SPECIES

Canine

## BREED

Rottweiler Mix

## SEX

Female Spayed

## AGE

12

## WEIGHT

27.5 kg

## INTERPRETED BY

Andrea Nicastro, DVM,  
Diplomate ACVIM  
(Small Animal Internal  
Medicine)

## IMAGING PERFORMED BY

Natalia Franco

## HOSPITAL NAME

Eagleson VC

## REFERRING VET

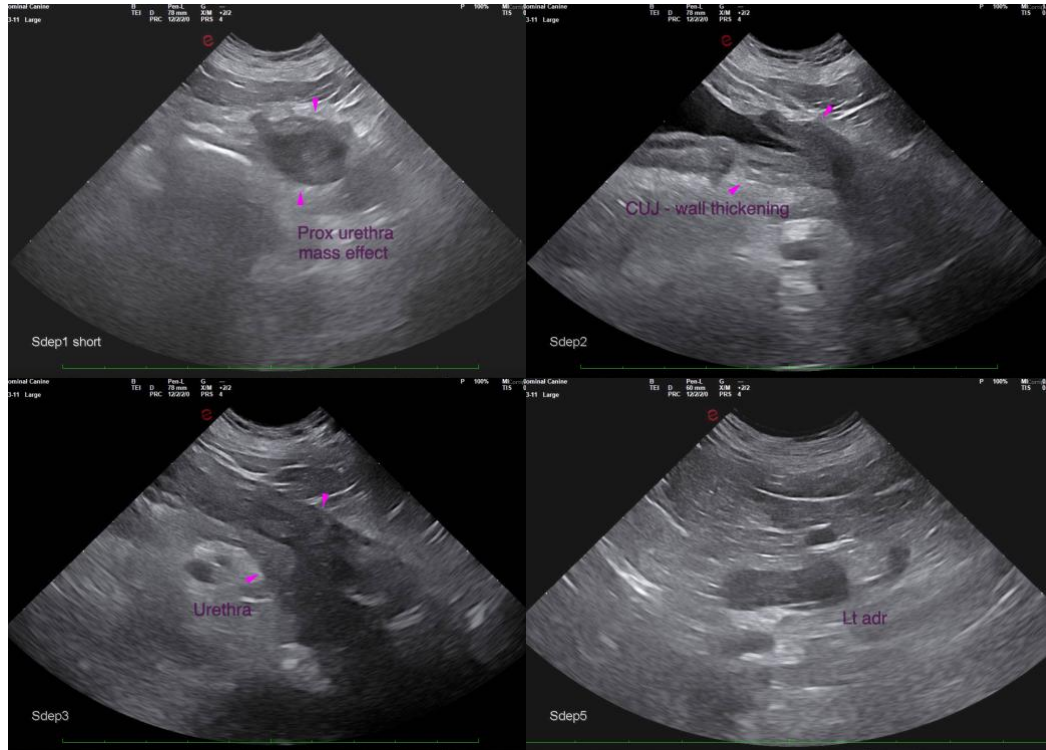
Mohamed Ammar

## INVOICE

22699

## DATE

3-16-26



The information and recommendations provided are based on the images presented by the referring veterinarian/sonographer. No evaluation can be communicated regarding pathology that was not visible in the image/video clips provided.

Thank you for this referral. If the clinical or image interpretation does not parallel your findings or if I can be of any further assistance, please contact me.

**Andrea Nicastro, MPH, DVM, Diplomate DACVIM (Small Animal Internal Medicine)**  
[info@SonoPath.com](mailto:info@SonoPath.com)