



PATIENT

Willie Tufts

PRESENTING CLINICAL SIGNS

History: gastroenteritis and a thickened gastric wall. Ulcerative disease versus tumor versus foreign body.

SPECIES

Canine

ULTRASONOGRAPHIC EXAMINATION OF THE ABDOMEN

Urinary System

The urinary bladder, trigone, and pelvic urethra are normal in thickness and the mucosal surface is smooth. The bladder lumen is moderately distended with anechoic urine. No masses, inflammatory changes or calculi are observed. Ureteral papillae and visualized portion of the proximal urethra, visible to a depth of 2 cm, are normal.

BREED

Maltese

SEX

Neutered Male

The prostate is normal in size (1.06 cm in width) and shape. Parenchyma is homogenous. The prostatic urethra appears normal without evidence of dilation or obstruction.

AGE

5 years

The left kidney presented normal size (3.80 cm in length); normal shape and architecture with smooth peripheral margins. There is a normal 1:3 cortex to medulla ratio with normal corticomedullary distinction. There is no evidence of pyelectasia, nephroliths, infarcts or hydronephrosis. Renal vasculature is normal.

WEIGHT

11 lbs

The right kidney presented normal size (3.61 cm in length); normal shape and architecture with smooth peripheral margins. There is a normal 1:3 cortex to medulla ratio with normal corticomedullary distinction. There is no evidence of pyelectasia, nephroliths, infarcts or hydronephrosis. Renal vasculature is normal.

INTERPRETED BY

Andrea Nicastro, DVM,
Diplomate ACVIM
(Small Animal Internal
Medicine)

Adrenal Glands

The left adrenal gland is normal size (0.39 cm at cranial pole) (0.32 cm at caudal pole) (1.14 cm in length); normal shape; homogenous parenchyma. The glandular echogenicity and detail are unremarkable. Capsule, cortex, and medullary definition are normal. The phrenicoabdominal vein and surrounding vasculature are normal.

IMAGING PERFORMED BY

Jenn

The right adrenal gland is normal size (0.82 cm at cranial pole) (0.54 cm at caudal pole) (1.29 cm in length); normal shape; homogenous parenchyma. The glandular echogenicity and detail are unremarkable. Capsule, cortex, and medullary definition are normal. The phrenicoabdominal vein and surrounding vasculature are normal.

HOSPITAL NAME

Rockaway AH

Spleen

The spleen is normal in size (1.38 cm in width at the level of the hilus) with a normal capsular contour. There is appropriate echogenicity and echotexture. No focal lesions are observed. Splenic vasculature is normal.

REFERRING VET

Dr. Manier

Liver

The liver is subjectively normal in size with normal contours and structure. There is appropriate echogenicity and echotexture. No overt structural evidence of inflammatory, infiltrative or regenerative pathology is evident. Vascular and biliary tracts are of normal volume with no evidence of congestion. No pathological hepatic lymphadenopathy observed.

INVOICE

10547

The gall bladder lumen is moderately distended. The wall is thin and smooth. Luminal contents are anechoic. The cystic and common bile ducts are normal.

DATE

3/16/22



PATIENT

Willie Tufts

Gastrointestinal

The gastric lumen is not distended. The gastric wall is normal in thickness with a normal layering pattern. The small intestinal lumen is not dilated. The small intestinal wall thickness is normal with a normal layering pattern and appropriate mural detail. Discreet masses are not identified. The colonic wall is normal. No obstructive or overt infiltrative disease is noted.

SPECIES

Canine

Pancreas

The region of the pancreas is isoechoic relative to surrounding omental fat. No obvious parenchymal abnormalities are observed. There is no evidence of regional inflammation or effusion.

BREED

Maltese

Free Abdomen

The peritoneal cavity is normal. There is no evidence of inflammation or effusion. The abdominal lymph nodes are normal/not visible.

SEX

Neutered Male

ULTRASONOGRAPHIC FINDINGS

AGE

5 years

Primary Findings

- Unremarkable abdomen. An obvious cause for the patient's clinical signs is not identified in this study.

WEIGHT

11 lbs

INTERPRETATION OF THE FINDINGS & FURTHER RECOMMENDATIONS

INTERPRETED BY

Andrea Nicastro, DVM,
Diplomate ACVIM
(Small Animal Internal
Medicine)

The following diagnostics/treatment recommendations can be considered:

IMAGING PERFORMED BY

Jenn

1. Serum cobalamin, folate, PLI and TLI
2. A fecal evaluation for ova/Giardia
3. Prophylactic deworming with Fenbendazole at 50 mg/kg once a day for 5 days is recommended. Repeat above protocol in 3 weeks.
4. A 6-week limited antigen diet trial to assess for food allergies.
5. Consider a 4-week course of Tylosin at 15-20 mg/kg by mouth every 12 hours as empirical treatment for small intestinal bacterial overgrowth.
6. A resting cortisol level to screen for hypoadrenocorticism. If resting cortisol level is < 2.0 mcg/dL, an ACTH stimulation test is recommended.
7. Depending on the results of the above diagnostics/therapeutics, endoscopic or surgical gastrointestinal biopsies may be warranted.
8. Three-view thoracic radiographs should be performed prior to any anesthetic event.

HOSPITAL NAME

Rockaway AH

REFERRING VET

Dr. Manier

INVOICE

10547

DATE

3/16/22



PATIENT

Willie Tufts

SPECIES

Canine

BREED

Maltese

SEX

Neutered Male

AGE

5 years

WEIGHT

11 lbs

INTERPRETED BY

Andrea Nicastro, DVM,
Diplomate ACVIM
(Small Animal Internal
Medicine)

**IMAGING
PERFORMED BY**

Jenn

HOSPITAL NAME

Rockaway AH

REFERRING VET

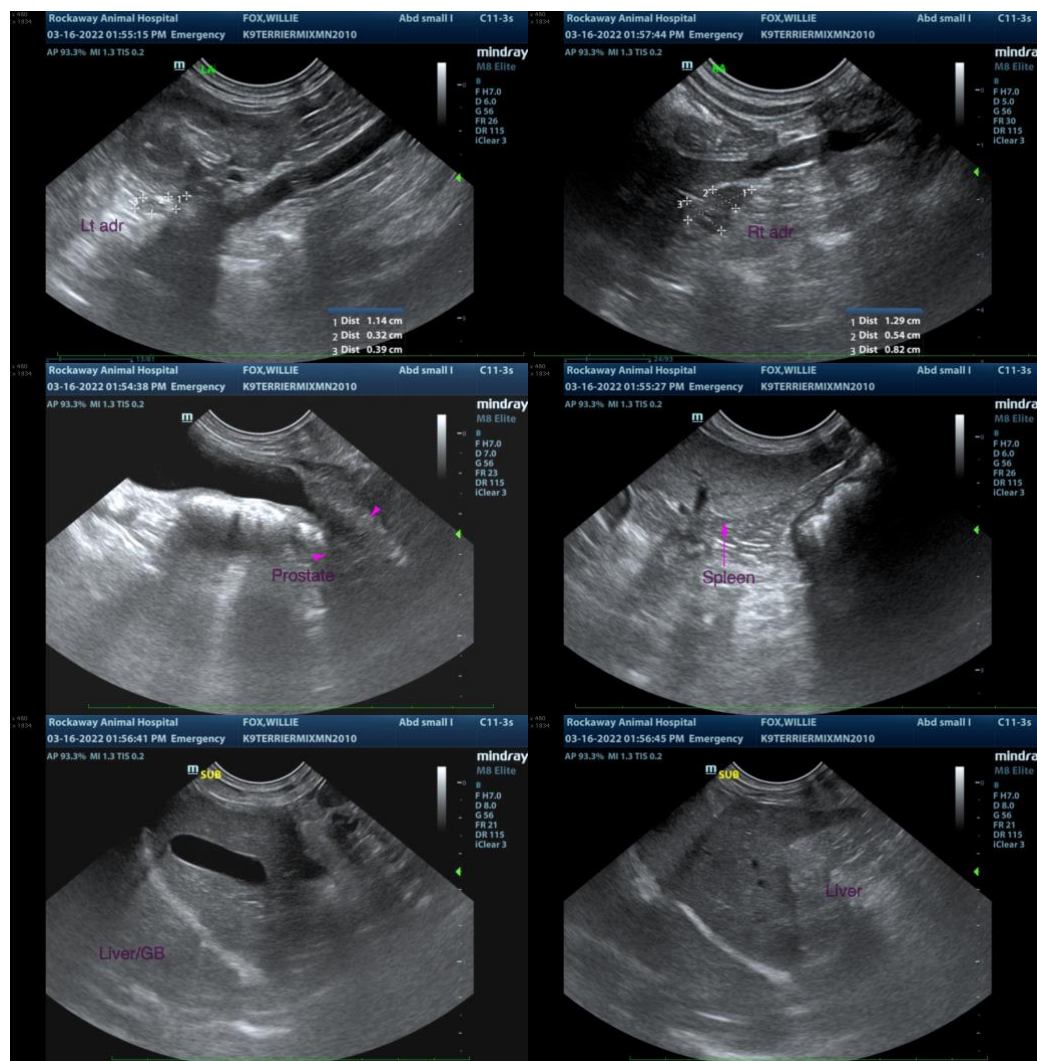
Dr. Manier

INVOICE

10547

DATE

3/16/22



The information and recommendations provided are based on the images presented by the referring veterinarian/sonographer. No evaluation can be communicated regarding pathology that was not visible in the image/video clips provided.

Thank you for this referral. If the clinical or image interpretation does not parallel your findings or if I can be of any further assistance, please contact me.

Andrea Nicastro, DVM, Diplomate DACVIM (Small Animal Internal Medicine)
info@SonoPath.com