

**DATE PRESENTING CLINICAL SIGNS**

3.15.2023

CC: vomits all over the basement every day. HX: owner feeds pet small amounts frequently now over past 6 months but does not help. PE: 10# weight loss since last seeing him in 2017. No other significant findings

PATIENT

Smokey Mathe

Current Medications: Mirataz: 1 mg SID since 03-06
 Lab Results: Slight increase in ALT (174) and AST. Creatinine kinase 4321. T4 normal.
 Date of Previous IntraPet Ultrasound: No previous.
 Sedation: Not required to complete full diagnostic ultrasound.
 Stat Report: Not requested.
 Imaging Performed By: Rachel Brillhart, RDMS.

SPECIES

Feline

ULTRASONOGRAPHIC EXAMINATION OF THE ABDOMEN**BREED**

DSH

Urinary System

The urinary bladder is mildly distended. The wall is normal in thickness with a smooth mucosal surface. A moderate amount of suspended echogenic debris is observed within the lumen. No cystic calculi are observed. The region of the trigone is normal.

SEX

Neutered Male

The left kidney is normal in size (3.53 cm in length) with a normal shape, architecture and smooth peripheral margins. There is a normal 1:3 cortex to medulla ratio with mild loss of corticomedullary distinction. The cortex is hyperechoic relative to the spleen. There is no evidence of pyelectasia, nephroliths, infarcts or hydroureter. Renal vasculature is normal.

AGE

8/19/2008

The right kidney is normal in size (3.77 cm in length) with a normal shape, architecture and smooth peripheral margins. There is a normal 1:3 cortex to medulla ratio with mild loss of corticomedullary distinction. A few hyperechoic shadowing diverticular foci are visualized. The cortex is hyperechoic relative to the spleen. There is no evidence of pyelectasia, nephroliths, infarcts or hydroureter. Renal vasculature is normal.

WEIGHT

7.75lbs

INTERPRETED BY

Andrea Nicastro,
 DMV, Diplomate
 DACVIM (Small
 Animal
 Internal Medicine)

Adrenal Glands

The left adrenal gland is normal in size (0.39 cm width). Normal shape and glandular echogenicity. The phrenicoabdominal vein and surrounding vasculature are normal.

The right adrenal gland is normal size (0.44 cm width). Normal shape and glandular echogenicity. The phrenicoabdominal vein and surrounding vasculature are normal.

HOSPITAL NAME

Harborside Mobile
 VC

Spleen

The spleen is contracted (0.50 cm in width at the level of the hilus) with normal curvilinear peripheral contours. The parenchyma is subjectively hypoechoic and homogenous in appearance. Splenic vasculature appears normal with no evidence of thrombosis.

REFERRING VET

Dr. Hawkins

Liver

The liver is subjectively enlarged with slightly swollen peripheral contours. The parenchyma is hyperechoic relative to the spleen and diffusely homogeneous in appearance. No distinct focal lesions are observed. Vascular and biliary tracts are of normal volume with no evidence of congestion. The portal vein to caudal vena cava ratio is approximately 1: 1.

INVOICE

12434

The gall bladder lumen is moderately distended. The wall is thin and smooth. A small to moderate amount of aggregated, echogenic, partially dependent debris/sludge is observed within the lumen. The cystic and common bile ducts are normal/not seen.

Gastrointestinal

The stomach and intestine are free of stasis and exhibit normal peristaltic activity. The gastric lumen is not distended. The gastric wall and pylorus are normal in thickness with a normal layering pattern. The pyloric outflow tract is patent. The small intestinal lumen is not dilated. The small intestinal wall thickness is normal with a normal layering pattern and appropriate mural detail. Discreet masses are not identified. The colonic wall is normal. There is no evidence of an obstructive pattern.

Pancreas

The base and limbs of the pancreas are visible with normal curvilinear peripheral contours. The parenchyma is largely mildly hypoechoic relative to surrounding omental fat and slightly mottled in appearance. The pancreatic duct is borderline dilated (0.25 cm in diameter). There is no evidence of peripancreatic inflammation or effusion.

Free Abdomen

There is no obvious evidence of free fluid. A few prominent mesenteric lymph nodes are visualized (the largest measuring 0.84 cm in length). A prominent cranial abdominal lymph node is also seen (0.62 cm in length).

ULTRASONOGRAPHIC FINDINGS

Primary Findings

- Hepatic changes are non-specific and could be consistent with hepatic lipidosis, inflammatory/infectious disease, infiltrative neoplasia, or other hepatopathy.
- The pancreatic changes are suggestive of chronic pancreatitis with suspected age-related remodeling.

Secondary Findings

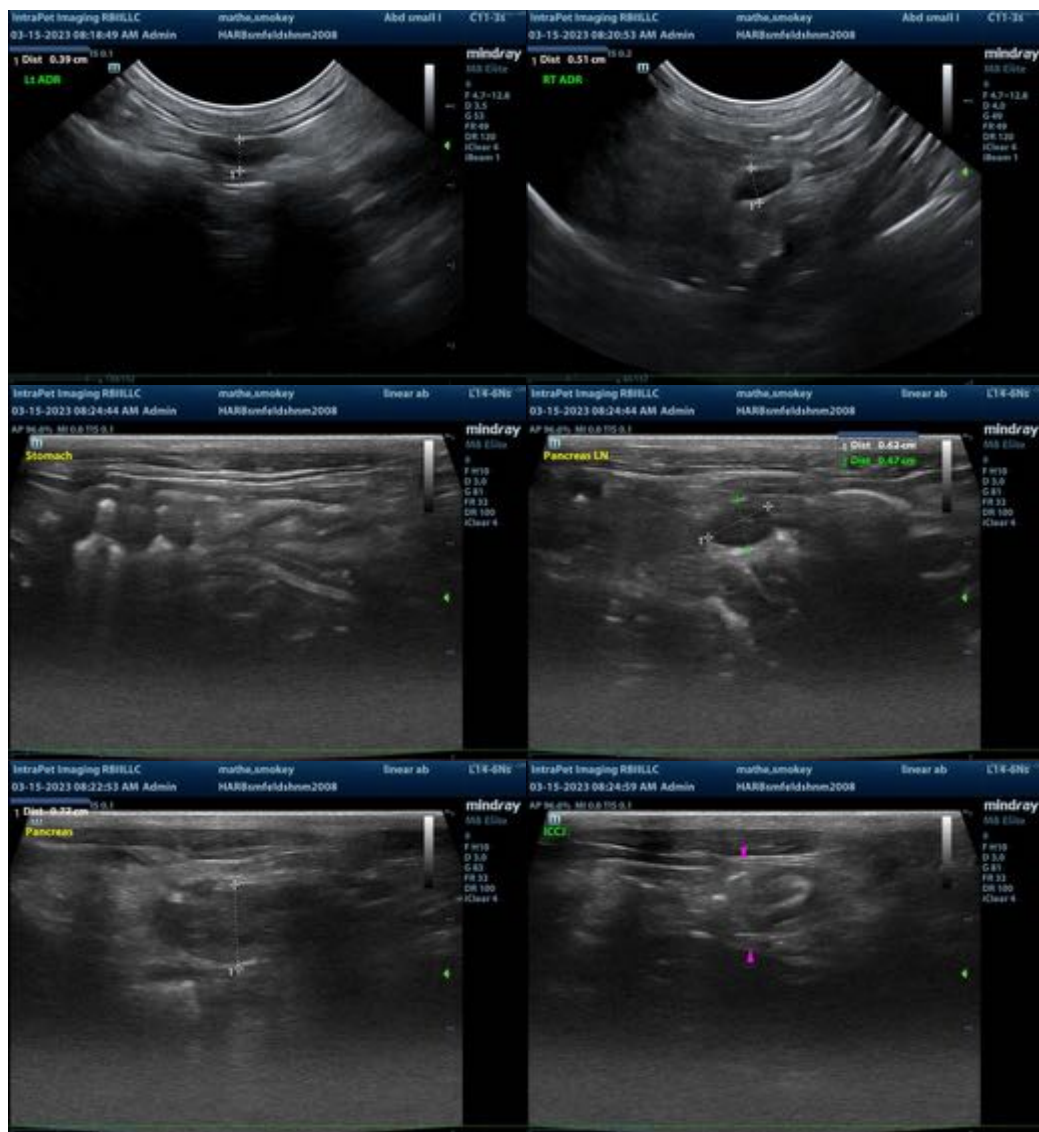
- The prominent abdominal lymph nodes are most consistent with reactive lymphadenitis or lymphoid hyperplasia. Neoplastic infiltration is considered less likely.
- Mild bilateral chronic renal changes with subtle right dystrophic mineralization
- Urinary bladder debris
- Splenic contraction, likely secondary to dehydration

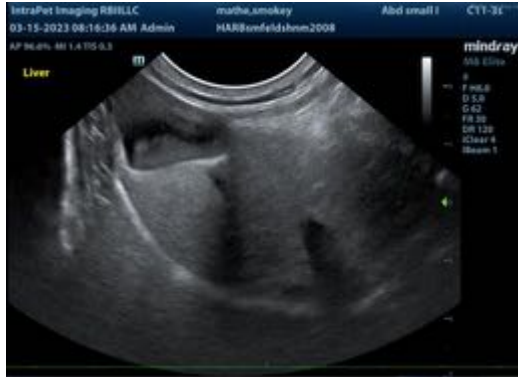*It is unclear whether the patient's clinical signs are secondary to underlying hepatic disease, pancreatic disease, microscopic gastrointestinal disease, occult neoplasia, or other underlying disease process.

INTERPRETATION OF THE FINDINGS & FURTHER RECOMMENDATIONS

- Three-view thoracic radiographs are recommended to assess for occult esophageal disease.
- Consider fecal evaluation for ova and Giardia, as well as a malabsorption panel, including serum cobalamin and folate, TLI and PLI.
- Also consider initiation of a limited antigen or hydrolyzed protein diet, along with a probiotic.

- A fine-needle aspirate of the liver can also be considered (if clotting status is appropriate). A 25-gauge needle should be used.
- Consider heartworm testing (i.e., antigenic stimulation and antibody), as heartworm disease can cause chronic vomiting in cats.
- Ultimately GI +/- liver biopsies may be necessary to get a definitive diagnosis.
- In the meantime, symptomatic care and nutritional support is recommended.





The information and recommendations provided are based on the images presented by the referring veterinarian/sonographer. No evaluation can be communicated regarding pathology that was not visible in the image/video clips provided.

Thank you for this referral. If the clinical or image interpretation does not parallel your findings or if I can be of any further assistance, please contact me.

Andrea Nicastro, DVM, Diplomate DACVIM (Small Animal Internal Medicine)
info@SonoPath.com