



PATIENT

Brody Peck

SPECIES

Canine

BREED

Yorkshire terrier

SEX

Male, neutered

AGE

15 Yrs.

WEIGHT

12.4 lbs.

INTERPRETED BY

Andrea Nicastro, DVM,
Diplomate ACVIM
(*Small Animal Internal
Medicine*)

**IMAGING
PERFORMED BY**

Dr. Bartus

HOSPITAL NAME

Valley VS

REFERRING VET

Dr. Bartus

INVOICE

13119

DATE

3/14/2022

PRESENTING CLINICAL SIGNS

History: PU/PD for about 3 months
Abnormal PE/Chem/CBC/UA Results: ALT 231 (10-125), ALKP 1391 (23-212), TP 8.5 (5.2-8.2), Glob 4.7 (2.5-4.5), HCT 36.3% (37.3-61.7%)

ULTRASONOGRAPHIC EXAMINATION OF THE ABDOMEN

Urinary System

The urinary bladder and visible portion of the pelvic urethra are normal for the degree of luminal distension. The urine is anechoic with no evidence of debris. Cystic calculi and discrete masses are not observed. The region of the trigone and the visible portion of the proximal urethra are normal.

The prostate is normal in size (0.85 cm in width) and shape. Parenchyma is homogenous. The prostatic urethra appears normal without evidence of dilation or obstruction.

The left kidney is normal size with normal shape and smooth peripheral contours. The cortex is mildly thickened and hyperechoic and there is mild to moderate loss of corticomedullary distinction. Mild to moderate pyelectasia is present (0.29 cm in the transverse plane). Several non-obstructive nephroliths are visualized. There is no evidence of infarcts or hydronephrosis.

The right kidney is normal in size with a normal shape, smooth peripheral margins and normal internal architecture. There is mild loss of corticomedullary distinction. Several hyperechoic shadowing diverticular foci are observed. Mild pyelectasia is present (0.24 cm in the transverse plane). 1-2 small nephroliths are visualized. There is no evidence of infarcts or hydronephrosis.

Adrenal Glands

The left adrenal gland is enlarged (0.54 cm at cranial pole) (0.73 cm at caudal pole). A 0.39 x 0.30 cm irregular hyperechoic nodule is observed at the cranial pole. The remaining parenchyma is mildly heterogeneous with some loss of glandular detail. The phrenicoabdominal vein and surrounding vasculature appear normal.

The right adrenal gland is upper limits of normal size (0.80 cm at cranial pole) (0.55 cm at caudal pole) (1.85 cm in length); normal shape; homogenous parenchyma. The glandular echogenicity and detail are unremarkable. Capsule, cortex, and medullary definition are normal. The phrenicoabdominal vein and surrounding vasculature are normal.

Spleen

The spleen is normal in size (0.82 cm in width at the level of the hilus) with a normal capsular contour. There is appropriate echogenicity and echotexture. Several small, irregular hyperechoic nodules are observed throughout the organ. Splenic vasculature is normal.

Liver

The liver is subjectively prominent to enlarged with rounded to irregular peripheral contours. The parenchyma is hypoechoic relative to the spleen and diffusely mottled and heterogeneous in appearance with a questionable mass effect in the left to mid liver. Vascular and biliary tracts are of normal volume with no evidence of congestion. The gall bladder lumen is moderately distended. The wall is thin and smooth. A small to moderate amount of aggregated echogenic partially dependent debris/sludge is observed within the lumen. The cystic and common bile ducts are normal/not seen.



PATIENT

Gastrointestinal

Brody Peck

The stomach and intestine are free of stasis and exhibit normal peristaltic activity. The gastric lumen is mildly fluid distended. The gastric wall and pylorus are normal in thickness with a normal layering pattern. The pyloric outflow tract is patent. The small intestinal lumen is not dilated. The small intestinal wall thickness is normal with a normal layering pattern and appropriate mural detail. Discreet masses are not identified. The colonic wall is normal. No obstructive disease is noted.

SPECIES

Canine

BREED

Yorkshire terrier

Pancreas

The region of the pancreas is isoechoic relative to surrounding omental fat. No obvious parenchymal abnormalities are observed. There is no evidence of regional inflammation or effusion.

SEX

Male, neutered

Free Abdomen

The peritoneal cavity is normal. There is no evidence of inflammation or effusion. The abdominal lymph nodes are normal/not visible.

AGE

15 Yrs.

ULTRASONOGRAPHIC FINDINGS

Primary Findings:

- The hepatic parenchymal changes could be consistent with infiltrative neoplasia (i.e., round cell tumor, adenocarcinoma). Alternatively, a benign process (i.e., regenerative nodular hyperplasia and/or vacuolar hepatopathy) may be present.
- Bilateral adrenomegaly, more pronounced on the left side. The left adrenal nodule is most consistent with benign nodular hyperplasia. However, an emerging tumor cannot be completely excluded.

Secondary Findings:

- Bilateral non-specific age-related renal changes with nephrocalcinosis and mild pyelectasia.
- The hyperechoic splenic nodules trend toward the benign (i.e., myelolipomas) with a low possibility of a neoplastic process.

*It is unclear whether the patient's clinical signs and abnormal liver values are due to a primary hepatopathy or Cushing's disease. Given the sonographic appearance of the liver, a hepatopathy is favored.

INTERPRETATION OF THE FINDINGS & FURTHER RECOMMENDATIONS

- Pre- and post-prandial serum bile acids are recommended to assess hepatic function. Hepatic tissue sampling (i.e., fine needle aspirate or surgical biopsy) may be necessary to get a definitive diagnosis. Surgical biopsies would be ideal in that they are more likely to represent global organ pathology. If biopsies are pursued, aerobic and anaerobic bile cultures and acquisition of additional hepatic tissue samples for potential copper quantitation are recommended. Three-view thoracic radiographs should be performed prior to any anesthetic event.
- Also consider further testing for Cushing's disease (i.e., low-dose dexamethasone suppression test or ACTH stimulation test).
- A urinalysis is also recommended to assess for isosthenuria.

INTERPRETED BY

Andrea Nicastro, DVM,
Diplomate ACVIM
(Small Animal Internal
Medicine)

IMAGING PERFORMED BY

Dr. Bartus

HOSPITAL NAME

Valley VS

REFERRING VET

Dr. Bartus

INVOICE

13119

DATE

3/14/2022



PATIENT

Brody Peck

SPECIES

Canine

BREED

Yorkshire terrier

SEX

Male, neutered

AGE

15 Yrs.

WEIGHT

12.4 lbs.

INTERPRETED BY

Andrea Nicastro, DVM,
Diplomate ACVIM
(Small Animal Internal
Medicine)

IMAGING PERFORMED BY

Dr. Bartus

HOSPITAL NAME

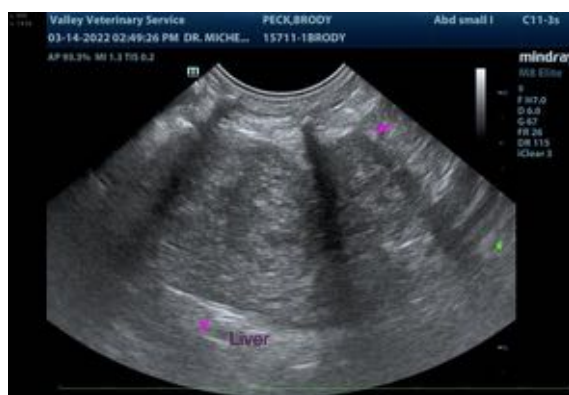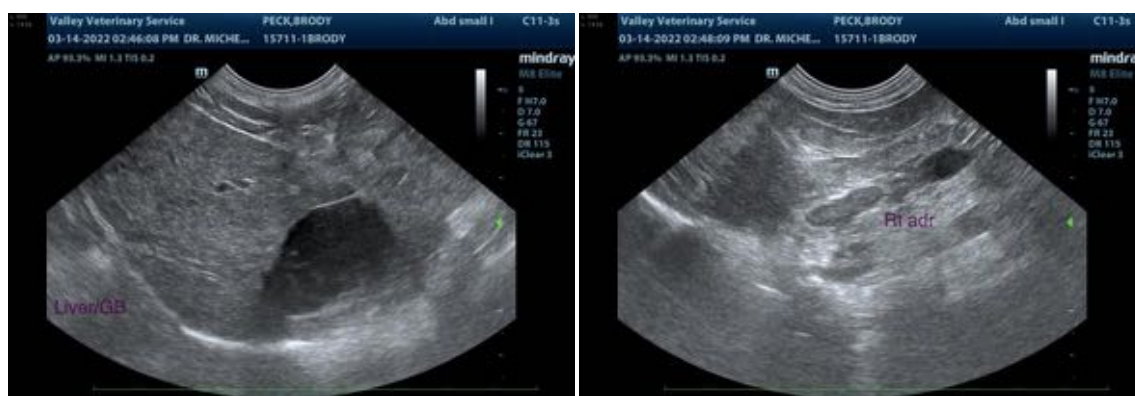
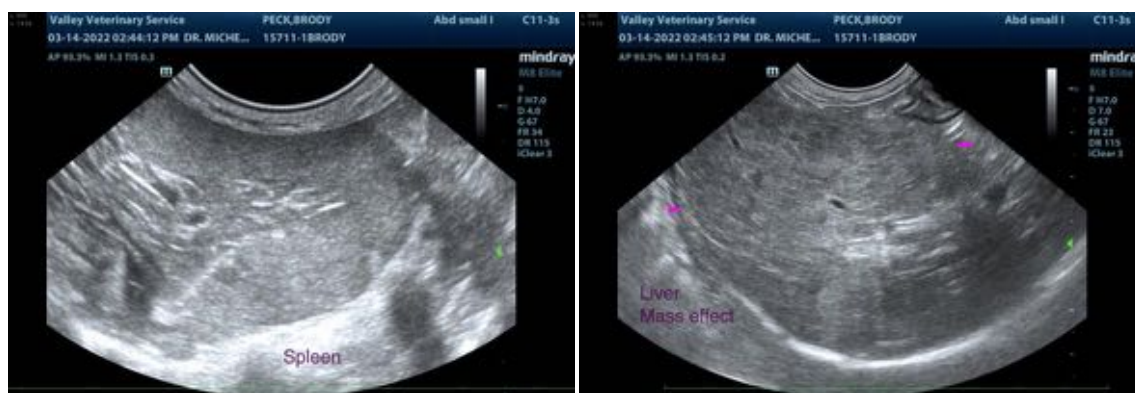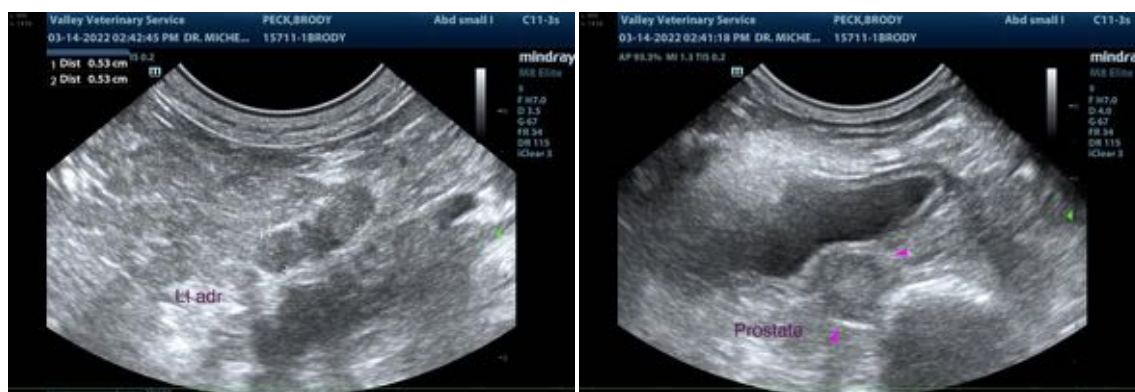
Valley VS

REFERRING VET

Dr. Bartus

INVOICE

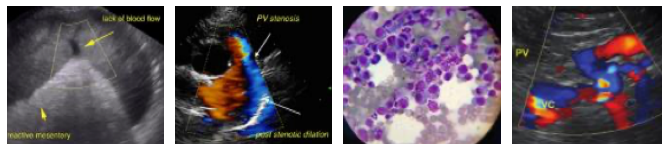
13119



The information and recommendations provided are based on the images presented by the referring

DATE

3/14/2022



PATIENT

Brody Peck

veterinarian/sonographer. No evaluation can be communicated regarding pathology that was not visible in the image/video clips provided.

Thank you for this referral. If the clinical or image interpretation does not parallel your findings or if I can be of any further assistance please contact me.

SPECIES

Canine

Andrea Nicastro, DVM, Diplomate ACVIM (*Small Animal Internal Medicine*)

BREED

Yorkshire terrier

Andrea.nicastro@sonopath.com

SEX

Male, neutered

AGE

15 Yrs.

WEIGHT

12.4 lbs.

INTERPRETED BY

Andrea Nicastro, DVM,
Diplomate ACVIM
(*Small Animal Internal
Medicine*)

**IMAGING
PERFORMED BY**

Dr. Bartus

HOSPITAL NAME

Valley VS

REFERRING VET

Dr. Bartus

INVOICE

13119

DATE

3/14/2022