**DATE PRESENTING CLINICAL SIGNS**

3/13/23

History of weight loss, labs from February show ALKP elevation and PSL elevation. AFAST today showed splenic mass.

**PATIENT**

Andy Squire

Current Medications: 3/10/23: convenia, gabapentin 50 mg BID, entyce 0.6 ml SID  
 Lab Results: AFAST: splenic tumor. 2/13/23 ALKP 468, PSL 718, amyl 1295, USG 1.022, 2+ protein.  
 Date of Previous IntraPet Ultrasound: No previous.  
 Sedation: Not required to complete full diagnostic ultrasound.  
 Stat Report: Not requested.  
 Imaging Performed By: Stephanie Warga RDCS, RVT.

**SPECIES**

Canine

**BREED**

Shih Tzu

**SEX**

Male, neutered

**AGE**

6/1/2007

**WEIGHT  
13.2 lbs.****ULTRASONOGRAPHIC EXAMINATION OF THE ABDOMEN****Urinary System**

The urinary bladder wall is normal in thickness and the mucosal surface is smooth. The bladder lumen is moderately distended with anechoic urine. No masses, inflammatory changes or calculi are observed. Ureteral papillae and visualized portion of the proximal urethra, visible to a depth of 1-2 cm, are normal.

The prostate is normal in size (0.99 cm in width) and shape. Parenchyma is homogenous. The prostatic urethra appears normal without evidence of dilation or obstruction.

The left kidney is normal size (3.63 cm in length) with a normal shape and smooth peripheral contours. The cortex is variably thickened and heterogeneous with pinpoint hyperechoic to mineralized foci. There poor corticomedullary distinction. A few small cortical cysts are present. Several non-obstructive nephroliths are visualized. Mild pyelectasia is present (0.20 cm in the longitudinal plane). There is no evidence of hydroureter. Renal vasculature is normal.

The right kidney is normal size (3.83 cm in length) with a normal shape and smooth peripheral contours. The cortex is variably thickened and heterogeneous with pinpoint hyperechoic to mineralized foci. There poor corticomedullary distinction. A few small cortical cysts are present. Several non-obstructive nephroliths are visualized. Mild pyelectasia is present (0.25 cm in the transverse plane). There is no evidence of hydroureter. Renal vasculature is normal.

**INTERPRETED BY**

Andrea Nicastro, DVM,  
 Diplomate ACVIM  
 (Small Animal Internal  
 Medicine)

**HOSPITAL NAME**

Everhart VH

**REFERRING VET**

Dr. Notarangelo

**INVOICE**

14727

**Adrenal Glands**

The left adrenal gland is mildly enlarged (0.62 cm at cranial pole) (0.57 cm at caudal pole) (1.81 cm in length); normal shape; homogenous parenchyma. The glandular echogenicity and detail are unremarkable. Capsule, cortex, and medullary definition are normal. The phrenicoabdominal vein and surrounding vasculature are normal.

The right adrenal gland is mildly enlarged (0.53 cm at cranial pole) (0.48 cm at caudal pole) (1.87 cm in length); normal shape; homogenous parenchyma. The glandular echogenicity and detail are unremarkable. Capsule, cortex, and medullary definition are normal. The phrenicoabdominal vein and surrounding vasculature are normal.

**Spleen**

The spleen is overall relatively normal in size (1.34 cm in width at the level of the hilus) with slightly irregular peripheral contours. A 2.25 x 1.59 cm irregular hypoechoic to heterogeneous cavitated mass is observed just cranial to the hilus. The lesion causes capsular expansion. In addition, a 0.92 x 0.45 cm hypoechoic nodule is seen. In the remainder of the spleen, the margins are curvilinear and the parenchyma is homogeneous. Splenic vasculature is normal with no evidence of thrombosis.

**Liver**

The liver is subjectively prominent in size with swollen curvilinear peripheral contours. The parenchyma is isoechoic relative to the spleen and exhibits mild heterogeneity. No distinct focal lesions are observed. Hepatic vasculature and biliary tracts are of normal volume with no evidence of congestion. The gall bladder lumen is moderately distended. The wall is thin and smooth. A moderate amount of echogenic to mineralized mostly gravity-dependent debris/sludge is observed within the lumen. The cystic and common bile ducts are normal/not seen.

### ***Gastrointestinal***

The stomach and intestine are free of stasis and exhibit normal peristaltic activity. The gastric lumen is not distended. The gastric wall and pylorus are normal in thickness with a normal layering pattern. The pyloric outflow tract is patent. The small intestinal lumen is not dilated. The small intestinal wall thickness is normal with a normal layering pattern and appropriate mural detail. Discreet masses are not identified. The colonic wall is normal. No obstructive disease is noted.

### ***Pancreas***

The region of the pancreas is isoechoic relative to surrounding omental fat. No obvious parenchymal abnormalities are observed. There is no evidence of regional inflammation or effusion.

### ***Free Abdomen***

There is no obvious evidence of free fluid. A few prominent lymph nodes are observed near the aortic trifurcation, the largest measuring 0.75 cm in diameter. Surrounding mesentery is hyperechoic.

### ***Other***

A brief echocardiogram reveals no evidence of pericardial effusion or obvious right atrial/auricular mass.

## **ULTRASONOGRAPHIC FINDINGS**

### **Primary Findings:**

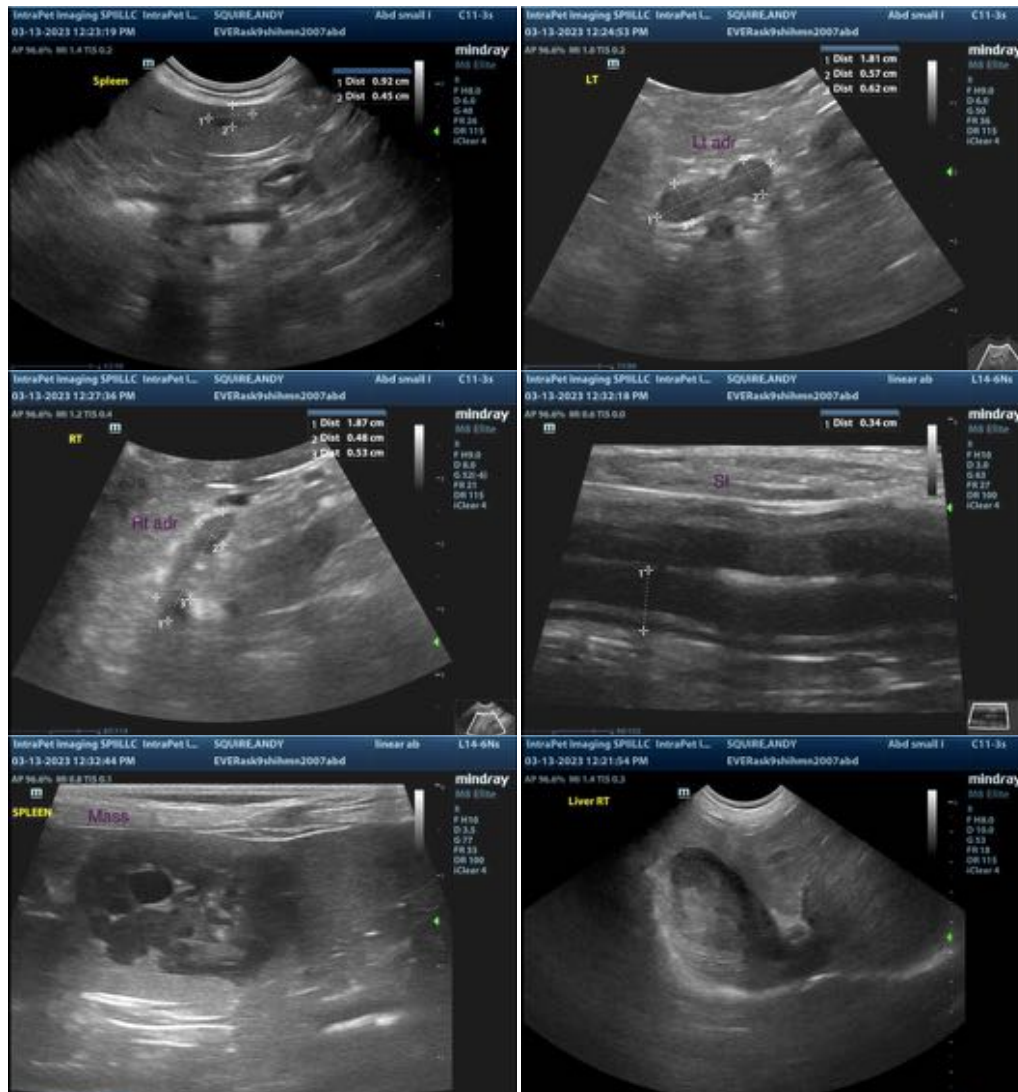- The splenic mass is concerning for a neoplastic process (i.e., sarcoma, round cell tumor, other). However, a benign lesion (i.e., inflammatory focus/abscess, other) cannot be completely excluded. The smaller hypoechoic splenic nodule trends toward the benign (i.e., focus of lymphoid hyperplasia or similar) but may represent a metastatic lesion.
- The caudal lymphadenopathy with adjacent peritonitis may represent reactive change or emerging neoplasia.

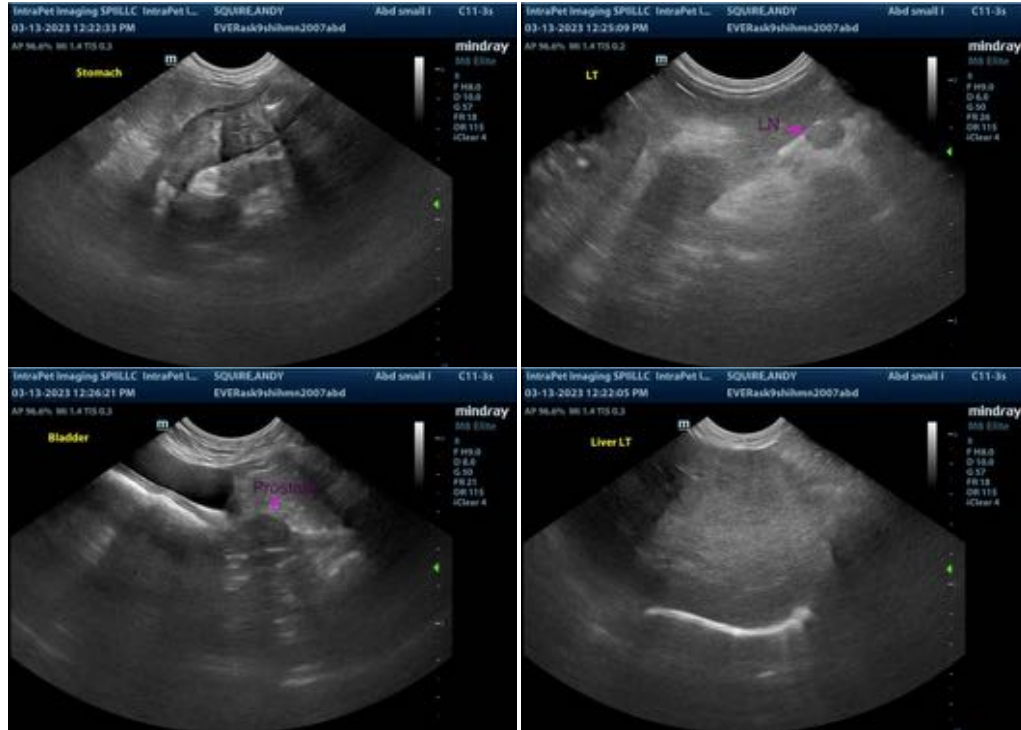
### **Secondary Findings:**

- The diffuse hepatic changes are non-specific and could be consistent with vacuolar hepatopathy, regenerative nodular hyperplasia, and/or age-related remodeling. Inflammatory and infiltrative disease are considered less likely.
- Gallbladder debris/sludge, non-mucocele.
- Mild left adrenomegaly.
- Bilateral, degenerative renal changes with dystrophic mineralization, pyelectasia and cortical cysts.

## **INTERPRETATION OF THE FINDINGS & FURTHER RECOMMENDATIONS**

- Given the splenic mass, three-view thoracic radiographs are recommended to assess for pulmonary metastatic disease. Also consider a fine needle aspirate of the splenic mass (if clotting status is appropriate). A 25-gauge needle should be used and care should be taken to avoid the cavitated areas. There is some risk of iatrogenic hemorrhage with the procedure. If aspiration is not pursued, consider splenectomy with submission of the spleen for histopathology. If surgery is performed, liver biopsies should also be obtained.
- Serial monitoring (i.e., every 3-4 months) of the patient's liver values is recommended. If liver values continue to increase, a repeat abdominal ultrasound +/- hepatic tissue sampling may be warranted, especially if it is not biopsied at this time.
- Consider testing for hyperadrenocorticism with a low-dose dexamethasone suppression test or ACTH stimulation test if clinical signs (i.e., PU/PD) develop in the future.





The information and recommendations provided are based on the images presented by the referring veterinarian. No evaluation can be communicated regarding pathology that was not visible in the image/video clips provided.

Thank you for this referral. If the clinical or image interpretation does not parallel your findings or if I can be of any further assistance please contact me.

Andrea Nicastro, MPH, DVM, Diplomate DACVIM (Small Animal Internal Medicine)  
info@SonoPath.com