



PATIENT

Ellie Willis

PRESENTING CLINICAL SIGNS

History of loose stools, which resolved with GI Biome diet. Prior fecals have been negative. Fecal PCR infectious disease panel also negative. GI panel unremarkable. Stools are now formed, but patient is still underweight. Has possibly been underfeeding until earlier this month.

SPECIES

Canine

ULTRASONOGRAPHIC EXAMINATION OF THE ABDOMEN

Urinary System

BREED

Labrador Retr

The urinary bladder, trigone, and pelvic urethra are normal in thickness and the mucosal surface is smooth. The bladder lumen is moderately distended with anechoic urine. No masses, inflammatory changes or calculi are observed. The region of the trigone and visible portion of the proximal urethra are normal.

SEX

Female Intact

The left kidney is normal in size (5.95 cm in length) with a normal shape, architecture and smooth peripheral margins. There is a normal 1:3 cortex to medulla ratio with normal corticomedullary distinction. There is no evidence of pyelectasia, nephroliths, infarcts or hydronephrosis. Renal vasculature is normal.

AGE

1 year

The right kidney is normal in size (6.21 cm in length) with a normal shape, architecture and smooth peripheral margins. There is a normal 1:3 cortex to medulla ratio with normal corticomedullary distinction. There is no evidence of pyelectasia, nephroliths, infarcts or hydronephrosis. Renal vasculature is normal.

WEIGHT

NP

Adrenal Glands

The left adrenal gland is normal to slightly flattened (0.46 cm at cranial pole) (0.43 cm at caudal pole); with smooth peripheral contours; homogenous parenchyma. The glandular echogenicity and detail are unremarkable. Capsule, cortex, and medullary definition are normal. The phrenicoabdominal vein and surrounding vasculature are normal.

INTERPRETED BY

Andrea Nicastro, DVM,
Diplomate ACVIM (*Small
Animal Internal Medicine*)

The right adrenal gland is normal size (0.51 cm at cranial pole) (0.50 cm at caudal pole); normal shape; homogenous parenchyma. The glandular echogenicity and detail are unremarkable. Capsule, cortex, and medullary definition are normal. The phrenicoabdominal vein and surrounding vasculature are normal.

**IMAGING
PERFORMED BY**

Andrea Nicastro, DVM,
Diplomate ACVIM (*Small
Animal Internal Medicine*)

Spleen

The spleen is normal in size (1.66 cm in width at the level of the hilus) with a normal capsular contour. There is appropriate echogenicity and echotexture. No focal lesions are observed. Splenic vasculature is normal.

HOSPITAL NAME

West Ashley VC

Liver

The liver is subjectively normal in size with normal contours and structure. There is appropriate echogenicity and echotexture. No overt structural evidence of inflammatory, infiltrative, or regenerative pathology is evident. Vascular and biliary tracts are of normal volume with no evidence of congestion. No pathological hepatic lymphadenopathy observed.

REFERRING VET

Dr. Grayson Hudgins

The gall bladder lumen is moderately distended. The wall is thin and smooth. Luminal contents are anechoic. The cystic and common bile ducts are normal/not seen.

INVOICE

12383

Gastrointestinal

The gastric lumen is moderate distended with ingesta. The gastric wall and pylorus are normal in thickness with a normal layering pattern. The pyloric outflow tract appears patent. The small intestinal lumen is segmentally dilated with chyme. The small intestinal wall thickness is normal with a normal layering pattern and appropriate mural detail. Discreet masses are not identified. The colonic wall is normal. There is no evidence of an obstructive pattern.

DATE

3.10.23

Pancreas

A portion of the pancreas is obscured by the gastric distention. In the visualized portion no obvious abnormalities are seen.

Free Abdomen

The peritoneal cavity is normal. There is no evidence of inflammation or effusion. The abdominal lymph nodes are normal/not visible.

Other

A brief echocardiogram reveals no evidence of pericardial effusion or obvious right atrial/auricular mass.

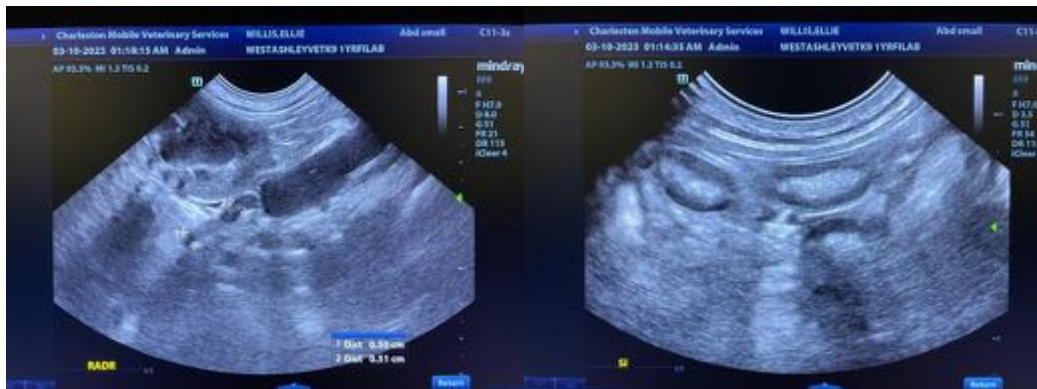
ULTRASONOGRAPHIC FINDINGS

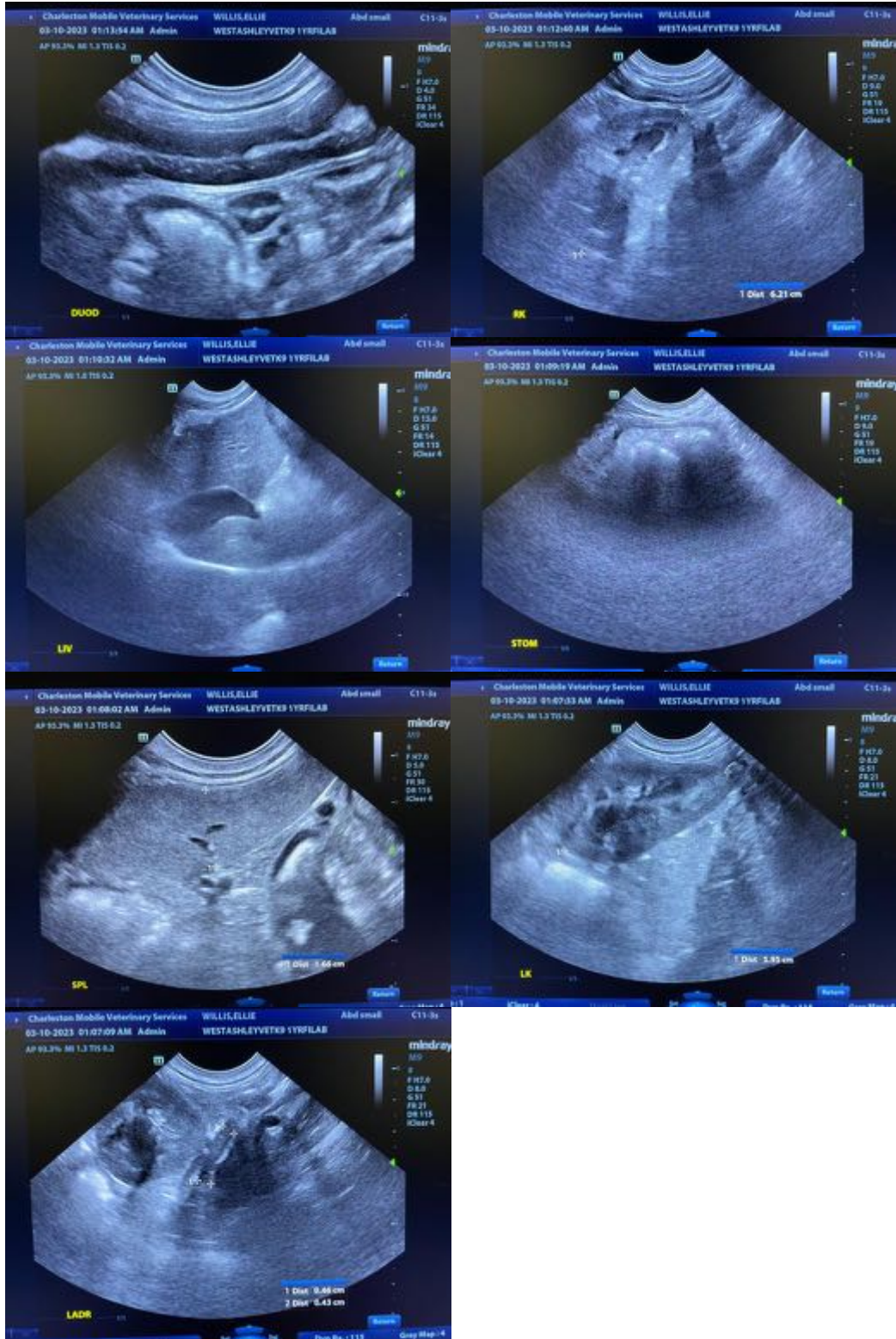
Findings

- The questionably flat left adrenal gland may be a normal variant for this patient or may be secondary to early atrophy (i.e., due to atypical hypoadrenocorticism).
- If the patient was fasted for this study, the presence of ingesta within the gastric lumen could suggest delayed gastric emptying.
- The abdomen is otherwise unremarkable.

INTERPRETATION OF THE FINDINGS & FURTHER RECOMMENDATIONS

- Consider a resting cortisol level to screen for atypical hypoadrenocorticism.
- Also consider rechecking the patient's weight in 4-6 weeks. If the patient is still not of adequate weight and the resting cortisol level is normal, GI biopsies (i.e., endoscopic or surgical) may be necessary to get a definitive diagnosis.





The information and recommendations provided are based on the images presented by the referring veterinarian/sonographer. No evaluation can be communicated regarding pathology that was not visible in the image/video clips provided.

Thank you for this referral. If the clinical or image interpretation does not parallel your findings or if I can be of any further assistance, please contact me.

Andrea Nicastro, DVM, Diplomate DACVIM (Small Animal Internal Medicine)
info@SonoPath.com