



PATIENT

Ruby McWilliam

SPECIES

Canine

BREED

Australian shepherd

SEX

Female

AGE

6 Months

WEIGHT

16.2 kg

INTERPRETED BY

Andrea Nicastro, DVM,
Diplomate ACVIM
(*Small Animal Internal
Medicine*)

**IMAGING
PERFORMED BY**

Dr. Gumley

HOSPITAL NAME

Cedarview AH

REFERRING VET

Dr. Gumley

INVOICE

13062

DATE

3/1/22

PRESENTING CLINICAL SIGNS

History: Recurrent urinary tract infections. Hematuria and dysuria noticed first 20 Dec 2021.
Abnormal PE/Chem/CBC/UA Results: Proteus mirabilis cultured in December and resolved with antibiotics but recurred with repeated culture. Vaginocopy - narrow vestibule, follicular vaginitis, cingulum diameter 10 mm.

ULTRASONOGRAPHIC EXAMINATION OF THE ABDOMEN

**This study was limited to the urinary bladder. There is a potential for pathology in organs that were not visualized.

***This study was submitted in conjunction with a study of the urinary tract performed on 1/6/22.

Urinary Bladder

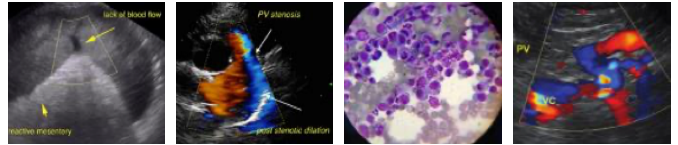
The urinary bladder is mildly distended. The ventral wall is thickened (up to 0.77 cm) and irregular. A small amount of echogenic debris, mineralized sand +/- tiny calculi is observed within the lumen.

ULTRASONOGRAPHIC FINDINGS

- Echogenic debris/mineralized sand with evidence of cystitis, which appears more severe compared to the study performed on 1/6/22.

INTERPRETATION OF THE FINDINGS & FURTHER RECOMMENDATIONS

- A repeat urine culture is recommended once the patient has been off antibiotics for 5-7 days. The urine sample should be collected via cystocentesis. A prolonged antibiotic course (i.e., 3-4 weeks) may be warranted if the infection is still present. Consider a repeat urine culture halfway through the antibiotic course and again 5-7 days after the last dose of antibiotics.
- If crystalluria is evident on the urinalysis, consider a prescription urinary diet.
- Baseline labwork including a CBC and chemistry panel is also recommended to assess for evidence of underlying metabolic dysfunction.
- Also consider supplementation with Cranainidin.



PATIENT

Ruby McWilliam

SPECIES

Canine

BREED

Australian shepherd

SEX

Female

AGE

6 Months

WEIGHT

16.2 kg

INTERPRETED BY

Andrea Nicastro, DVM,
Diplomate ACVIM
(*Small Animal Internal
Medicine*)

**IMAGING
PERFORMED BY**

Dr. Gumley

HOSPITAL NAME

Cedarview AH

REFERRING VET

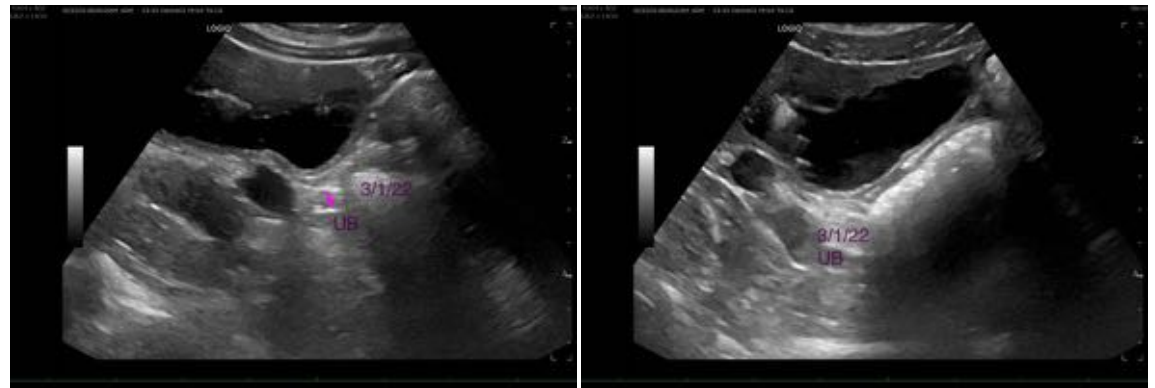
Dr. Gumley

INVOICE

13062

DATE

3/1/22



The information and recommendations provided are based on the images presented by the referring veterinarian/sonographer. No evaluation can be communicated regarding pathology that was not visible in the image/video clips provided.

Thank you for this referral. If the clinical or image interpretation does not parallel your findings or if I can be of any further assistance please contact me.

Andrea Nicastro, DVM, Diplomate ACVIM (*Small Animal Internal Medicine*)

Andrea.nicastro@sonopath.com