

**PATIENT**

Luna Kushner

**SPECIES**

Canine

**BREED**

Mixed Breed K9

**SEX**

Spayed Female

**AGE**

4 years

**WEIGHT**

54.8 lbs

**INTERPRETED BY**

Andrea Nicastro, DVM,  
Diplomate ACVIM  
(Small Animal Internal  
Medicine)

**IMAGING  
PERFORMED BY**

Kelly Vazquez

**HOSPITAL NAME**

Westwood Regional VH

**REFERRING VET**

Dr. Hartwick

**INVOICE**

10816

**DATE**

4/27/22

**PRESENTING CLINICAL SIGNS**

History: Ongoing excessive licking of vaginal area "for a year" - no other itch. UTI treated in Feb at other DVM. Possible leaking on bed vs. saliva from licking. No dermatitis, minimally recessed vulva. No PU/PD, not itching. History of sensitive gut (R/O underlying primary GI disease/IBD vs. other). R/O urethral sphincter issue. Current meds: Proin trial - stopped/vomiting.

Abnormal PE/Chem/CBC/UA Results: CBC/Chem: WNL. U/A: PH 8.0, WBC 2-3/HPF, protein 1+, struvites, USG 1.045. Urine C & S = negative.

**ULTRASONOGRAPHIC EXAMINATION OF THE ABDOMEN**

**Urinary System**

The urinary bladder, trigone, and pelvic urethra are normal in thickness and the mucosal surface is smooth. The bladder lumen is mildly distended with anechoic urine. No masses, inflammatory changes or calculi are observed. Ureteral papillae and visualized portion of the proximal urethra, visible to a depth of 2 cm, are normal.

The left kidney presented normal size (5.58 cm in length); normal shape and architecture with smooth peripheral margins. There is a normal 1:3 cortex to medulla ratio with normal corticomedullary distinction. There is no evidence of pyelectasia, nephroliths, infarcts or hydroureter. Renal vasculature is normal.

The right kidney presented normal size (4.83 cm in length); normal shape and architecture with smooth peripheral margins. There is a normal 1:3 cortex to medulla ratio with normal corticomedullary distinction. There is no evidence of pyelectasia, nephroliths, infarcts or hydroureter. Renal vasculature is normal.

**Adrenal Glands**

There are no images provided of the left adrenal gland.

The right adrenal gland is normal size (0.36 cm at cranial pole) (0.42 cm at caudal pole) (1.46 cm in length); normal shape; homogenous parenchyma. The glandular echogenicity and detail are unremarkable. Capsule, cortex, and medullary definition are normal. The phrenicoabdominal vein and surrounding vasculature are normal.

**Spleen**

The spleen is normal in size (2.33 cm in width at the level of the hilus) with a normal capsular contour. There is appropriate echogenicity and echotexture. No focal lesions are observed. Splenic vasculature is normal.

**Liver**

The liver is subjectively normal in size with normal contours and structure. There is appropriate echogenicity and echotexture. No overt structural evidence of inflammatory, infiltrative or regenerative pathology is evident. Vascular and biliary tracts are of normal volume with no evidence of congestion. No pathological hepatic lymphadenopathy observed.

The gall bladder lumen is moderately distended. The wall is thin and smooth. Luminal contents are anechoic. The cystic and common bile ducts are normal.

**Gastrointestinal**

The stomach and intestine are free of stasis and exhibit normal peristaltic activity. The gastric lumen is not distended. The gastric wall and pylorus are normal in thickness with a normal layering pattern. The small intestinal lumen is not dilated. The small intestinal wall thickness is normal with a normal layering pattern

and appropriate mural detail. Discreet masses are not identified. The colonic wall is normal. No obstructive or overt infiltrative disease is noted.

### **Pancreas**

The region of the pancreas is isoechoic relative to surrounding omental fat. No obvious parenchymal abnormalities are observed. There is no evidence of regional inflammation or effusion.

### **Free Abdomen**

The peritoneal cavity is normal. There is no evidence of inflammation or effusion. The abdominal lymph nodes are normal/not visible.

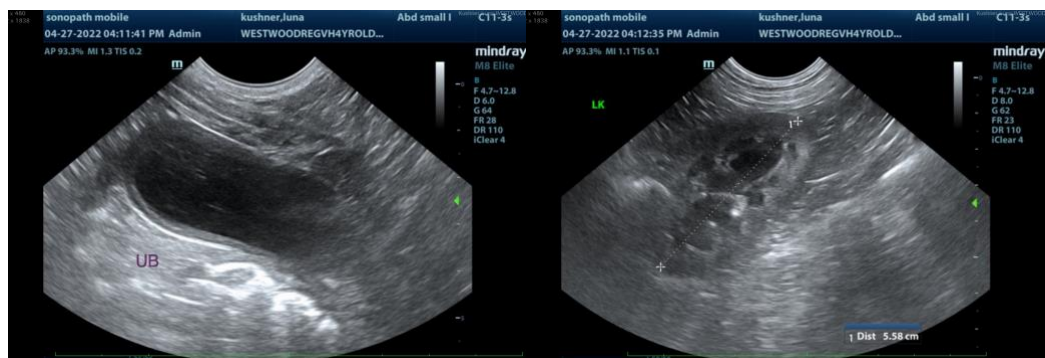
## **ULTRASONOGRAPHIC FINDINGS**

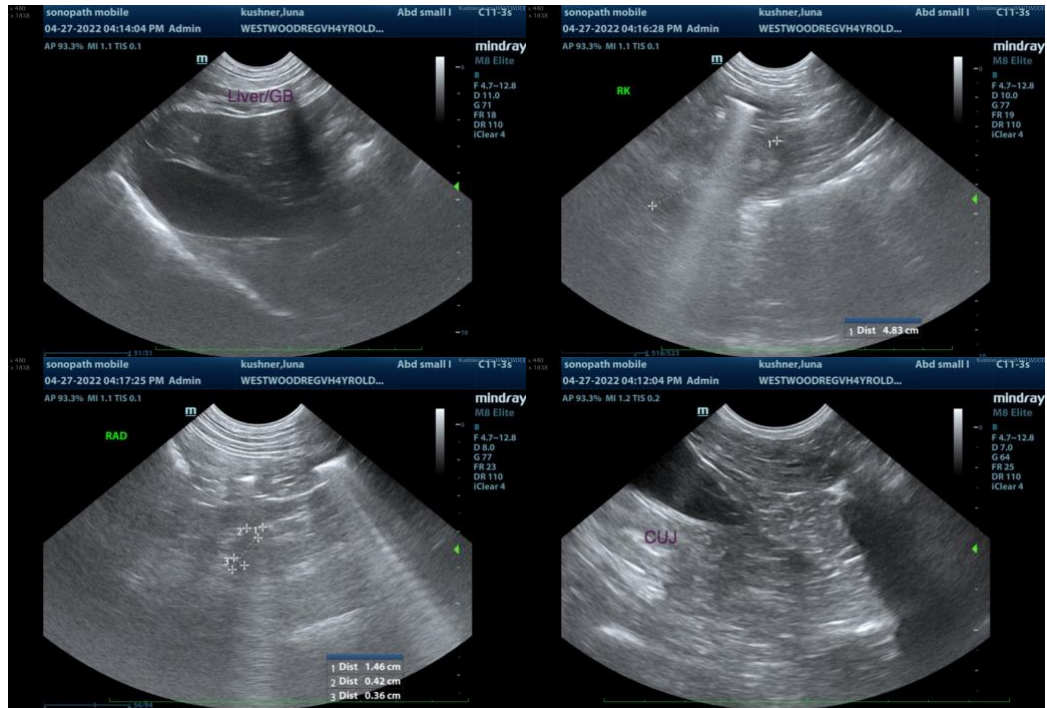
### **Primary Findings**

Unremarkable abdomen. An obvious cause for the patient's clinical signs is not identified in this study. Considerations include urethral sphincter mechanism incompetence, vaginitis, vaginal foreign body or tumor, occult urinary tract infection, allergic skin disease, other.

## **INTERPRETATION OF THE FINDINGS & FURTHER RECOMMENDATIONS**

- Given the proteinuria, a UPC is recommended.
- A vaginal exam is recommended to assess for evidence of tumors/polyps and foreign bodies.
- Consider a repeat course of broad-spectrum antibiotics, particularly if the patient had a response to the initial course of treatment. If no response to antibiotics or phenylpropanolamine is seen, consider referral to a board-certified dermatologist for further evaluation.





The information and recommendations provided are based on the images presented by the referring veterinarian/sonographer. No evaluation can be communicated regarding pathology that was not visible in the image/video clips provided.

Thank you for this referral. If the clinical or image interpretation does not parallel your findings or if I can be of any further assistance, please contact me.

**Andrea Nicastro, DVM, Diplomate DACVIM (Small Animal Internal Medicine)**  
info@SonoPath.com