



DATE

2-9-26

PATIENT

Grimm Hodge

SPECIES

Canine

BREED

Rottweiler

SEX

Female Spayed

AGE

88.7 lbs

WEIGHT

8/1/2017

INTERPRETED BY

Andrea Nicastro,
DVM, Diplomate
ACVIM (Small Animal
Internal Medicine)

HOSPITAL NAME

Animal EH

REFERRING VET

Dr. Ruby

INVOICE

22538

PRESENTING CLINICAL SIGNS

Patient History: Grimm Hodge presents for difficulty ambulating, decreased appetite, and persistent diarrhea. Patient History: - Persistent diarrhea since approximately 1/26; initially bloody, later lighter in color and not bloody. - Bloody diarrhea noted 1/28; pancreatitis test negative but close to positive; treated as presumptive pancreatitis. - Completed antibiotic course (unspecified), currently on gabapentin and probiotic (Provable). - Refusing Hill's Science Diet low-fat prescription food; eating small amounts, attempted wet food. - Drinking excessive water. - Weight loss noted; harness now two sizes larger. - Vomiting/diarrhea episode in car en route; foul odor, unclear if vomit or diarrhea. - Neurological signs: loss of control in pelvic limbs, ataxia, nystagmus observed at home. No coughing or sneezing reported. - No other dogs in household affected.
Current medications: - Gabapentin - Probiotic (Provable) -Completed antibiotic course (unspecified)

Current Medications: None listed, see above.

Labwork Results: CBC shows a mild lymphopenia. Low BUN. (Labwork attached).

Date of Previous IntraPet Ultrasound: No previous.

Sedation: IV Propofol.

Stat Report: STAT requested.

Imaging Performed by: Rachel Brillhart, RDMS.

ULTRASONOGRAPHIC EXAMINATION OF THE ABDOMEN

Urinary System

The urinary bladder wall is normal in thickness. The mucosal surface is smooth. The bladder is moderately distended. Luminal contents are mostly anechoic. No cystic calculi are observed. The region of the trigone and visible portion of the proximal urethra are normal.

The left kidney is normal in size (7.21 cm in length) with a normal shape, architecture and smooth peripheral margins. There is a normal 1:3 cortex to medulla ratio with normal corticomedullary distinction. Mild pyelectasia is present (0.21 cm in the transverse plane). There is no evidence of nephroliths, infarcts or hydroureter. Renal vasculature is normal.

The right kidney is normal in size (6.31 cm in length) with a normal shape, architecture and smooth peripheral margins. There is a normal 1:3 cortex to medulla ratio with normal corticomedullary distinction. There is no evidence of pyelectasia, nephroliths, infarcts or hydroureter. Renal vasculature is normal.

Adrenal Glands

The left adrenal gland is normal in size (0.69 cm at cranial pole) (0.80 cm at caudal pole) with a normal shape and homogenous parenchyma. The glandular echogenicity and detail are unremarkable. Capsule, cortex, and medullary definition are normal. The phrenicoabdominal vein and surrounding vasculature are normal.

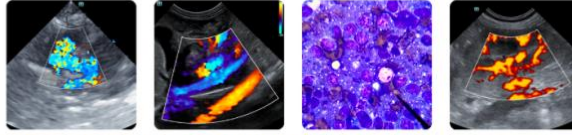
The right adrenal gland is normal in size (0.76 cm at cranial pole) (0.64 cm at caudal pole) with a normal shape and homogenous parenchyma. The glandular echogenicity and detail are unremarkable. Capsule, cortex, and medullary definition are normal. The phrenicoabdominal vein and surrounding vasculature are normal.

Spleen

The spleen is subjectively normal in size (2.03 cm in width at the level of the hilus) with smooth peripheral contours. The parenchyma is diffusely mottled in appearance. Several, small, ill-defined hypoechoic nodules are observed throughout the organ. Splenic vasculature appears normal with no evidence of thrombosis.

Liver

The liver is subjectively normal in size with normal contours and structure. There is appropriate



DATE

2-9-26

echogenicity and echotexture. No overt structural evidence of inflammatory, infiltrative, or regenerative pathology is evident. Vascular and biliary tracts are of normal volume with no evidence of congestion.

PATIENT

Grimm Hodge

The gallbladder is of normal contours and contains some dependent echogenic debris. The wall is normal in thickness. No choleliths are observed. The cystic and common bile ducts are normal/not seen.

SPECIES

Canine

Gastrointestinal

The gastric lumen is mildly distended with ingesta. The gastric wall is normal in thickness with a normal layering pattern. The small intestinal lumen is not overtly dilated. Several areas of small intestinal wall are thickened (up to 2.1 cm). In some regions, there is loss of the normal layering pattern. The wall in the region of the ileocecolic junction is thickened (up to 0.63 cm) with questionable retention of the normal layering pattern. There is no obvious evidence of an obstructive pattern.

BREED

Rottweiler

Pancreas

The right limb of the pancreas is visible with normal curvilinear peripheral contours. The parenchyma is largely hyperechoic relative to surrounding omental fat and slightly heterogenous in appearance. The pancreatic duct is visible but not overtly dilated. There is no evidence of peripancreatic inflammation or effusion.

SEX

Female Spayed

Lymph Nodes

Several, enlarged, rounded hypoechoic mesenteric lymph nodes are visualized (one measuring 2.9 x 1.8 cm). Surrounding mesentery is hyperechoic. In addition, a 2.2 x 1.6 cm hypoechoic, irregular, sublumbar lymph node is seen.

AGE

88.7 lbs

Free Abdomen

A brief echocardiogram reveals no obvious evidence of pericardial or pleural effusion in the visible window. No obvious intracardiac masses are seen in the available images.

WEIGHT

8/1/2017

Other

A brief echocardiogram reveals no evidence of pericardial effusion or obvious right atrial/auricular mass.

INTERPRETED BY

Andrea Nicastro,
DVM, Diplomate
ACVIM (Small Animal
Internal Medicine)

ULTRASONOGRAPHIC FINDINGS

Primary Findings

- The bowel wall changes are concerning for infiltrative neoplasia (i.e., lymphoma) with a lower possibility of a multifocal inflammatory process.
- The abdominal lymphadenopathy is also concerning for infiltrative neoplasia (i.e., lymphoma) with a lower possibility of lymphadenitis or lymphoid hyperplasia.
- The splenic parenchymal changes could be consistent with infiltrative neoplasia (i.e., lymphoma) or a benign process (i.e., lymphoid hyperplasia, extramedullary hematopoiesis, splenitis, antigenic stimulation, other).

HOSPITAL NAME

Animal EH

REFERRING VET

Dr. Ruby

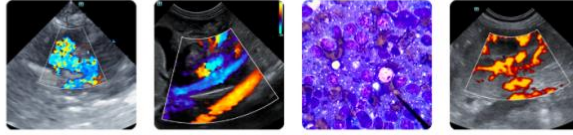
- Trace ascites

INVOICE

22538

Secondary Findings

- Mild bilateral nonspecific age-related renal changes



DATE

2-9-26

PATIENT

Grimm Hodge

SPECIES

Canine

BREED

Rottweiler

SEX

Female Spayed

AGE

88.7 lbs

WEIGHT

8/1/2017

INTERPRETED BY

Andrea Nicastro,
DVM, Diplomate
ACVIM (Small Animal
Internal Medicine)

HOSPITAL NAME

Animal EH

REFERRING VET

Dr. Ruby

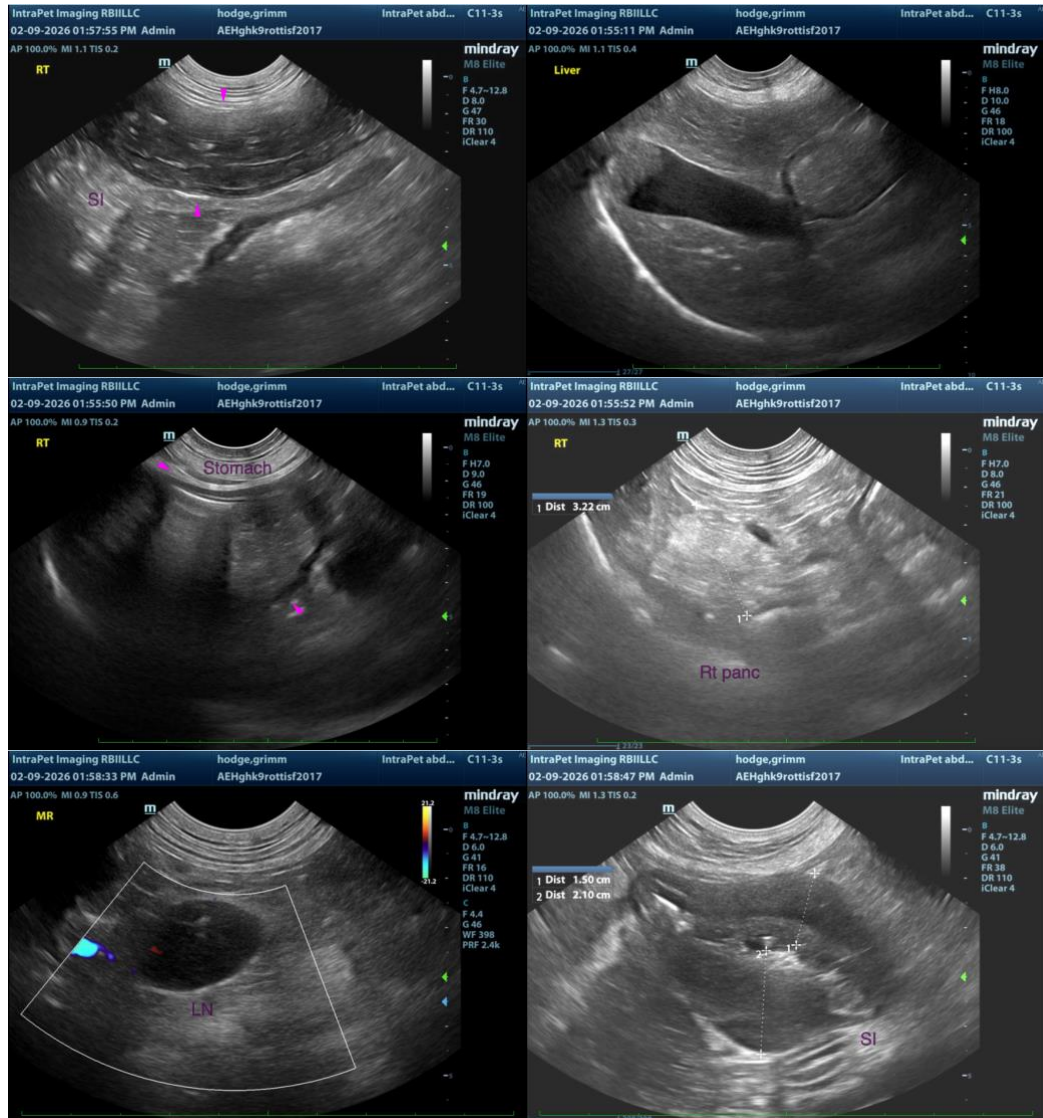
INVOICE

22538

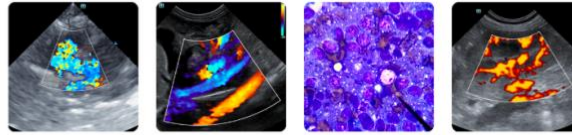
- The pancreatic changes are most consistent with age-related parenchymal remodeling, potentially secondary to a prior inflammatory episode, early fibrosis or chronic pancreatitis.

INTERPRETATION OF THE FINDINGS & FURTHER RECOMMENDATIONS

- Consider fine-needle aspiration of the enlarged mesenteric lymph nodes and thickened bowel segments (assuming normal clotting status). Twenty-five gauge-needles should be used. Depending on the results, consultation with a board-certified oncologist may be indicated.
- Other considerations include the following:
 - Three-view thoracic radiographs to assess cardiopulmonary status
 - GI panel including serum cobalamin and folate, TLI and PLI



Imaging performed by



Clinical Sonography & Telectylogy
Educational Teleconsultation Services™

SonoPath

FOSTERING THE ART OF VETERINARY MEDICINE™

SonoPath.com info@sonopath.com 1.800.838.4268

DATE

2-9-26

PATIENT

Grimm Hodge

SPECIES

Canine

BREED

Rottweiler

SEX

Female Spayed

AGE

88.7 lbs

WEIGHT

8/1/2017

INTERPRETED BY

Andrea Nicastro, DVM, Diplomate ACVIM (Small Animal Internal Medicine)

HOSPITAL NAME

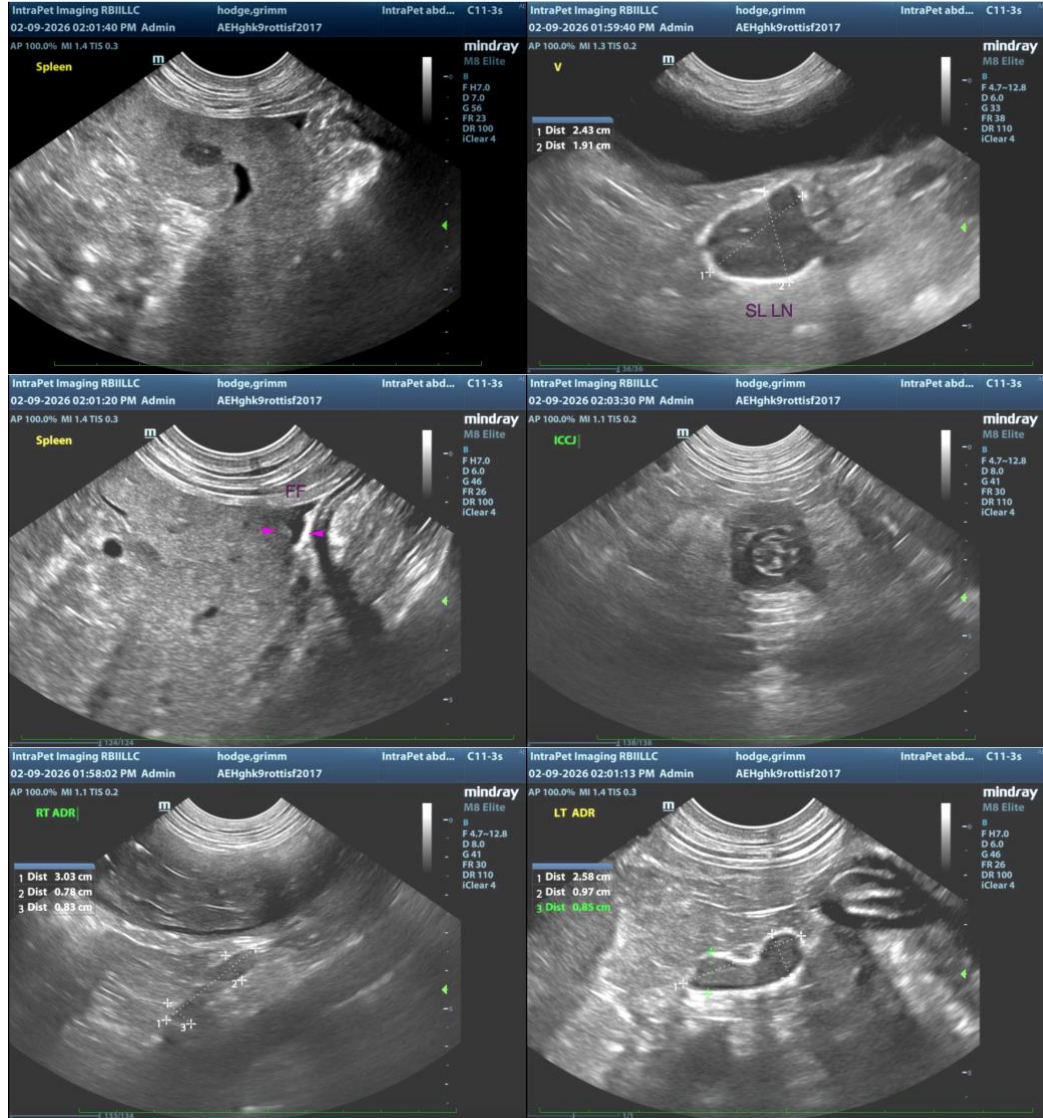
Animal EH

REFERRING VET

Dr. Ruby

INVOICE

22538



The information and recommendations provided are based on the images presented by the referring veterinarian/sonographer. No evaluation can be communicated regarding pathology that was not visible in the image/video clips provided.

Thank you for this referral. If the clinical or image interpretation does not parallel your findings or if I can be of any further assistance, please contact me.

Andrea Nicastro, MPH, DVM, Diplomate DACVIM (Small Animal Internal Medicine)
info@SonoPath.com