**DATE PRESENTING CLINICAL SIGNS**

2/9/2022

Referral for Continued Care. Pancreatitis.
 History: 02-08-2022 Notes: Ritchie is a 15 y/o MN Dachshund who was referred for azotemia - in West VA at cabin, O noticed increased drinking and did not think much of it as it is dryer there - was eating okay, Sunday was more tired - Monday did not eat, then ate some scrambled eggs and baby food - No C/S/V/D - urinating more frequently - Hx med: known heart murmur (never seen cardiologist), dental disease, hypothyroidism Medications: - Thyroxine 0.2 mg PO SID (suppose to be BID).

PATIENT

Ritchie Baczynskyj

SPECIES

Canine

Current Medications: Amp/Sulb (Unasyn) 1.5gm Injection, Buprenorphine 0.6mg/mL, Thyro Tablets (Levothyroxine) 0.2mg, Ondansetron 2mg/mL Injection, Pimobendan 5 mg, and Pantoprazole (Protonix) 40mg/vial Injection.

BREED

Lab Results: Attached.

Dachshund

SEX

Neutered Male

Radiographs: Abdomen 2 View: Enlarged cardiac silhouette, nephrolith in left kidney, GI tract uniform in appearance, enlarged liver vs folded spleen in lateral image

Date of Previous IntraPet Ultrasound: No previous.

AGE

2006

Sedation: Not required to complete full diagnostic ultrasound.
 Stat Report: Not requested.
 Imaging Performed By: Rachel Brillhart, RDMS.

WEIGHT

15.1 lbs

Additional history: Creatinine 3.2. B1 185. PCB 41. Normal blood pressure. Non-specific gravity 1.012.
 Trace proteinuria inactive sediment.

ULTRASONOGRAPHIC EXAMINATION OF THE ABDOMEN**INTERPRETED BY**

Andrea Nicastro, DMV,
 Diplomate DACVIM
 (Small Animal
 Internal Medicine)

Urinary System

The urinary bladder, trigone, and pelvic urethra are normal in thickness and the mucosal surface is smooth. The bladder lumen is moderately distended with anechoic urine. No masses, inflammatory changes or calculi are observed. Ureteral papillae and visualized portion of the proximal urethra, visible to a depth of 2 cm, are normal.

HOSPITAL NAME

Animal Emergency
 Hospital

The prostate is normal in size (0.92 cm in width) and shape. Parenchyma is homogenous. The prostatic urethra appears normal without evidence of dilation or obstruction.

REFERRING VET

Dr. Thompson

The left kidney is normal size (4.90 cm in length); normal shape and architecture with smooth peripheral margins. The cortex is mildly thickened and there is mild to moderate loss of corticomedullary distinction. A few small cortical cysts are present. Moderate pyelectasia is present (0.43 cm in the longitudinal plane). There is no evidence of nephroliths, infarcts or hydroureter. Renal vasculature is normal.

INVOICE

10298

The right kidney is normal size (4.69 cm in length); normal shape and architecture with smooth peripheral margins. The cortex is mildly thickened and there is mild to moderate loss of corticomedullary distinction. A few pinpoint foci of mineralization are observed within the cortex. A few small cortical cysts are present. Mild pyelectasia is present (0.30 cm in the longitudinal plane). There is no evidence of nephroliths, infarcts or hydroureter. Renal vasculature is normal.

Adrenal Glands

The left adrenal gland is enlarged (0.95 cm at cranial pole) (0.84 cm at caudal pole) (2.40 cm in length); with a slightly irregular shape; homogenous parenchyma. The glandular echogenicity and detail are unremarkable. Capsule, cortex, and medullary definition are normal. The phrenicoabdominal vein and surrounding vasculature are normal.

The right adrenal gland is enlarged (0.96 cm at cranial pole) (0.78 cm at caudal pole) (2.54 cm in length); with a slightly irregular shape; homogenous parenchyma. The glandular echogenicity and detail are unremarkable. Capsule, cortex, and medullary definition are normal. The phrenicoabdominal vein and surrounding vasculature are normal.

Spleen

The spleen is subjectively normal in size (0.86 cm in width at the level of the hilus) with normal curvilinear peripheral contours. A light micronodular pattern is present throughout the parenchyma. One to two small hypoechoic nodules are also seen. Splenic vasculature is normal with no evidence of thrombosis.

Liver

The liver is subjectively normal in size with normal curvilinear peripheral contours. The parenchyma is slightly mottled in appearance. No distinct focal lesions are observed. Vascular and biliary tracts are of normal volume with no evidence of congestion.

The gall bladder lumen is moderately distended. The wall is thin and smooth. A small amount of aggregated echogenic debris is adhered to the luminal surface. The cystic and common bile ducts are normal.

Gastrointestinal

The gastric wall is to mildly thickened (up to 0.61 cm), with a prominent muscularis layer in some areas. The gastric lumen is minimally distended with fluid. The pyloric outflow tract is patent. The small intestinal lumen is not dilated. One segment of small intestine in the caudal abdomen is slightly corrugated in appearance. The remaining small intestinal wall thickness is normal with a normal layering pattern and appropriate mural detail. Discreet masses are not identified. The colonic wall is normal. There is no evidence of an obstructive pattern.

Pancreas

The right limb is enlarged with irregular peripheral contours. The parenchyma is hyperechoic relative to surrounding omental fat and diffusely mottled in appearance with a few ill-defined hypoechoic nodules. The pancreatic duct is not overtly dilated.

Free Abdomen

The peritoneal cavity is normal. There is no evidence of inflammation or effusion. The abdominal lymph nodes are normal/not visible.

Other

A brief echocardiogram reveals no evidence of pericardial effusion or obvious right atrial/auricular mass.

ULTRASONOGRAPHIC FINDINGS

Primary Findings

- Bilateral non-specific nephropathy with pyelectasia, cortical cysts and left dystrophic mineralization. Based on the clinical history and sonographic changes acute-on-chronic renal

failure is suspected. Pyelonephritis is a possibility as well as toxin exposure, Leptospirosis, or progressive non-specific renal disease.

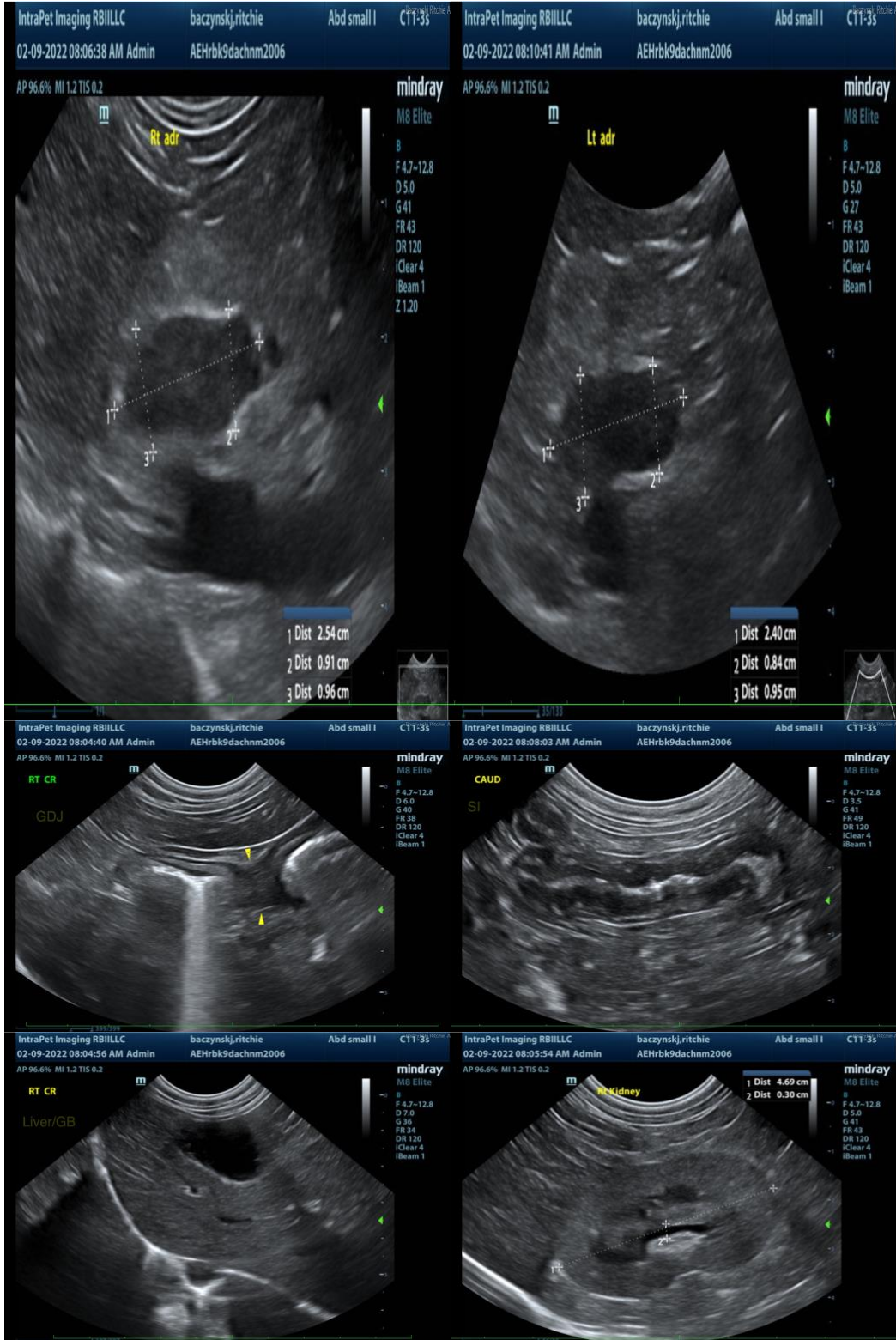
- The gastric wall thickening is most consistent with gastritis. Uremic gastritis is a consideration, given the presence of azotemia. Other possibilities include hypertrophy, or less likely, emerging neoplasia.

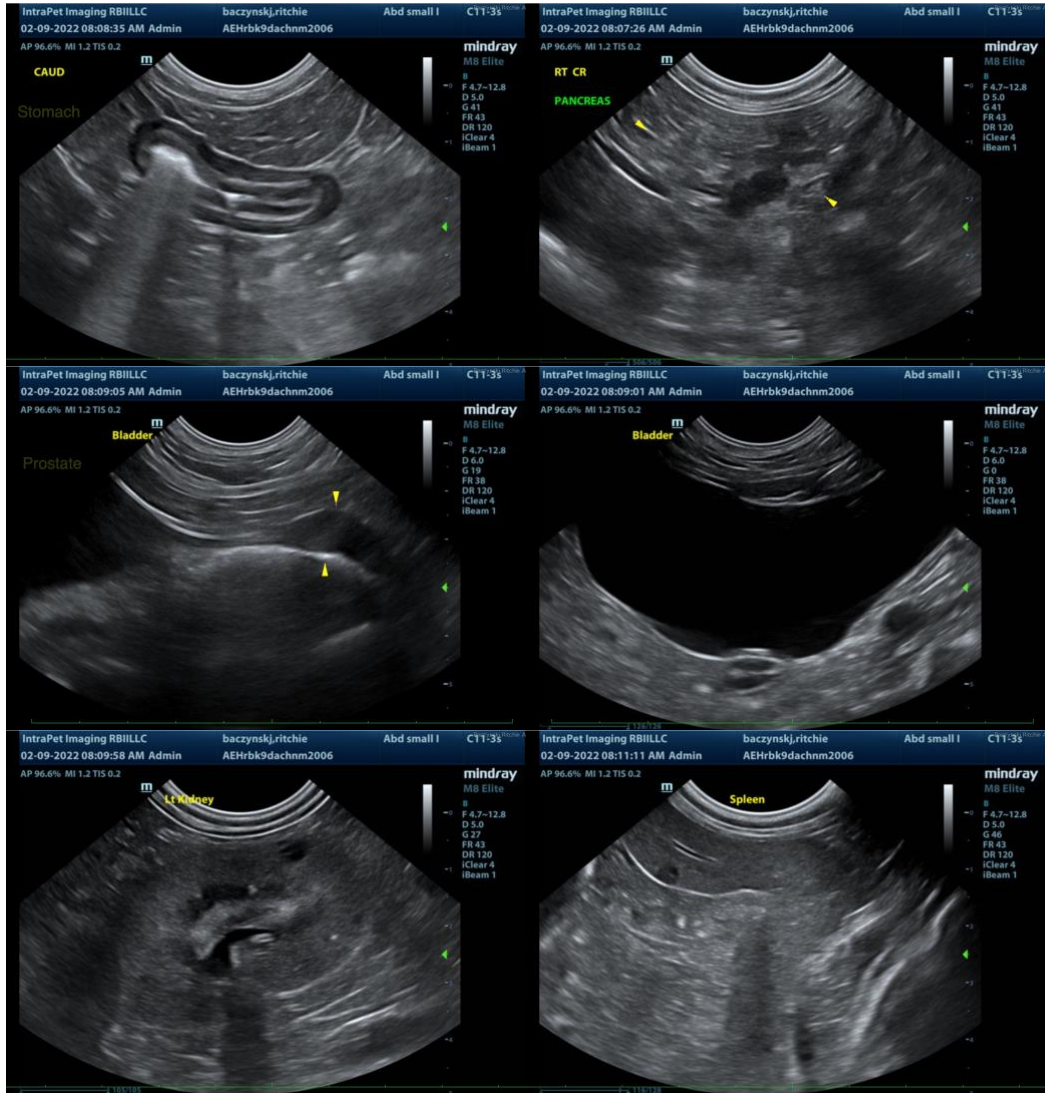
Secondary Findings

- Bilateral adernomegaly
- The splenic parenchyma changes are most consistent with a benign process such as lymphoid hyperplasia, extramedullary hematopoiesis or splenitis with a low possibility of infiltrative neoplasia (i.e., lymphoma, mast cell neoplasia).
- The diffuse hepatic changes are non-specific and could be consistent with vacuolar hepatopathy, regenerative nodular hyperplasia, and/or age-related remodeling. Inflammatory and infiltrative disease are considered less likely.
- The pancreatic changes are most consistent with age-related remodeling/fibrosis. Concurrent low-grade pancreatitis is also possible, particularly if a positive Murphy's sign is present.

INTERPRETATION OF THE FINDINGS & FURTHER RECOMMENDATIONS

- Leptospirosis testing (i.e., blood and urine PCR; serology)
- Urine culture and sensitivity, preferably on a pre-antibiotic sample
- UPC, IV fluid diuresis and supportive care. Broad-spectrum antibiotic therapy (i.e., fluoroquinolone), is also recommended while awaiting urine culture and sensitivity results





The information and recommendations provided are based on the images presented by the referring veterinarian/sonographer. No evaluation can be communicated regarding pathology that was not visible in the image/video clips provided.

Thank you for this referral. If the clinical or image interpretation does not parallel your findings or if I can be of any further assistance, please contact me.

Andrea Nicastro, DVM, Diplomate DACVIM (Small Animal Internal Medicine)
info@SonoPath.com