

**DATE PRESENTING CLINICAL SIGNS**

2.8.23 P presents adr with distended abdomen after falling off the couch last night. p now will not eat. No vomiting. normal BMs

PATIENT

Zoey Frommeyer

Current Medications: Galliprant 15mg SID.

Lab Results: Mild non-regenerative anemia. ALT 1050. ALP 3325. GGT 29. SDMA 18. BUN 54. USG 1.020. 3+ proteinuria. 4dx negative.

Radiographs: enlarged liver w/mineralization

SPECIES

Canine

Date of Previous IntraPet Ultrasound: No previous.

Sedation: Not required to complete full diagnostic ultrasound.

Stat Report: Declined.

Imaging Performed By: Stephanie Warga RDCS, RVT.

BREED

Yorkshire Terrier Mix

ULTRASONOGRAPHIC EXAMINATION OF THE ABDOMEN**SEX**

Spayed Female

Urinary System

The urinary bladder wall is normal in thickness and the mucosal surface is smooth. The bladder lumen is moderately distended with mostly anechoic urine. No masses, inflammatory changes or calculi are observed. Ureteral papillae and visualized portion of the proximal urethra, visible to a depth of 2 cm, are normal.

AGE

1/22/2012

The left kidney is normal in size (4.37 cm in length) with a normal shape, architecture and smooth peripheral margins. There is a normal 1:3 cortex to medulla ratio with poor corticomedullary distinction. The cortex is hyperechoic relative to the spleen. Pinpoint hyperechoic foci are observed within the cortex. Mild pyelectasia is present (0.25 cm in the transverse plane). There is no evidence of infarcts or hydroureter. Renal vasculature is normal.

WEIGHT

17.7 lbs

The right kidney is normal in size (4.12 cm in length) with a normal shape, architecture and smooth peripheral margins. There is a normal 1:3 cortex to medulla ratio with poor corticomedullary distinction. The cortex is hyperechoic relative to the spleen. One to two small cortical cysts are seen. Mild pyelectasia is present (0.29 cm in the transverse plane). There is no evidence of nephroliths, infarcts or hydroureter. Renal vasculature is normal.

INTERPRETED BY

Andrea Nicastro, DMV,
Diplomate DACVIM
(Small Animal
Internal Medicine)

HOSPITAL NAME

Northwind AH

Adrenal Glands

The left adrenal gland is mildly enlarged (0.90 cm at cranial pole) (0.47 cm at caudal pole) (2.27 cm in length) with a slightly irregular shape and homogenous parenchyma. The glandular echogenicity and detail are unremarkable. Capsule, cortex, and medullary definition are normal. The phrenicoabdominal vein and surrounding vasculature are normal.

REFERRING VET

Dr. Cross

The right adrenal gland is enlarged (0.81 cm at cranial pole) (0.77 cm at caudal pole) (2.11 cm in length) with a slightly irregular shape. The parenchyma is subtly heterogenous with some loss of glandular detail. A 0.58 cm ill-defined hyperechoic nodule/area is observed at the caudal aspect. The phrenicoabdominal vein and surrounding vasculature appear normal.

INVOICE

12172

Spleen

The spleen is normal in size (0.88 cm in width at the level of the hilus) with a normal capsular contour. There is appropriate echogenicity and echotexture. Numerous small linear mineralized foci are observed throughout the organ. Splenic vasculature is normal.

Liver

The liver is subjectively enlarged with swollen/rounded peripheral contours. The parenchyma is hyperechoic relative to the spleen and diffusely heterogenous, with numerous varying-sized hyperechoic

nodules throughout the organ. Hepatic vasculature and intrahepatic biliary tracts are of normal volume with no evidence of congestion. (See also "Other" category).

The gall bladder lumen is moderately distended. The wall is thin and smooth. A small to moderate amount of aggregated, echogenic, partially dependent debris/sludge is observed within the lumen. The cystic and common bile ducts are normal/not seen.

Gastrointestinal

The gastric lumen is mildly-distended liquid-appearing ingesta. The gastric wall appears to be normal in thickness with a normal layering pattern. The small intestinal lumen is not dilated. The small intestinal wall thickness is normal with a normal layering pattern and appropriate mural detail. Discreet masses are not identified. The wall of the descending colon is borderline thickened (up to 0.29 cm) with retention of the normal layering pattern. There is no evidence of an obstructive pattern. (See also "Other" category).

Pancreas

A portion of the pancreas is obscured by the cranial abdominal pathology. In the visualized portion no obvious pathology is observed.

Free Abdomen

There is no obvious evidence free fluid.

Lymph nodes

(See "Other" category).

Other

An approximately 8.00 cm hyperechoic to slightly heterogenous, mildly cavitated mass is observed in the mid- to right cranial abdomen. In addition, an approximately 3.40 cm irregular, mineralized focus is also observed in the mid-cranial abdomen.

ULTRASONOGRAPHIC FINDINGS

Primary Findings

- Large cranial abdominal mass (the origin of which is unclear). It may be arising from liver, GI tract, lymph node, mesentery, pancreas, other. Neoplasia (i.e., sarcoma, carcinoma, round cell tumor) is suspected. However, a benign process (i.e., nodular hyperplasia, inflammatory focus) cannot be completely excluded.
- The origin of the mineralized focus in the cranial abdomen is also unclear. It may be within the gastric lumen, associated with the cranial abdominal mass, other.
- The diffuse hepatic parenchymal changes are nonspecific and may be secondary to infiltrative neoplasia, multifocal inflammatory disease, hepatotoxicosis (i.e., copper), regenerative nodular hyperplasia, vacuolar hepatopathy, other hepatopathy, or some combination thereof.

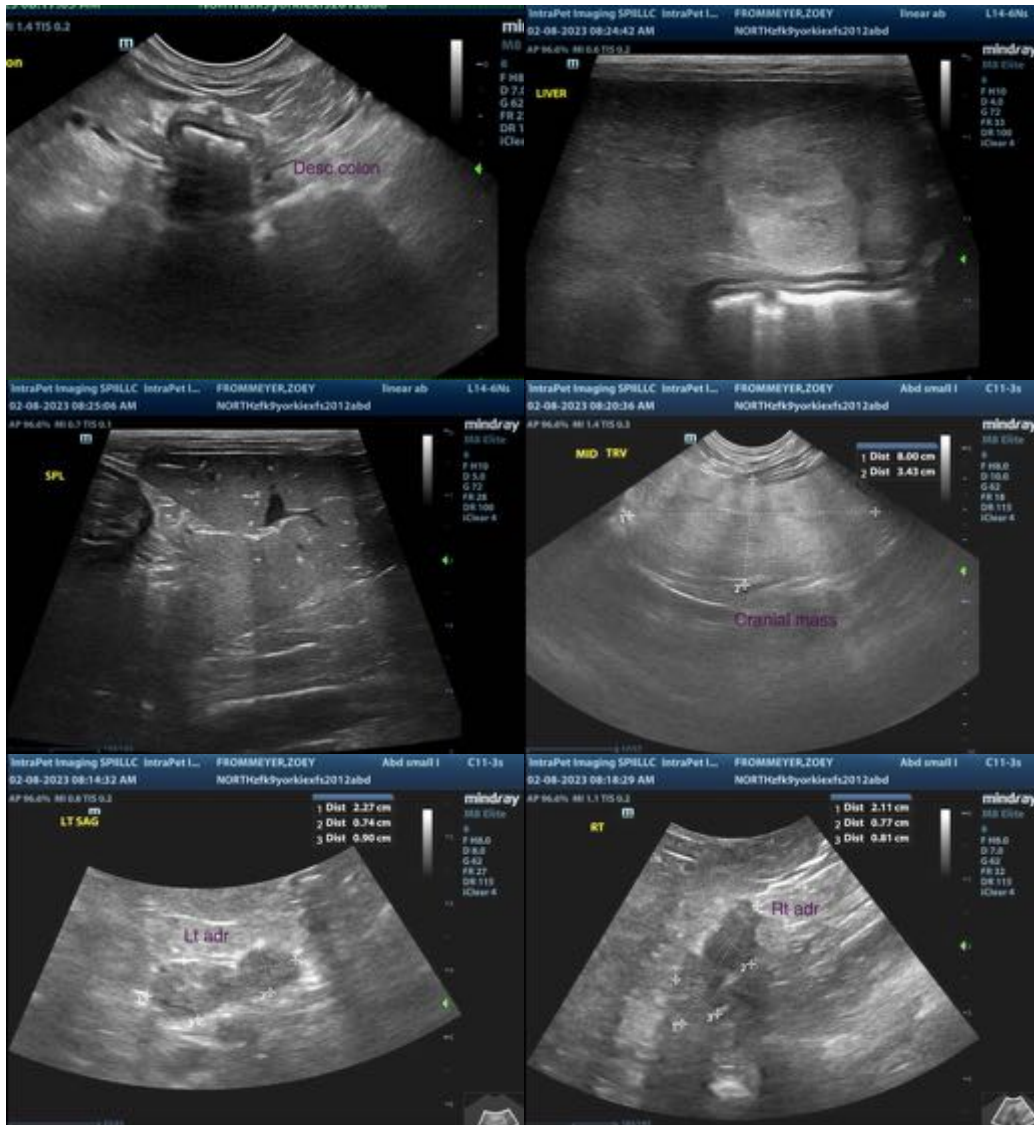
Secondary Findings

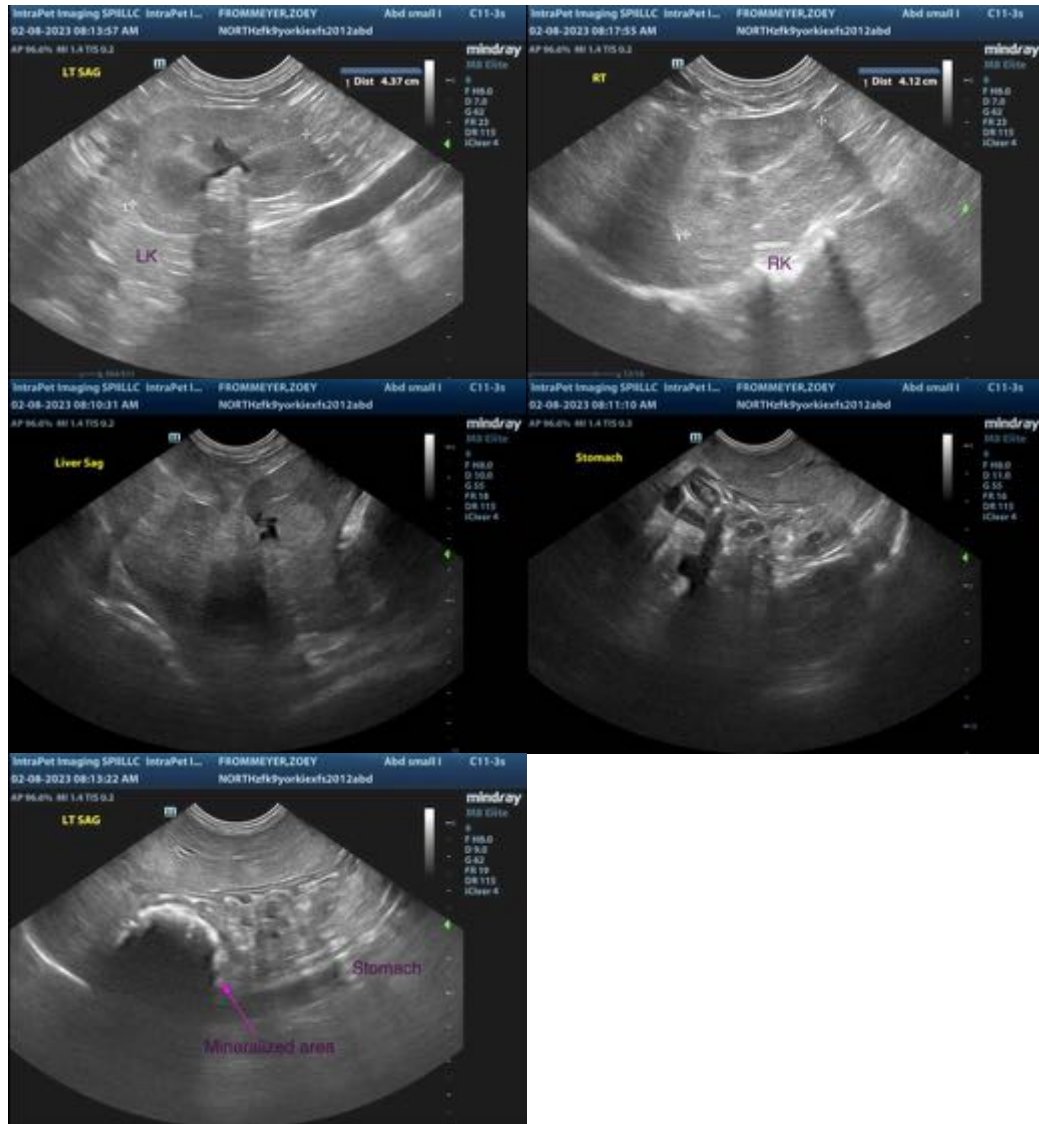
- Bilateral chronic degenerative renal changes with pyelectasia
- The splenic parenchymal changes are most consistent with dystrophic mineralization. This tends to be a benign incidental finding, associated with endocrinopathies.
- Mild bilateral adrenomegaly

- Gall bladder/sludge – non-mucocele
- The mild colonic wall thickening is most consistent with an inflammatory process, with a lower possibility of emerging neoplasia.

INTERPRETATION OF THE FINDINGS & FURTHER RECOMMENDATIONS

- Three-view thoracic radiographs are recommended to assess for pulmonary metastases.
- Consider fine-needle aspirates of the cranial abdominal mass and liver (if clotting status is appropriate). 25-gauge needles should be used. If the cytology results are inconclusive, surgical biopsies may be necessary to get a definitive diagnosis. An abdominal CT scan would be useful in better characterizing the origin and extent of the cranial abdominal mass and mineralized area.





The information and recommendations provided are based on the images presented by the referring veterinarian/sonographer. No evaluation can be communicated regarding pathology that was not visible in the image/video clips provided.

Thank you for this referral. If the clinical or image interpretation does not parallel your findings or if I can be of any further assistance, please contact me.

Andrea Nicastro, MPH, DVM, Diplomate DACVIM (Small Animal Internal Medicine)
info@SonoPath.com

