


PATIENT PRESENTING CLINICAL SIGNS

Rupert Pataky History: Pre dental blood work indicated elevated liver values Scan to evaluate liver

SPECIES

Canine

Abnormal PE/Chem/CBC/UA Results: CBC WNL, except: - MPV 13.5 (N 8.7 - 13.2) HIGH Chemistry WNL, except: - Alkp 437 (N 23 - 212) HIGH - Amyl 472 (N 500 - 1500) LOW - TT4 24 (N 13 - 51) - SDMA 12 (N 0 - 14) Repeated a month later: alp elevated 583 (23-212) was 437) lipase elevated 1848 (200-1800) (amylase had previously

BREED

Schipperke

SEX

Neutered Male

AGE

7 years

WEIGHT

8.60 kg

ULTRASONOGRAPHIC EXAMINATION OF THE ABDOMEN
Urinary System

The urinary bladder wall is normal in thickness and the mucosal surface is smooth. The bladder lumen is mildly to moderately distended with anechoic urine. No masses, inflammatory changes or calculi are observed. Ureteral papillae and visualized portion of the proximal urethra, visible to a depth of 2 cm, are normal.

The prostate is normal in size (0.85 cm in width) and shape. Parenchyma is homogenous. The prostatic urethra appears normal without evidence of dilation or obstruction.

The left kidney is normal in size (4.67 cm in length) with a normal shape, architecture and smooth peripheral margins. There is a normal 1:3 cortex to medulla ratio with minimal to mild loss of corticomedullary distinction. There is no evidence of pyelectasia, nephroliths, infarcts or hydroureter. Renal vasculature is normal.

The right kidney is normal in size (4.74 cm in length) with a normal shape, architecture and smooth peripheral margins. There is a normal 1:3 cortex to medulla ratio with minimal to mild loss of corticomedullary distinction. There is no evidence of pyelectasia, nephroliths, infarcts or hydroureter. Renal vasculature is normal.

INTERPRETED BY

Andrea Nicastro, DVM,
 Diplomate ACVIM (*Small
 Animal Internal Medicine*)

Adrenal Glands

The left adrenal gland is normal in size (0.30 cm at cranial pole) (0.50 cm at caudal pole) (0.61 cm in length) with a normal shape and homogenous parenchyma. The glandular echogenicity and detail are unremarkable. Capsule, cortex, and medullary definition are normal. The phrenicoabdominal vein and surrounding vasculature are normal.

IMAGING PERFORMED BY

Dr Brian J Barnes

The right adrenal gland is in normal size (0.49 cm at cranial pole) (0.51 cm at caudal pole) (1.48 cm in length) with a normal shape and homogenous parenchyma. The glandular echogenicity and detail are unremarkable. Capsule, cortex, and medullary definition are normal. The phrenicoabdominal vein and surrounding vasculature are normal.

HOSPITAL NAME

Westview VH

Spleen

The spleen is normal in size (1.22 cm in width at the level of the hilus) with a normal capsular contour. The parenchyma is subtly mottled in appearance. No focal lesions are observed. Splenic vasculature is normal.

REFERRING VET

Dr Brian J Barnes

Liver

The liver is subjectively prominent to enlarged with slightly swollen peripheral contours. The parenchyma is isoechoic to mildly hypoechoic relative to the spleen, with relatively homogenous parenchyma and a coarse echotexture. No distinct focal lesions are observed. Hepatic vasculature and intrahepatic biliary tracts are of normal volume with no evidence of congestion. The portal vein to caudal vena cava ratio is approximately 1: 1.

INVOICE

12174

DATE

2.8.23

The gall bladder lumen is moderately distended. The wall is thin and smooth. A scant amount of echogenic debris is observed within the lumen. The cystic and common bile ducts are normal/not seen.

Gastrointestinal

The stomach and intestine are free of stasis and exhibit normal peristaltic activity. The gastric lumen is not distended. The gastric wall and pylorus are normal in thickness with a normal layering pattern. The pyloric outflow tract is patent. The small intestinal lumen is not dilated. The small intestinal wall thickness is normal with a normal layering pattern and appropriate mural detail. Discreet masses are not identified. The colonic wall is normal. There is no evidence of an obstructive pattern.

Pancreas

The region of the pancreas is isoechoic relative to surrounding omental fat. No obvious parenchymal abnormalities are observed. There is no evidence of regional inflammation or effusion.

Free Abdomen

The peritoneal cavity is normal. There is no evidence of inflammation or effusion. A 1.14 cm mesenteric lymph node is visualized.

ULTRASONOGRAPHIC FINDINGS

Primary Findings

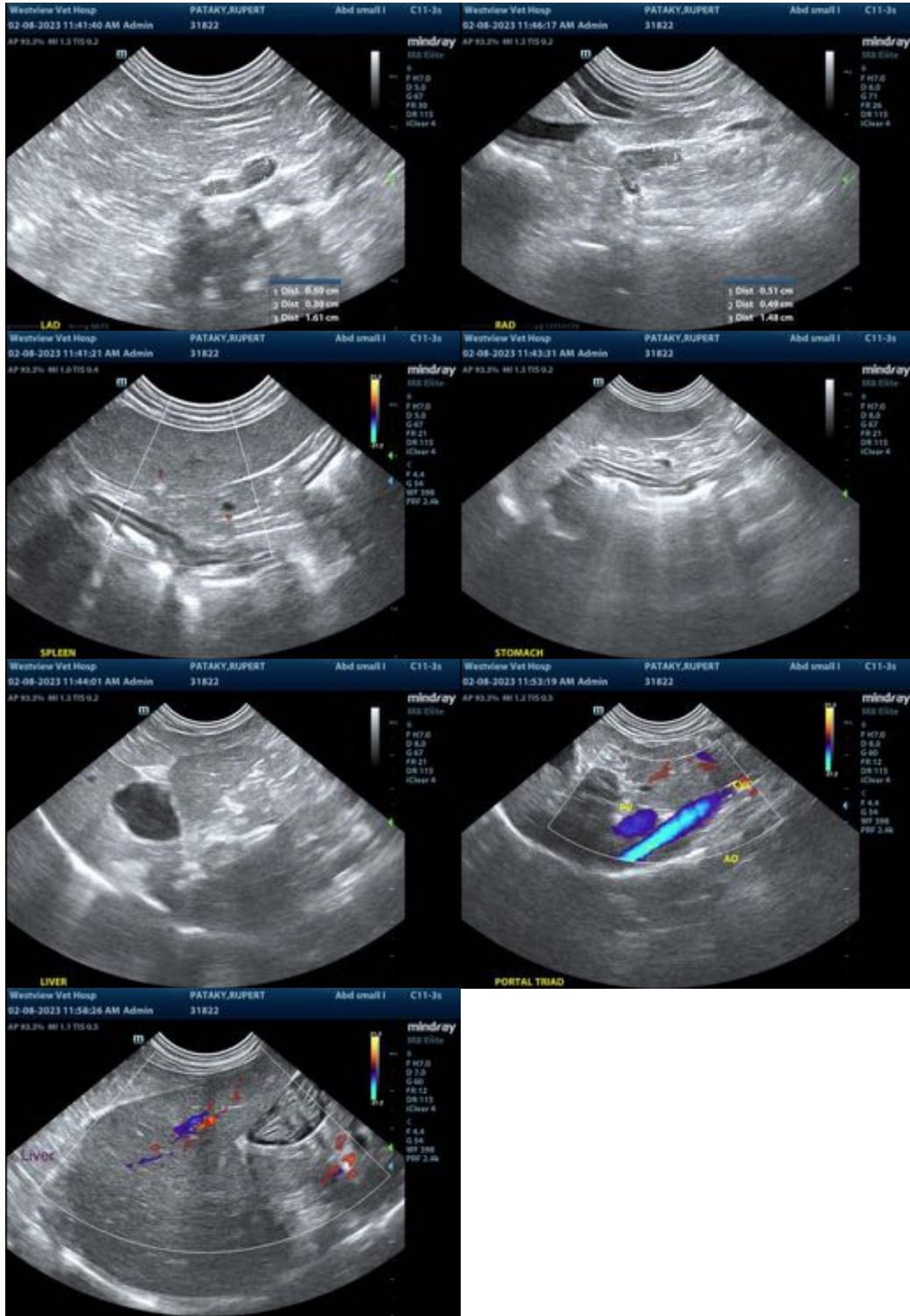
- Nonspecific diffuse hepatopathy. Differentials include vacuolar hepatopathy (i.e., idiopathic, endocrine), hepatotoxicosis (i.e., copper), inflammatory disease (less likely in light of the normal ALT), other hepatopathy.

Secondary Findings

- Minor bilateral age-related renal changes
- The splenic parenchymal changes are most consistent with a benign process such as lymphoid hyperplasia, extramedullary hematopoiesis, splenitis or antigenic stimulation with a low possibility of infiltrative neoplasia (i.e., lymphoma, mast cell neoplasia).

INTERPRETATION OF THE FINDINGS & FURTHER RECOMMENDATIONS

Consider hepatic tissue sampling (i.e., fine-needle aspirate or biopsy (laparoscopic or surgical)) if clotting status is appropriate. If biopsies are pursued, aerobic and anaerobic bile cultures should also be obtained along with additional hepatic tissue sampling for potential copper quantitation. If hepatic tissue sampling is not pursued at this time, liver values should be rechecked in 2-3 months to assess for further increases. Leptospirosis testing can also be considered. However, this differential is considered less likely, given the normal ALT and the asymptomatic state of the patient.



The information and recommendations provided are based on the images presented by the referring veterinarian/sonographer. No evaluation can be communicated regarding pathology that was not visible in the image/video clips provided.

Thank you for this referral. If the clinical or image interpretation does not parallel your findings or if I can be of any further assistance, please contact me.

Andrea Nicastro, MPH, DVM, Diplomate DACVIM (Small Animal Internal Medicine)
info@SonoPath.com