

**DATE**

2/8/2022

**PRESENTING CLINICAL SIGNS**

History: ER on 10/11/21 for pancreatitis. P had blood work and rads. P was on bland diet. P was on Carafate and Metro - O did not give Cerenia or Gaba. P has been acting normal since episode of pancreatitis. No vomiting or diarrhea. Started P on Denamarin with no improvement in ALT.

**PATIENT**

Whiskey Stasak

Current Medications: Denamarin Advanced CHEWABLE Tablets Small / Medium Canine (120mg) - starting 11.22.21 - no other medications

Lab Results: 10/11/21 - ALT 167. 11/22/21 - ALT 166. 2/4/22 - ALT 242

Date of Previous IntraPet Ultrasound: No previous IntraPet scans.

Sedation: Not required to complete full diagnostic ultrasound.

Stat Report: Not requested.

**SPECIES**

Canine

**BREED**

Doodle mix

Imaging Performed By: Andi Parkinson, RDMS.

**SEX**

Male, neutered

**ULTRASONOGRAPHIC EXAMINATION OF THE ABDOMEN****Urinary System**

The urinary bladder, trigone, and pelvic urethra are normal in thickness and the mucosal surface is smooth. The bladder lumen is moderately distended with mostly anechoic urine. No masses, inflammatory changes or calculi are observed. Ureteral papillae and visualized portion of the proximal urethra, visible to a depth of 2 cm, are normal.

**AGE**

7/21/2020

The prostate is normal in size (0.89 cm in width in the transverse plane) and shape. Parenchyma is homogenous. The prostatic urethra appears normal without evidence of dilation or obstruction.

**WEIGHT**

16.9 lbs.

The left kidney is normal size (4.92 cm in length); normal shape and architecture with smooth peripheral margins. There is a normal 1:3 cortex to medulla ratio with normal corticomedullary distinction. There is no evidence of pyelectasia, nephroliths, infarcts or hydroureter. Renal vasculature is normal.

**INTERPRETED BY**

Andrea Nicastro, DVM,  
Diplomate ACVIM  
(Small Animal Internal  
Medicine)

The right kidney is normal size (3.97 cm in length); normal shape and architecture with smooth peripheral margins. There is a normal 1:3 cortex to medulla ratio with normal corticomedullary distinction. There is no evidence of pyelectasia, nephroliths, infarcts or hydroureter. Renal vasculature is normal.

**HOSPITAL NAME**

Warm &amp; Fuzzy VC

**Adrenal Glands**

The left adrenal gland is normal size (0.40 cm at cranial pole) (0.45 cm at caudal pole) (1.86 cm in length); normal shape; homogenous parenchyma. The glandular echogenicity and detail are unremarkable. Capsule, cortex, and medullary definition are normal. The phrenicoabdominal vein and surrounding vasculature are normal.

**REFERRING VET**

Dr. Weber

The right adrenal gland is normal size (0.38 cm at cranial pole) (0.55 cm at caudal pole) (1.86 cm in length); normal shape; homogenous parenchyma. The glandular echogenicity and detail are unremarkable. Capsule, cortex, and medullary definition are normal. The phrenicoabdominal vein and surrounding vasculature are normal.

**INVOICE**

12985

**Spleen**

The spleen is normal in size (1.20 cm in width at the level of the hilus) with a normal capsular contour. There is appropriate echogenicity and echotexture. No focal lesions are observed. Splenic vasculature is normal.

**Liver**

The liver is subjectively normal in size with normal contours and structure. There is appropriate echogenicity and echotexture. No overt structural evidence of inflammatory, infiltrative or regenerative pathology is evident. Vascular and biliary tracts are of normal volume with no evidence of congestion. No pathological

hepatic lymphadenopathy observed. The gall bladder lumen is moderately distended. The wall is thin and smooth. Luminal contents are mostly anechoic. The cystic and common bile ducts are normal/not seen.

### ***Gastrointestinal***

The stomach and intestine are free of stasis and exhibit normal peristaltic activity. The gastric lumen is not distended. The gastric wall and pylorus are normal in thickness with a normal layering pattern. The pyloric outflow tract is patent. The small intestinal lumen is not dilated. The small intestinal wall thickness is normal with a normal layering pattern and appropriate mural detail. Discreet masses are not identified. The colonic wall is normal. No obstructive disease is noted.

### ***Pancreas***

The pancreas is normal in size with normal peripheral contours. The pancreatic duct is normal. The base and limbs of the pancreas are isoechoic to surrounding omental fat. No focal lesions are observed. There is no evidence of peripancreatic inflammation or effusion.

### ***Free Abdomen***

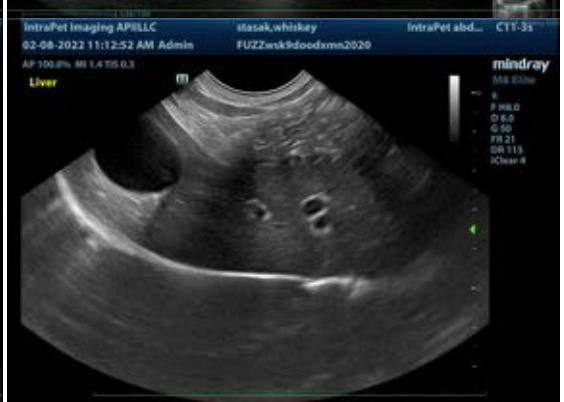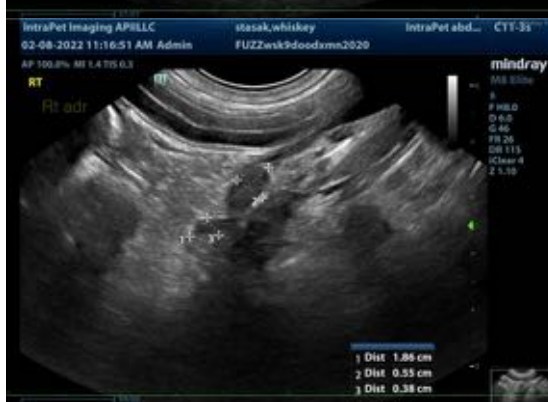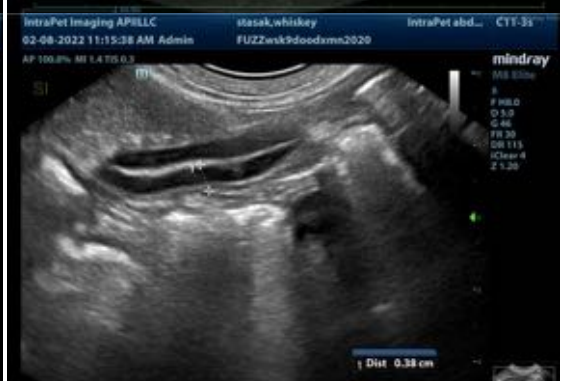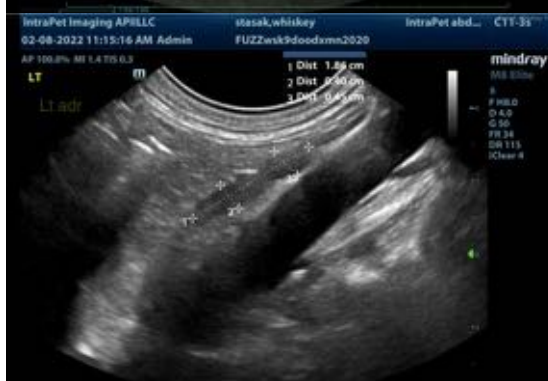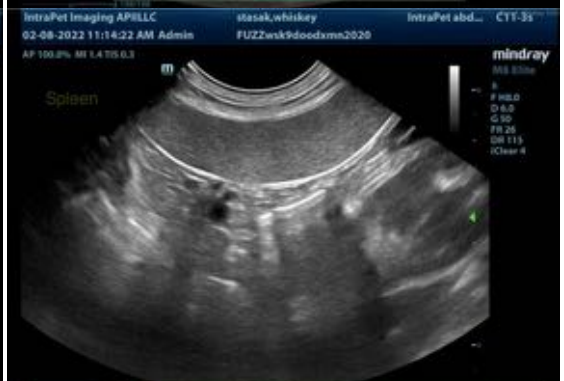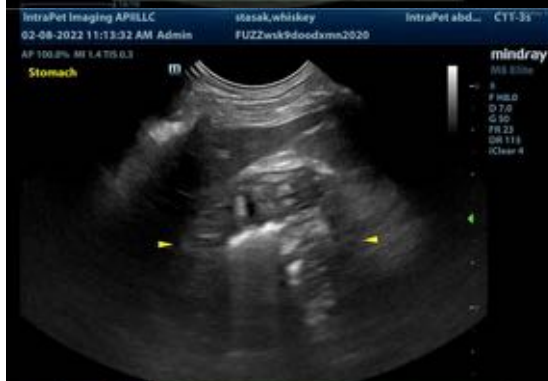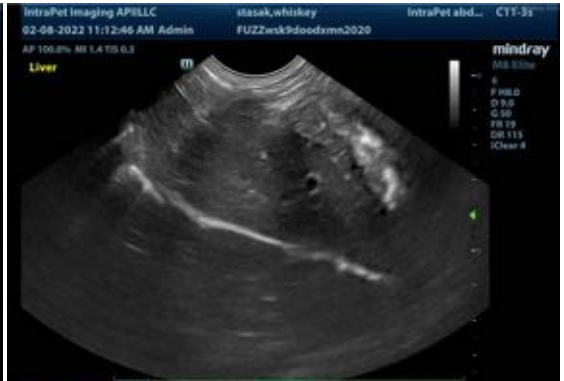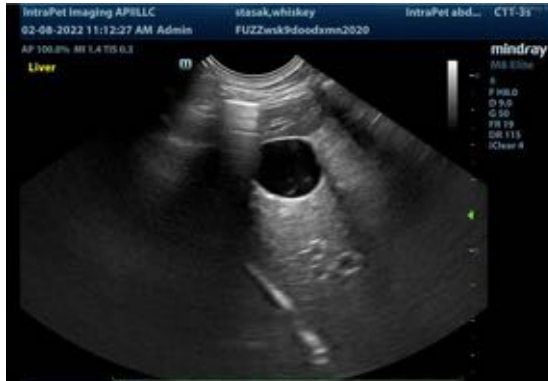The peritoneal cavity is normal. There is no evidence of inflammation or effusion. 2-3 prominent mesenteric lymph nodes are visualized, the largest measuring 1.20 cm in length.

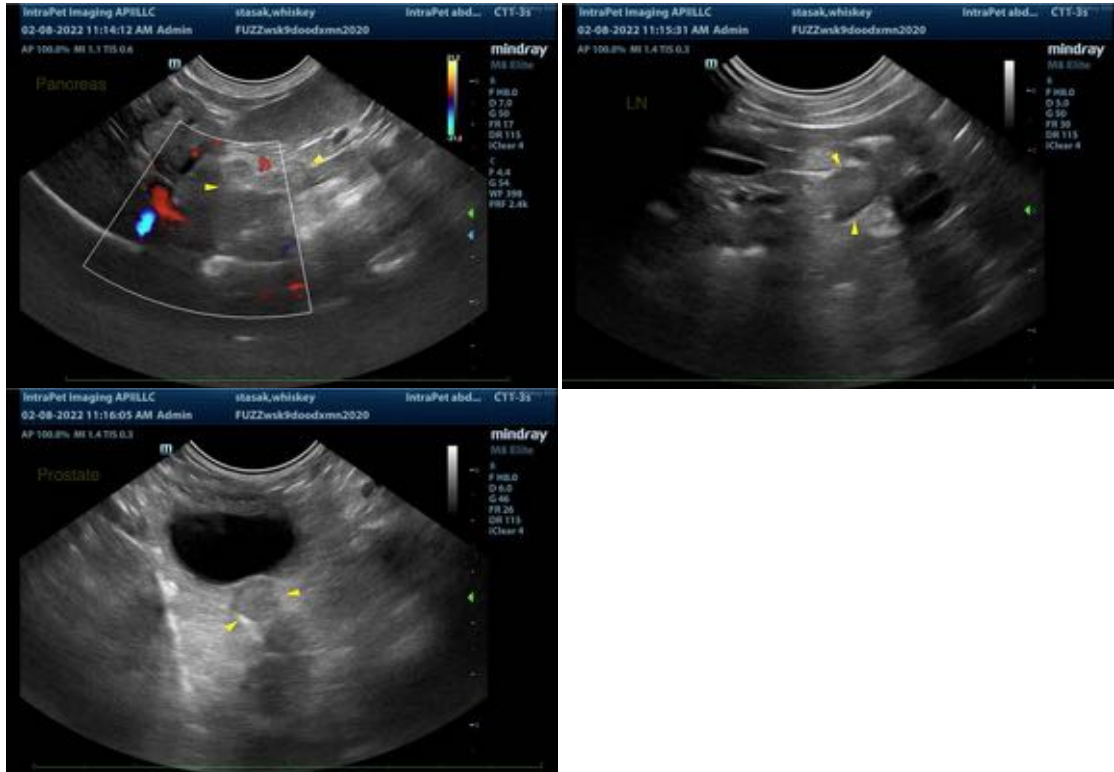
## **ULTRASONOGRAPHIC FINDINGS**

- The prominent mesenteric lymph nodes are likely reactive.
- An obvious cause for the elevated liver enzymes is not identified in the study. However, a microscopic hepatopathy (i.e., bacterial cholangiohepatitis, chronic active hepatitis, copper-associated hepatotoxicity, reactive hepatopathy, infiltrative neoplasia (less likely), Leptospirosis (less likely)) should be considered.

## **INTERPRETATION OF THE FINDINGS & FURTHER RECOMMENDATIONS**

- Consider pre- and post-prandial serum bile acids to assess hepatic function.
- A thorough oral exam is also recommended to assess for dental disease that may be causing a reactive hepatopathy.
- Ultimately, a surgical liver biopsy with aerobic and anaerobic bile cultures and acquisition of additional hepatic tissue samples for potential copper quantitation may be necessary to get a definitive diagnosis. A fine needle hepatic aspirate can be considered. However, results may not be representative of an underlying diffuse hepatopathy.
- If a more conservative approach is desired, empirical treatment for bacterial cholangiohepatitis (i.e., broad spectrum antibiotics along with continuation of the Denamarin) can be considered. If there is no improvement in the liver values within 5-7 days of initiating therapy, antibiotics should be discontinued and hepatic tissue sampling revisited.
- Leptospirosis testing can be considered. However, given the chronicity of the ALT elevation this differential is considered less likely.





The information and recommendations provided are based on the images presented by the referring veterinarian. No evaluation can be communicated regarding pathology that was not visible in the image/video clips provided.

Thank you for this referral. If the clinical or image interpretation does not parallel your findings or if I can be of any further assistance please contact me.

Andrea Nicastro, DVM, Diplomate ACVIM (*Small Animal Internal Medicine*)  
Andrea.nicastro@sonopath.com