



**PATIENT PRESENTING CLINICAL SIGNS**

Simba Torres Rivera

History: Presented as a referral for an abdominal ultrasound to evaluate vomiting. Pt has a history of vomiting and the most recent was 2-5-22. The patient was treated with Cerenia and famotidine and improved, but clinical signs returned a day later after offering a dental stick.

**SPECIES**

Abnormal PE/Chem/CBC/UA Results: BW: CHEM: ALT 168 (20-150) CBC: WBC 17.55 (6-17) NEU: 15.6 (3-12) HCT: 71 (37-55) PLT: 562 (165-500)

Canine

**BREED**

**ULTRASONOGRAPHIC EXAMINATION OF THE ABDOMEN**

Mixed breed

*Urinary System*

**SEX**

The urinary bladder, trigone, and pelvic urethra are normal in thickness and the mucosal surface is smooth. The bladder lumen is moderately distended with anechoic urine. No masses, inflammatory changes or calculi are observed. Ureteral papillae and visualized portion of the proximal urethra, visible to a depth of 2 cm, are normal.

Male, intact

**AGE**

The prostate is enlarged (2.64 cm in width) with a normal shape and relatively smooth peripheral contours. The parenchyma is hyperechoic to slightly heterogeneous in appearance with a few small ill-defined cystic areas. The prostatic urethra is not overtly dilated.

11 Yrs.

**WEIGHT**

The left kidney is normal size (5.27 cm in length); normal shape and architecture with smooth peripheral margins. There is a normal 1:3 cortex to medulla ratio with moderate loss of corticomedullary distinction. There is no evidence of pyelectasia, nephroliths, infarcts or hydronephrosis.

20 lbs.

**INTERPRETED BY**

The right kidney is normal size (5.09 cm in length); normal shape and architecture with smooth peripheral margins. There is a normal 1:3 cortex to medulla ratio with moderate loss of corticomedullary distinction. There is no evidence of pyelectasia, nephroliths, infarcts or hydronephrosis.

Andrea Nicastro, DVM,  
Diplomate ACVIM  
(Small Animal Internal  
Medicine)

*Adrenal Glands*

**IMAGING**

The left adrenal gland is normal size (0.52 cm at cranial pole) (0.58 cm at caudal pole) (1.62 cm in length); normal shape; homogenous parenchyma. The glandular echogenicity and detail are unremarkable. Capsule, cortex, and medullary definition are normal. The phrenicoabdominal vein and surrounding vasculature are normal.

**PERFORMED BY**

Dr. Ferrer

The right adrenal gland is normal size (0.94 cm at cranial pole) (0.48 cm at caudal pole) (1.83 cm in length); normal shape; homogenous parenchyma. The glandular echogenicity and detail are unremarkable. Capsule, cortex, and medullary definition are normal. The phrenicoabdominal vein and surrounding vasculature are normal.

**HOSPITAL NAME**

Paseos VC

*Spleen*

**REFERRING VET**

Dr. Biello

The spleen is normal in size (1.62 cm in width at the level of the hilus) with a normal capsular contour. There is appropriate echogenicity and echotexture. No focal lesions are observed. Splenic vasculature is normal.

**INVOICE**

*Liver*

12974

The liver is subjectively normal in size with normal contours and structure. There is appropriate echogenicity and echotexture. No overt structural evidence of inflammatory, infiltrative or regenerative pathology is evident. Vascular and biliary tracts are of normal volume with no evidence of congestion. No pathological hepatic lymphadenopathy observed. The gall bladder lumen is moderately

**DATE**

2/8/22



**PATIENT**

Simba Torres Rivera

distended. The wall is thin and smooth. A small to moderate amount of partially dependent echogenic debris/sludge is observed within the lumen. The cystic and common bile ducts are normal/not seen.

***Gastrointestinal***

**SPECIES**

Canine

The stomach and intestine are free of stasis and exhibit normal peristaltic activity. The gastric lumen is not distended. The gastric wall and pylorus are normal in thickness with a normal layering pattern. The pyloric outflow tract is patent. The small intestinal lumen is not dilated. The small intestinal wall thickness is normal with a normal layering pattern and appropriate mural detail. Discreet masses are not identified. The colonic wall is normal. No obstructive disease is noted.

**BREED**

Mixed breed

***Pancreas***

**SEX**

Male, intact

The region of the pancreas is isoechoic relative to surrounding omental fat. No obvious parenchymal abnormalities are observed. There is no evidence of regional inflammation or effusion.

***Free Abdomen***

**AGE**

11 Yrs.

The peritoneal cavity is normal. There is no evidence of inflammation or effusion. 1-2 prominent mesenteric lymph nodes are visualized, the largest measuring 0.82 cm in length.

**WEIGHT**

20 lbs.

**ULTRASONOGRAPHIC FINDINGS**

- The prostate changes are most consistent with benign prostatic hyperplasia. Bacterial prostatitis is also a differential but considered unlikely in the absence of lower urinary tract signs.
- Bilateral degenerative renal changes
- The lymph node changes are most consistent with reactive lymphadenitis or lymphoid hyperplasia.

**INTERPRETED BY**

Andrea Nicastro, DVM,  
Diplomate ACVIM  
(*Small Animal Internal  
Medicine*)

\*An obvious cause for the patient's vomiting is not identified in this study. Considerations include underlying metabolic disease, primary gastrointestinal disease (i.e., food allergy, inflammatory bowel disease, intestinal dysbiosis), low-grade pancreatitis, other.

**IMAGING PERFORMED BY**

Dr. Ferrer

**INTERPRETATION OF THE FINDINGS & FURTHER RECOMMENDATIONS**

**HOSPITAL NAME**

Paseos VC

- Given the elevated ALT, consider pre- and post-prandial serum bile acids to assess hepatic function.
- Given the severely elevated PCV, correction of dehydration (if present) is recommended followed by a recheck PCV. If the PCV is still elevated, further workup for polycythemia (i.e., thoracic radiographs, echocardiogram +/- arterial blood gas) should be considered.

**REFERRING VET**

Dr. Biello

- To further evaluate the vomiting issue, consider the following:
  1. Three-view thoracic radiographs to assess for occult esophageal disease.
  2. A fecal evaluation for ova/Giardia
  3. Malabsorption panel including serum cobalamin, folate, TLI and PLI

**INVOICE**

12974

**DATE**

2/8/22



**PATIENT**

Simba Torres Rivera

4. A resting cortisol level to screen for hypoadrenocorticism. If resting cortisol level is < 2.0 mcg/dL, an ACTH stimulation test is recommended

**SPECIES**

Canine

5. If the vomiting is chronic, consider a 6-week limited antigen diet trial.

6. Depending on the results of the above diagnostics, endoscopic or surgical GI biopsies may be necessary to get a definitive diagnosis.

**BREED**

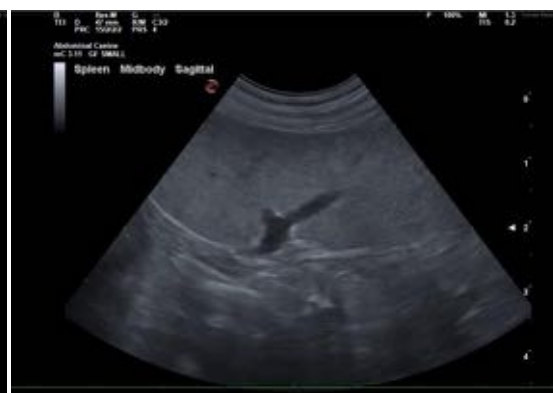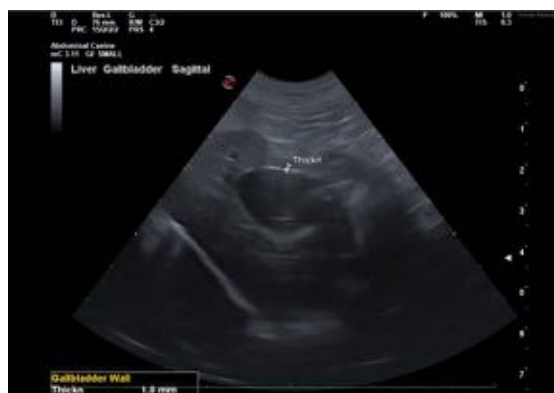Mixed breed

**SEX**

Male, intact

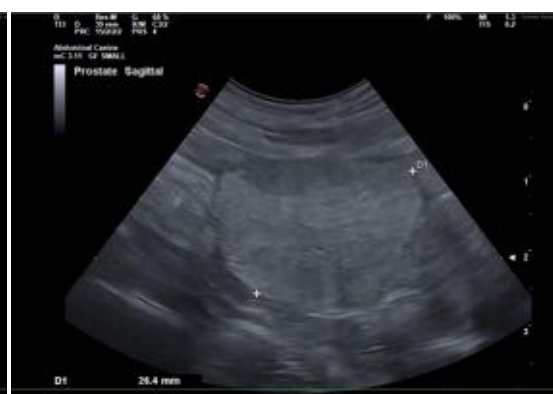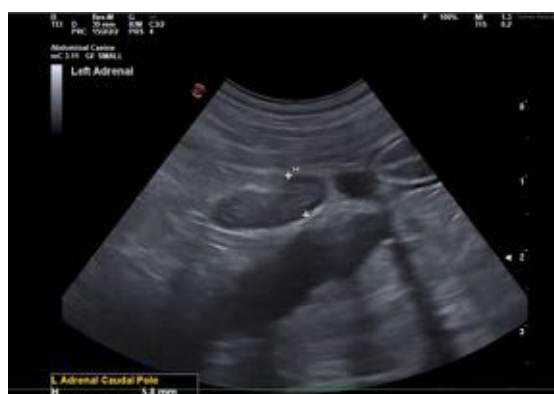**AGE**

11 Yrs.



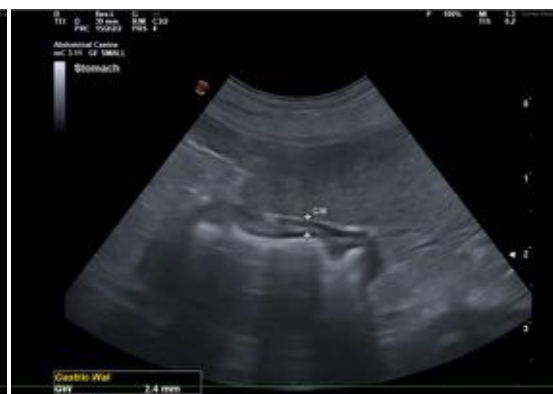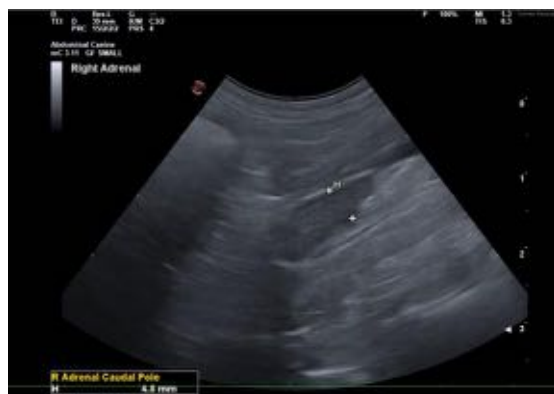**WEIGHT**

20 lbs.



**INTERPRETED BY**

Andrea Nicastro, DVM,  
Diplomate ACVIM  
(Small Animal Internal  
Medicine)



**IMAGING PERFORMED BY**

Dr. Ferrer

**HOSPITAL NAME**

Paseos VC

**REFERRING VET**

Dr. Biello

**INVOICE**

12974

**DATE**

2/8/22



**PATIENT**

Simba Torres Rivera

**SPECIES**

Canine

**BREED**

Mixed breed

**SEX**

Male, intact

**AGE**

11 Yrs.

**WEIGHT**

20 lbs.

**INTERPRETED BY**

Andrea Nicastro, DVM,  
Diplomate ACVIM  
(Small Animal Internal  
Medicine)

**IMAGING  
PERFORMED BY**

Dr. Ferrer

**HOSPITAL NAME**

Paseos VC

**REFERRING VET**

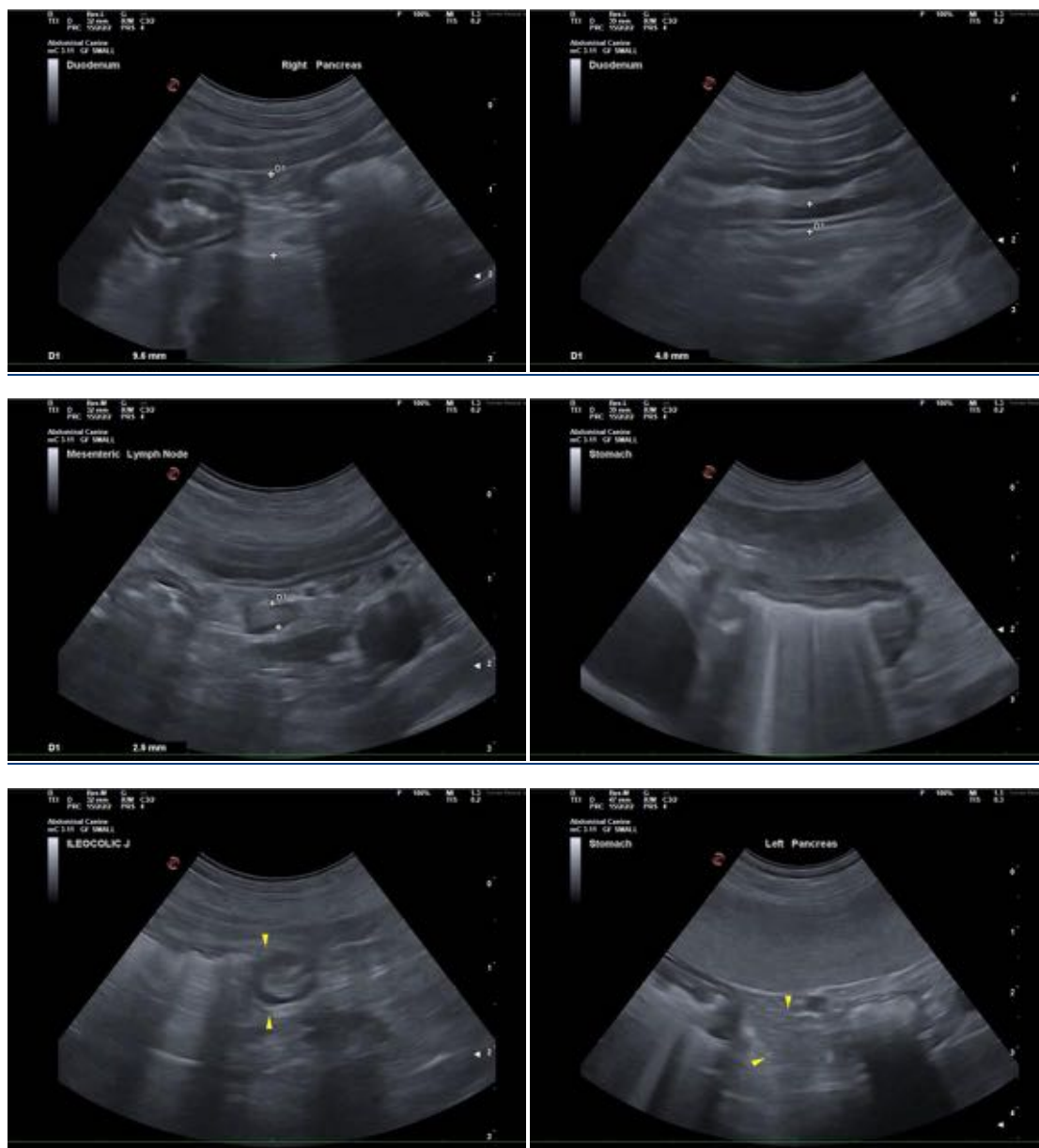
Dr. Biello

**INVOICE**

12974

**DATE**

2/8/22



The information and recommendations provided are based on the images presented by the referring veterinarian/sonographer. No evaluation can be communicated regarding pathology that was not visible in the image/video clips provided.

Thank you for this referral. If the clinical or image interpretation does not parallel your findings or if I can be of any further assistance please contact me.

Andrea Nicastro, DVM, Diplomate ACVIM (Small Animal Internal Medicine)

Andrea.nicastro@sonopath.com