SonoPath
Clinical Sonography & Telecytology

EDUCATIONAL TELECONSULTATION SERVICES™

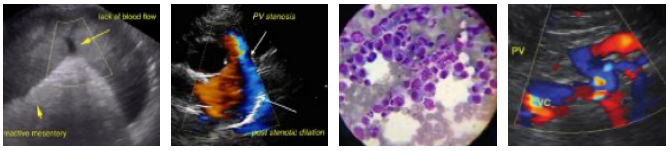

SonoPath.com™
1-800-838-4268 info@sonopath.com

PATIENT
Charlie Palmer

SPECIES
Canine

BREED
Beagle

SEX
Male, neutered

AGE
13 Yrs.

WEIGHT
14.4 kg.

INTERPRETED BY
Andrea Nicastro, DVM, Diplomate ACVIM (*Small Animal Internal Medicine*)

IMAGING PERFORMED BY
Dr. Patti Mayfield

HOSPITAL NAME
Highland VH

REFERRING VET
Dr. Rachel Poet

INVOICE
12979

DATE
2/8/22

PRESENTING CLINICAL SIGNS

History: Reason for Non-urgent Ultrasound: Abnormal urination , elevated liver enzymes, urine very dilute Primary Problem(s): Patient having urinary issues, tries to avoid accidents in the house but is going very frequently, has been going on for at least a couple months. Pertinent Medical History: Splenectomy performed ~ 3 years ago due to traumatic rupture. Histopathology not performed due to history of concussive trauma and subsequent hemorrhage. Current Medication: Galliprant 60 mg 1/2 tablet daily.
Abnormal PE/Chem/CBC/UA Results: Physical exam: Lenticular sclerosis and fibropapillomatous palpebral lesions OU. Mild dental tartar Multiple SQ lipomatous masses + sebaceous adenoma R scapular region Soft, supple abdomen. Mild ulcerative dermatitis on the prepuce. Blood work: 1/13/2022: CBC: Reticulocytes-- 172 K/ul (10-110) Platelets-- 603 K/uL (143-440) WBC -- 18,000/uL (4900-17,600) Remainder WNL CHEM: ALT-- 172 U/L (18-121) ALP-- 800 U/L (5-160) Remainder WNL UA: USG: 1.004, pH: 8, remainder unremarkable (no pyuria, hematuria, bacteriuria, crystalluria, proteinuria, etc) T4: wnl HW Ag: Neg

ULTRASONOGRAPHIC EXAMINATION OF THE ABDOMEN

Urinary System

The urinary bladder, trigone, and pelvic urethra are normal in thickness and the mucosal surface is smooth. The bladder lumen is moderately distended with anechoic urine. No masses, inflammatory changes or calculi are observed. Ureteral papillae and visualized portion of the proximal urethra, visible to a depth of 2 cm, are normal.

The prostate is normal in size (1.00 cm in width) and shape. Parenchyma is homogenous. The prostatic urethra appears normal without evidence of dilation or obstruction.

The left kidney is normal size (5.79 cm in length); normal shape and architecture with smooth peripheral margins. There is a normal 1:3 cortex to medulla ratio with minimal loss of corticomedullary distinction. Mild pyelectasia is present (0.32 cm in the transverse plane). There is no evidence of nephroliths, infarcts or hydroureter. Renal vasculature is normal.

The right kidney is normal size (4.65 cm in length); normal shape and architecture with smooth peripheral margins. There is a normal 1:3 cortex to medulla ratio with minimal loss of corticomedullary distinction. Trace pyelectasia is present (0.20 cm in the transverse plane). There is no evidence of nephroliths, infarcts or hydroureter. Renal vasculature is normal.

Adrenal Glands

The left adrenal gland is normal size (0.64 cm at cranial pole) (0.58 cm at caudal pole) (2.11 cm in length); normal shape; homogenous parenchyma. The glandular echogenicity and detail are unremarkable. Capsule, cortex, and medullary definition are normal. The phrenicoabdominal vein and surrounding vasculature are normal.

The right adrenal gland is mildly enlarged (1.84 cm at cranial pole) (0.70 cm at caudal pole) (2.66 cm in length) with a slightly irregular shape. The parenchyma is subtly heterogeneous with some loss of glandular detail. The phrenicoabdominal vein and surrounding vasculature are normal.

Spleen

Previously splenectomized due to traumatic rupture.

Liver

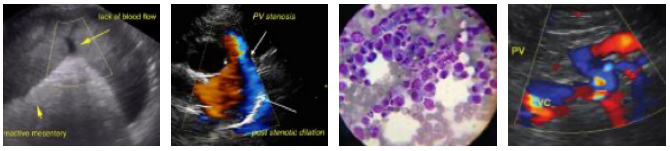

SonoPath.com
1-800-838-4268 info@sonopath.com

PATIENT
Charlie Palmer

SPECIES
Canine

BREED
Beagle

SEX
Male, neutered

AGE
13 Yrs.

WEIGHT
14.4 kg.

INTERPRETED BY
Andrea Nicastro, DVM, Diplomate ACVIM (*Small Animal Internal Medicine*)

IMAGING PERFORMED BY
Dr. Patti Mayfield

HOSPITAL NAME
Highland VH

REFERRING VET
Dr. Rachel Poet

INVOICE
12979

DATE
2/8/22

The liver is subjectively prominent in size with slightly swollen peripheral contours. The parenchyma is hypoechoic relative to the spleen and subtly mottled in appearance. A few small hyperechoic nodules are visualized. In addition, a 3.06 cm irregular hyperechoic to attenuating mass is observed on the right side. Finally, a 3.29 x 1.88 cm ill-defined hyperechoic to slightly heterogeneous nodule/area is observed in the left lateral lobe. Vascular and biliary tracts are of normal volume with no evidence of congestion. The gall bladder lumen is moderately distended. The wall is thin and smooth. A 1.06 cm polypoid like lesion is arising from the luminal surface. A small to moderate amount of echogenic, partially dependent debris/sludge is observed within the lumen. The cystic and common bile ducts are normal/not seen.

Gastrointestinal

The stomach and intestine are free of stasis and exhibit normal peristaltic activity. The gastric lumen is not distended. The gastric wall and pylorus are normal in thickness with a normal layering pattern. The pyloric outflow tract is patent. The small intestinal lumen is not dilated. The small intestinal wall thickness is normal with a normal layering pattern and appropriate mural detail. Discreet masses are not identified. The colonic wall is normal. No obstructive disease is noted.

Pancreas

The region of the pancreas is isoechoic relative to surrounding omental fat. No obvious parenchymal abnormalities are observed. There is no evidence of regional inflammation or effusion.

Free Abdomen

The peritoneal cavity is normal. There is no evidence of inflammation or effusion. The abdominal lymph nodes are normal/not visible.

ULTRASONOGRAPHIC FINDINGS

Primary Findings:

- The hyperechoic to attenuating right hepatic mass could be consistent with a focus of vacuolar hepatopathy, myelolipoma, regenerative nodule or less likely, a malignant process. The small hyperechoic nodules trend toward the benign (i.e., regenerative nodules). The ill-defined left hepatic lesion could be consistent with an area of regenerative nodular hyperplasia. Alternatively, emerging neoplasia is possible.
- Gallbladder debris/sludge, non-mucocele.
- Right adrenomegaly.

Secondary Findings:

- Minor, age-related renal changes with mild pyelectasia.

INTERPRETATION OF THE FINDINGS & FURTHER RECOMMENDATIONS

- A urine culture and sensitivity is recommended to evaluate for occult pyelonephritis.
- Given the clinical history, further testing for Cushing's disease (i.e., low-dose dexamethasone suppression test or ACTH stimulation test) should be considered. A baseline blood pressure

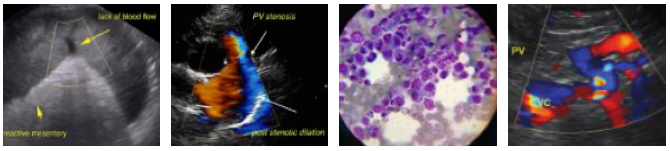

PATIENT

Charlie Palmer

SPECIES

Canine

BREED

Beagle

SEX

Male, neutered

AGE

13 Yrs.

WEIGHT

14.4 kg.

INTERPRETED BY

Andrea Nicastro, DVM, Diplomate ACVIM (*Small Animal Internal Medicine*)

IMAGING PERFORMED BY

Dr. Patti Mayfield

HOSPITAL NAME

Highland VH

REFERRING VET

Dr. Rachel Poet

INVOICE

12979

DATE

2/8/22

measurement should also be considered, particularly if the patient is subsequently diagnosed with Cushing's disease.

- A fine needle aspirate of the lesion in the left lateral lobe of the liver is recommended if clotting status is appropriate. If a more conservative approach is desired, consider a recheck ultrasound in 1-2 months to assess for progression. The gallbladder sludge can also be reassessed at this time to evaluate for potential development of a mucocele.
- Further PU/PD workup (if Cushing's negative) could include the following:
  1. DDAVP trial to assess for central diabetes insipidus
  2. Modified water deprivation test to evaluate for psychogenic polydipsia and nephrogenic diabetes insipidus
  3. Leptospirosis testing (i.e., blood and urine PCR, serology)

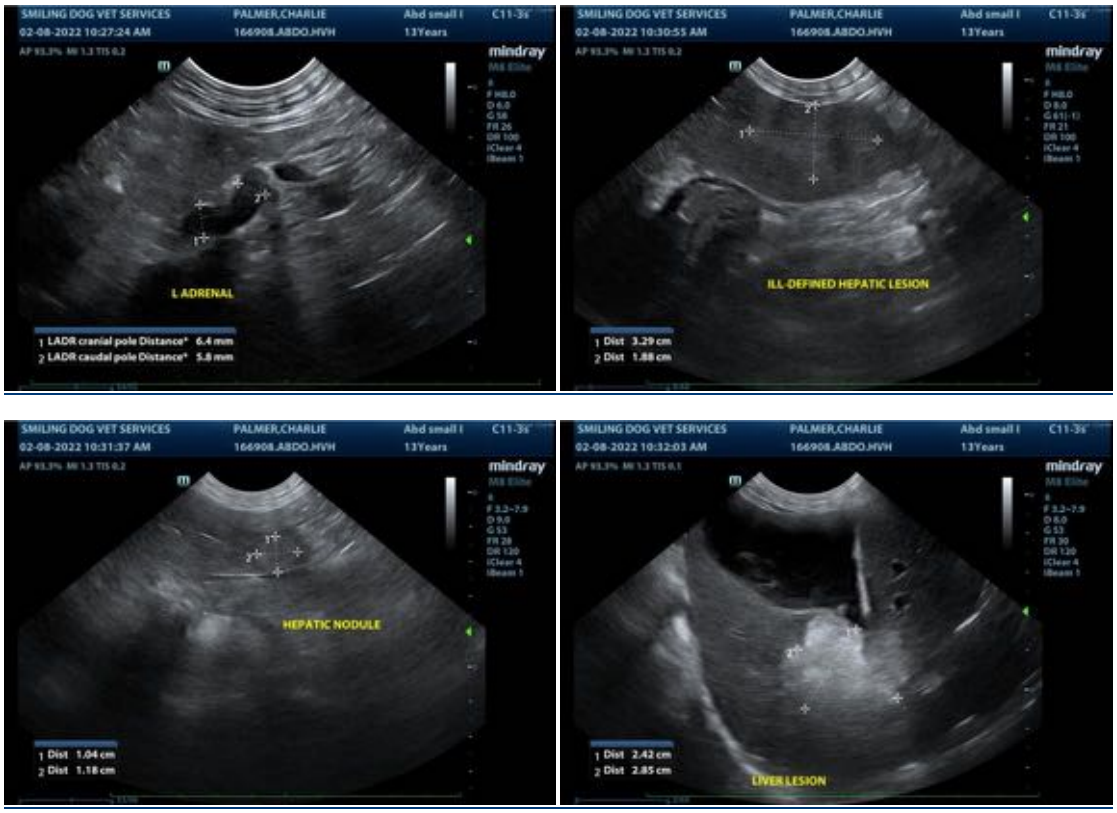

SonoPath

Clinical Sonography & Telecytology

EDUCATIONAL TELECONSULTATION SERVICES™

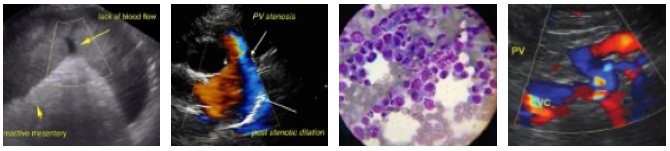

SonoPath.com™

1-800-838-4268 info@sonopath.com

PATIENT

Charlie Palmer

SPECIES

Canine

BREED

Beagle

SEX

Male, neutered

AGE

13 Yrs.

WEIGHT

14.4 kg.

INTERPRETED BY

Andrea Nicastro, DVM, Diplomate ACVIM (*Small Animal Internal Medicine*)

IMAGING PERFORMED BY

Dr. Patti Mayfield

HOSPITAL NAME

Highland VH

REFERRING VET

Dr. Rachel Poet

INVOICE

12979

DATE

2/8/22

The information and recommendations provided are based on the images presented by the referring

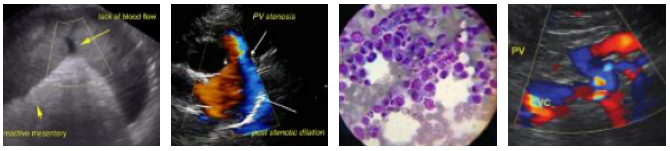

SonoPath.com
1-800-838-4268 info@sonopath.com

PATIENT

Charlie Palmer

SPECIES

Canine

BREED

Beagle

SEX

Male, neutered

AGE

13 Yrs.

WEIGHT

14.4 kg.

INTERPRETED BY

Andrea Nicastro, DVM, Diplomate ACVIM (*Small Animal Internal Medicine*)

IMAGING PERFORMED BY

Dr. Patti Mayfield

HOSPITAL NAME

Highland VH

REFERRING VET

Dr. Rachel Poet

INVOICE

12979

DATE

2/8/22

veterinarian/sonographer. No evaluation can be communicated regarding pathology that was not visible in the image/video clips provided.

Thank you for this referral. If the clinical or image interpretation does not parallel your findings or if I can be of any further assistance please contact me.

Andrea Nicastro, DVM, Diplomate ACVIM (*Small Animal Internal Medicine*)

Andrea.nicastro@sonopath.com