

PATIENT PRESENTING CLINICAL SIGNS

PATIENT Daisy Klinck
SPECIES Canine
BREED Pit mix
SEX Female, spayed
AGE 10 Years
WEIGHT 73 Pounds

History: Currently has 2-3 mast cell tumors on the skin that need to be removed. As well as a fractured canine that needs extraction. Has a previous history of mast cell tumor removal. Currently, o feels p is PU/PD Physical exam findings: BARH, masses, fractured tooth, overweight, pot belly Abnormal CBC values: mild hemococnetration - HCT 58% Abnormal Chemistry Values: ALP 542 (5-160), Cholesterol 431 (31-345), CK 234 (0-200) Abnormal UA Values: USG 1025, trace protein, occasional granular cast Radiograph Findings(email radiographs if available): Reason for Ultrasound: Evaluate for cause of elevated ALP. Low Dose Dex Suppression test was not supportive of Cushing's disease. Also want to make sure anesthesia for mass removal and tooth extraction is safe

ULTRASONOGRAPHIC EXAMINATION OF THE ABDOMEN

Urinary System

The urinary bladder wall is normal in thickness and the mucosal surface is smooth. The bladder lumen is moderately distended with anechoic urine. No masses, inflammatory changes or calculi are observed. Ureteral papillae and visualized portion of the proximal urethra, visible to a depth of 2 cm, are normal.

The left kidney is normal size (6.78 cm in length); normal shape and architecture with smooth peripheral margins. There is a normal 1:3 cortex to medulla ratio with mild loss of corticomedullary distinction. There is no evidence of pyelectasia, nephroliths, infarcts or hydroureter.

The right kidney is normal size (7.19 cm in length); normal shape and architecture with smooth peripheral margins. There is a normal 1:3 cortex to medulla ratio with minimal to mild loss of corticomedullary distinction. There is no evidence of pyelectasia, nephroliths, infarcts or hydroureter.

Adrenal Glands

The left adrenal gland is normal size (0.84 cm at cranial pole) (0.79 cm at caudal pole); normal shape; homogenous parenchyma. The glandular echogenicity and detail are unremarkable. Capsule, cortex, and medullary definition are normal. The phrenicoabdominal vein and surrounding vasculature are normal.

The right adrenal gland is normal size (0.83 cm at cranial pole) (0.68 cm at caudal pole) with a slightly irregular shape. The glandular echogenicity and detail are unremarkable. Capsule, cortex, and medullary definition are normal. The phrenicoabdominal vein and surrounding vasculature are normal.

Spleen

The spleen is normal in size (1.89 cm in width at the level of the hilus) with a normal capsular contour. There is appropriate echogenicity and echotexture. A few small ill-defined hypoechoic nodules/areas are observed, the largest measuring 0.52 cm in length. Splenic vasculature is normal.

Liver

The liver is subjectively normal in size with normal contours and structure. There is appropriate echogenicity and echotexture. No overt structural evidence of inflammatory, infiltrative or regenerative pathology is evident. Vascular and biliary tracts are of normal volume with no evidence of congestion. No pathological hepatic lymphadenopathy observed. The gallbladder is of normal contours and contains some dependent echogenic debris. The wall is normal in thickness. No choleliths are

INTERPRETED BY

Andrea Nicastro, DVM,
Diplomate ACVIM
(Small Animal Internal
Medicine)

IMAGING PERFORMED BY

Loetitia Saint-Jacques, RVT

HOSPITAL NAME

Alpine AH

REFERRING VET

Dr. Lindsay Sjolín

INVOICE

14551

DATE

2/6/23



PATIENT observed. The cystic and common bile ducts are normal.

Daisy Klinck ***Gastrointestinal***

SPECIES The gastric lumen is not distended. The gastric wall is normal in thickness with a normal layering pattern. The small intestinal lumen is not dilated. The small intestinal wall thickness is normal with a normal layering pattern and appropriate mural detail. Discreet masses are not identified. The colonic wall is normal. There is no evidence of an obstructive pattern.

Canine

BREED ***Pancreas***

Pit mix The region of the pancreas is isoechoic relative to surrounding omental fat. No obvious parenchymal abnormalities are observed. There is no evidence of regional inflammation or effusion.

SEX ***Free Abdomen***

Female, spayed The peritoneal cavity is normal. There is no evidence of inflammation or effusion. The left medial iliac lymph node is visible (1.47 cm in length). The node is normal in shape and echogenicity. A few prominent mesenteric lymph nodes are also seen, the largest measuring 2.28 cm in length.

AGE

10 Years

ULTRASONOGRAPHIC FINDINGS

WEIGHT

73 Pounds

Primary Findings:

- Minor bilateral age-related renal changes.

Secondary Findings:

- The splenic parenchymal changes are most consistent with a benign process such as lymphoid hyperplasia, extramedullary hematopoiesis, splenitis or antigenic stimulation with a lower possibility of infiltrative neoplasia (i.e., lymphoma, mast cell neoplasia).
- The prominent abdominal lymph nodes are most consistent with reactive lymphadenitis or lymphoid hyperplasia. Neoplastic infiltration is considered less likely.

INTERPRETED BY

Andrea Nicastro, DVM,
Diplomate ACVIM
(*Small Animal Internal
Medicine*)

IMAGING PERFORMED BY

Loetitia Saint-Jacques, RVT

HOSPITAL NAME

Alpine AH

*The cause for the elevated ALT is not definitively identified in this study. However, a benign process (i.e., early vacuolar hepatopathy or regenerative nodular hyperplasia or age-related remodeling) is considered likely with a lower possibility of inflammatory disease or infiltrative neoplasia.

REFERRING VET

Dr. Lindsay Sjolín

INTERPRETATION OF THE FINDINGS & FURTHER RECOMMENDATIONS

INVOICE

14551

DATE

2/6/23

- Given the possible PU/PD as well as the proteinuria, a urine culture and sensitivity +/- a UPC (if proteinuria persists in the face of a negative urine culture) should be considered.
- Regarding the splenic changes, consider a fine needle aspirate (to further assess for mast cell disease), if clotting status is appropriate. A 25-gauge needle should be used. Subcutaneous diphenhydramine is recommended 15 minutes prior to aspiration to help reduce the risk of mast cell degranulation.
- Thoracic radiographs should also be considered to assess for metastatic disease, if not already performed.



PATIENT

Daisy Klinck

SPECIES

Canine

BREED

Pit mix

SEX

Female, spayed

AGE

10 Years

WEIGHT

73 Pounds

INTERPRETED BY

Andrea Nicastro, DVM,
Diplomate ACVIM
(Small Animal Internal
Medicine)

IMAGING PERFORMED BY

Loetitia Saint-Jacques, RVT

HOSPITAL NAME

Alpine AH

REFERRING VET

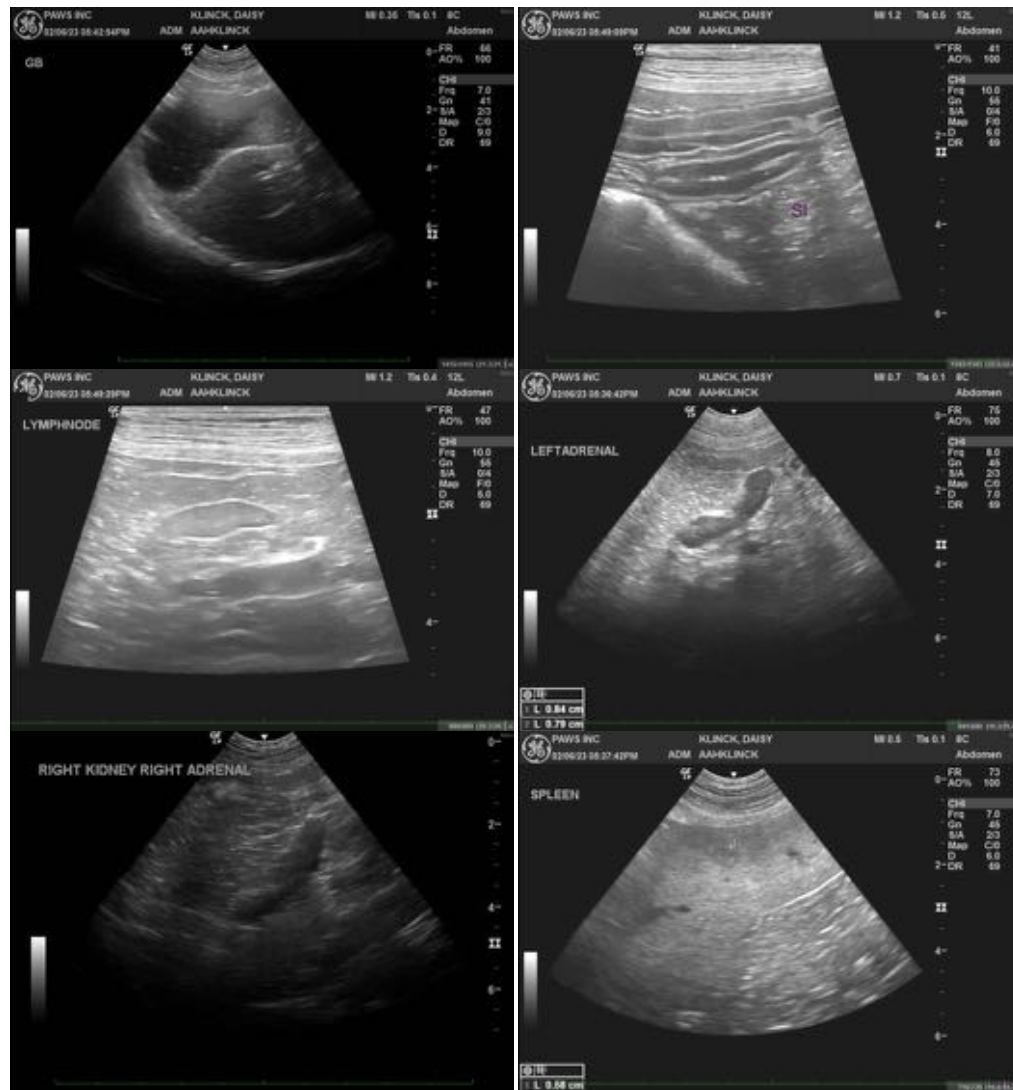
Dr. Lindsay Sjolín

INVOICE

14551

DATE

2/6/23



The information and recommendations provided are based on the images presented by the referring veterinarian/sonographer. No evaluation can be communicated regarding pathology that was not visible in the image/video clips provided.

Thank you for this referral. If the clinical or image interpretation does not parallel your findings or if I can be of any further assistance, please contact me.

Andrea Nicastro, MPH, DVM, Diplomate DACVIM (Small Animal Internal Medicine)
info@SonoPath.com